

VENTANA PD-L1 (SP263) Assay Interpretation Guide for Non-Small Cell Lung Cancer

1% Tumor Cell (TC) Scoring Algorithm

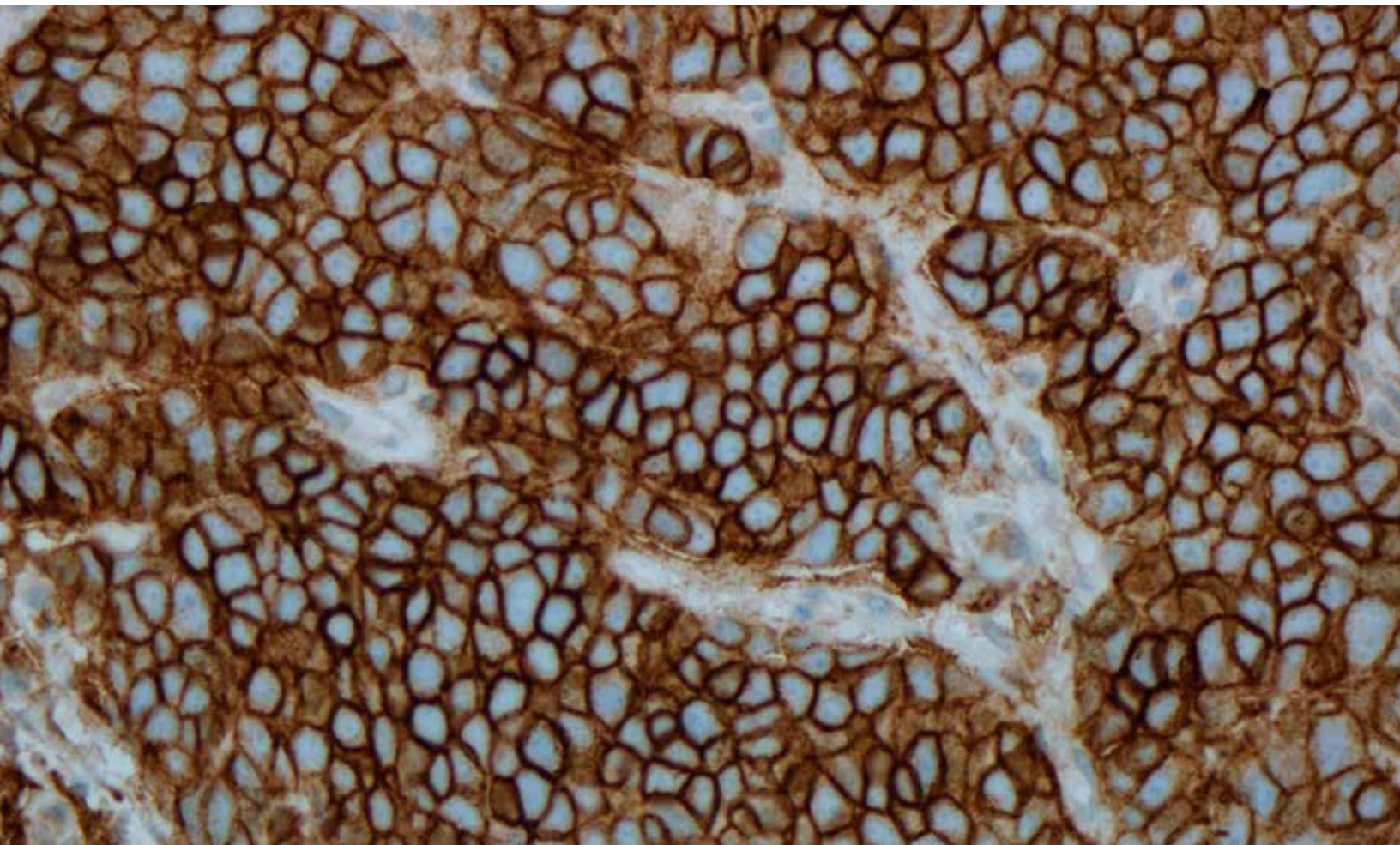


Table of Contents

Introduction	5
Intended Use	6
Intended Use of Product	6
Purpose of Interpretation Guide	6
Evaluation	7
Evaluating Tumor Cell Staining Patterns and Intensities	7
Morphology and Background Acceptability Criteria	14
Positive Tissue Control	15
Scoring Criteria	16
PD-L1 Expression Atlas in NSCLC	18
Photo Gallery	18
Challenging Features	38
Impact of Pre-Analytical Conditions on VENTANA PD-L1 (SP263) Assay Staining	54
References	56

Introduction

Lung cancer has been the most common cancer in the world for several decades and remains the leading cause of cancer deaths worldwide. It is estimated to account for 12.9% of all new cancer cases and is responsible for nearly 1.59 million deaths annually worldwide, or approximately one in five cancer-related deaths.¹ Although improvements have been made in diagnosis and therapy options, prognosis remains poor with low long-term survival rates for all stages. Over the past three decades, lung cancer has shown among the least improvement in survival rates when compared with other cancers.²

Non-small cell lung cancer (NSCLC), one of the two major types of lung cancer, accounts for approximately 85% of all lung cancer cases.³ In more than half of patients newly diagnosed with NSCLC, the disease has already metastasized, greatly decreasing the likelihood of survival. The 5-year relative survival rate for NSCLC diagnosed as distant disease is 4.7%.³ The majority of patients with NSCLC present with inoperable, locally advanced disease (Stage IIIB) or metastatic disease (Stage IV), neither of which currently has any curative treatment options; on average, these patients typically die within a year of diagnosis. Improvement in the clinical outcome of lung cancer is likely to be achieved through better understanding of the molecular events that underlie its pathogenesis, identifying new biomarker targets, and developing new treatment options.

PD-L1 is a transmembrane protein that downregulates immune responses through binding to its two inhibitory receptors programmed death-1 (PD-1) and B7.1.⁴ PD-1 is an inhibitory receptor expressed on T cells following T-cell activation, which is sustained in states of chronic stimulation such as in chronic infection or cancer.⁵ Binding of PD-L1 with PD-1 inhibits T cell proliferation, cytokine production, and cytolytic activity, leading to the functional inactivation or exhaustion of T cells. B7.1 is a molecule expressed on antigen presenting cells and activated T cells. PD-L1 binding to B7.1 on T cells and antigen presenting cells can mediate downregulation of immune responses, including inhibition of T-cell activation and cytokine production.⁶ PD-L1 expression has been observed in immune cells and tumor cells.^{7,8} Aberrant expression of PD-L1 on tumor cells has been reported to impede anti-tumor immunity, resulting in immune evasion.^{5,8} Therefore, interruption of the PD-L1/PD-1 pathway represents an attractive strategy to reinvigorate tumor-specific T cell immunity suppressed by the expression of PD-L1 in the tumor microenvironment. PD-L1 is expressed in a broad range of cancers including lung, melanoma, urothelial, ovarian, and colorectal cancer. Prevalence of PD-L1 expression has been reported from 12% to 100% depending on the tumor type, anti PD-L1 clone and cutoff for positivity.⁹

VENTANA PD-L1 (SP263) Assay is an immunohistochemical (IHC) assay utilizing an anti-PD-L1 rabbit monoclonal primary antibody (VENTANA PD-L1 (SP263)) to recognize the programmed death ligand 1 (PD-L1) protein.

Intended Use

Intended Use of Product

Refer to the corresponding VENTANA PD-L1 (SP263) Assay method sheet for the detailed intended use of this product.

Purpose of Interpretation Guide

The VENTANA PD-L1 (SP263) Assay interpretation guide is designed to assist pathologists in interpreting and scoring NSCLC tissues stained with VENTANA PD-L1 (SP263) Assay.

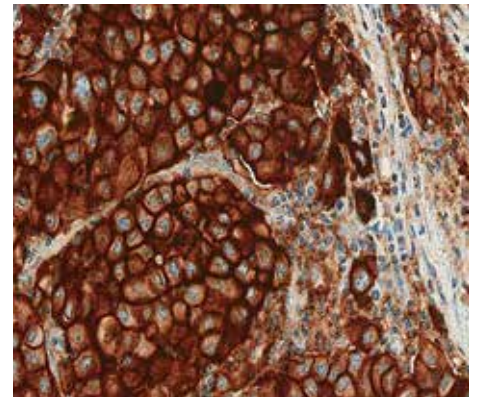
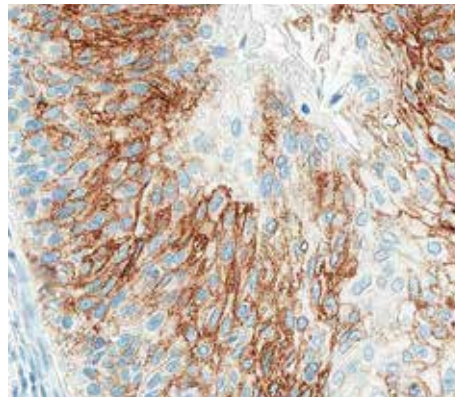
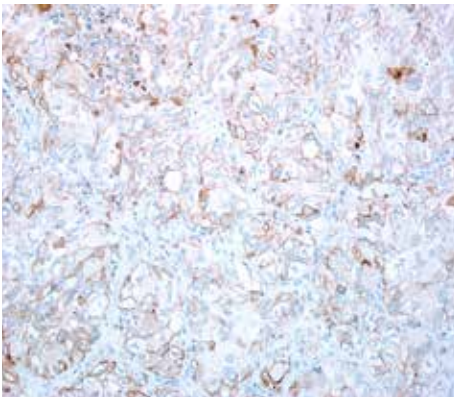
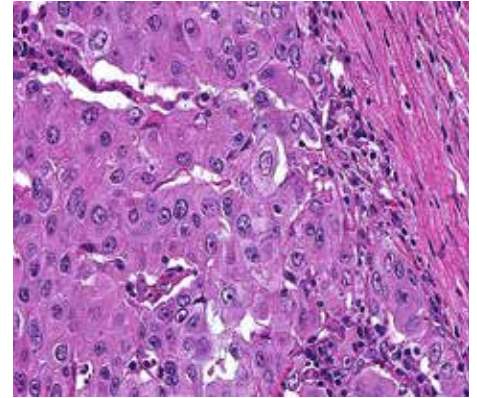
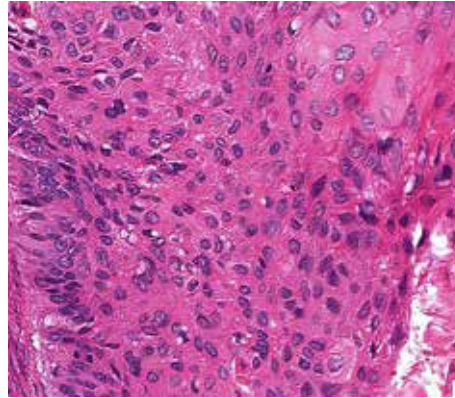
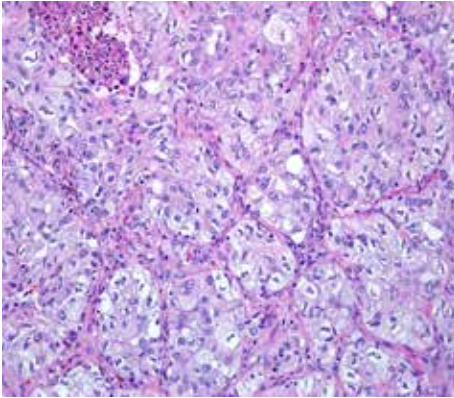
- The photomicrographs included as part of this interpretation guide illustrate the staining patterns, as well as the range of PD-L1 expression, which may be present in NSCLC tissues stained with VENTANA PD-L1 (SP263) Assay.
- The staining criteria in this interpretation guide outlines the scoring of NSCLC tissue stained with VENTANA PD-L1 (SP263) Assay using a $\geq 1\%$ tumor cell (TC) cutoff.
- The use of placenta as a tissue control in the context of PD-L1 evaluation, and the associated staining characteristics and performance are addressed.
- Challenging cases, staining artifacts, and the impact of pre-analytic conditions on the assay are also addressed.

Evaluation

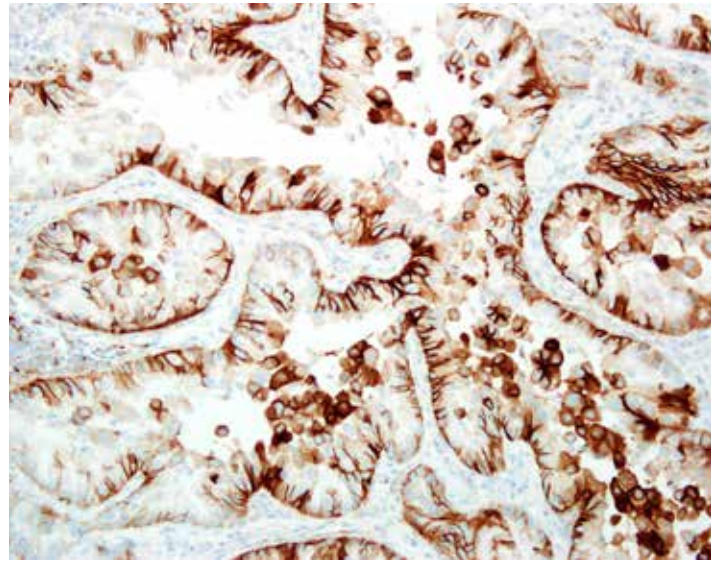
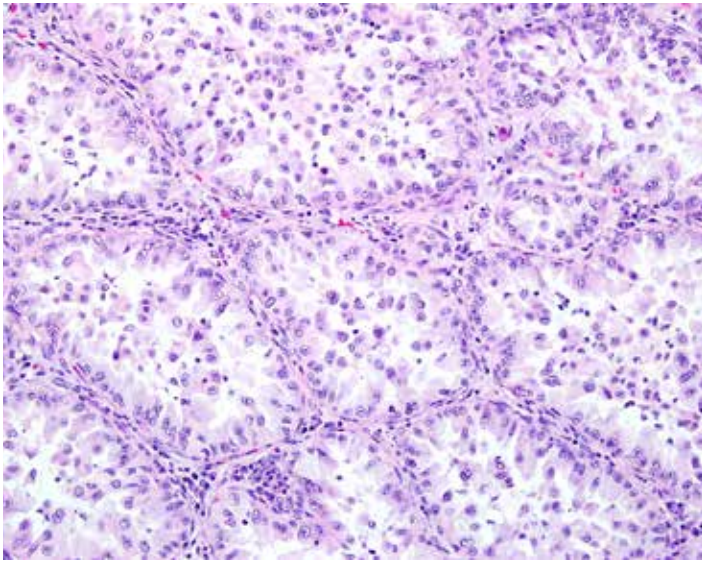
Evaluating Tumor Cell Staining Patterns and Intensities

NSCLC neoplastic cells labeled with the VENTANA PD-L1 (SP263) Assay are evaluated for percent positivity of the tumor cells with membrane staining at any intensity of the diaminobenzidine (DAB) signal. The immunohistochemical staining in NSCLC is membranous and/or cytoplasmic, and may be expressed homogeneously or heterogeneously throughout the neoplasm. Membrane staining can have a discontinuous, circumferential or basolateral pattern.

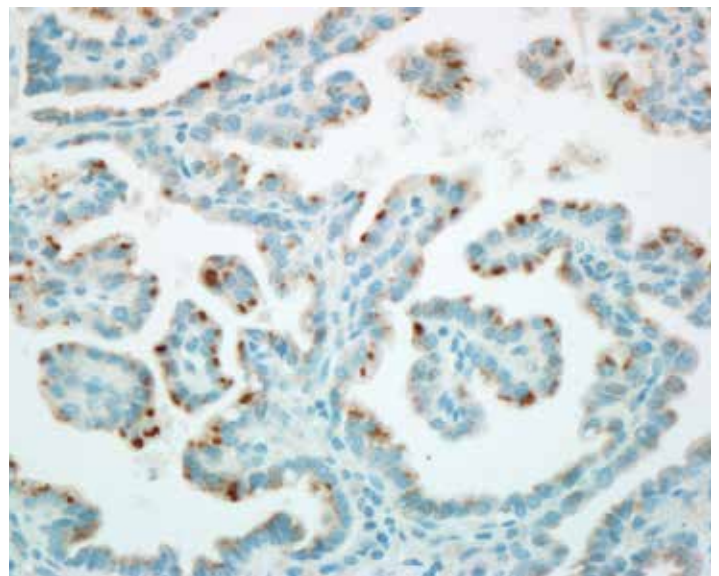
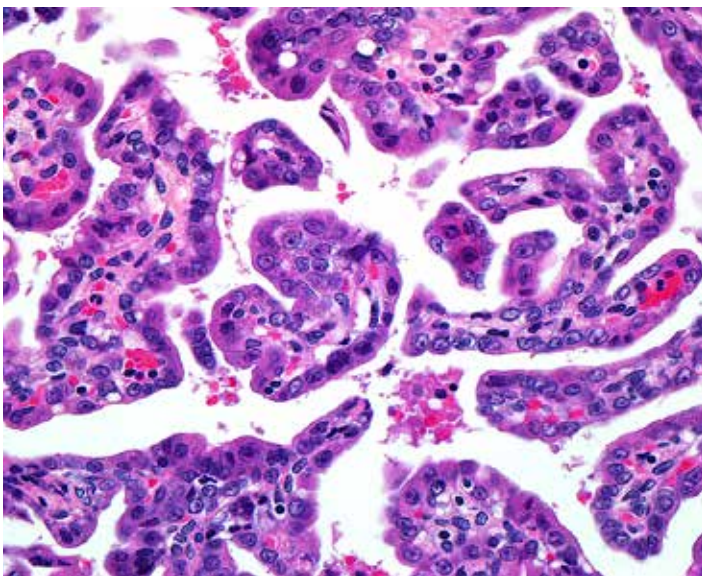
Cytoplasmic staining is generally diffuse with some cases displaying a finely granular quality. Rare cases have shown a peri-nuclear dot-like body staining with variable intensity. The total percentage of tumor membrane signal intensities is visually estimated and used to generate the PD-L1 expression level. Tumor cell cytoplasmic staining is disregarded for determining PD-L1 expression. An isotype-matched negative control antibody is used to evaluate the presence of background in test samples and establish a staining intensity baseline.



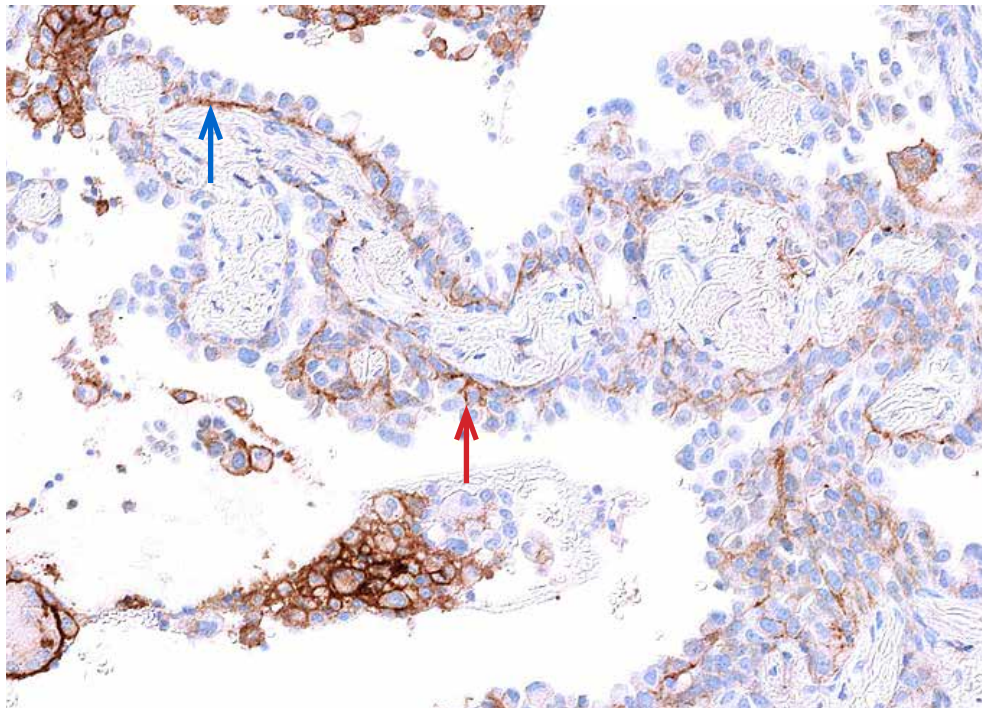
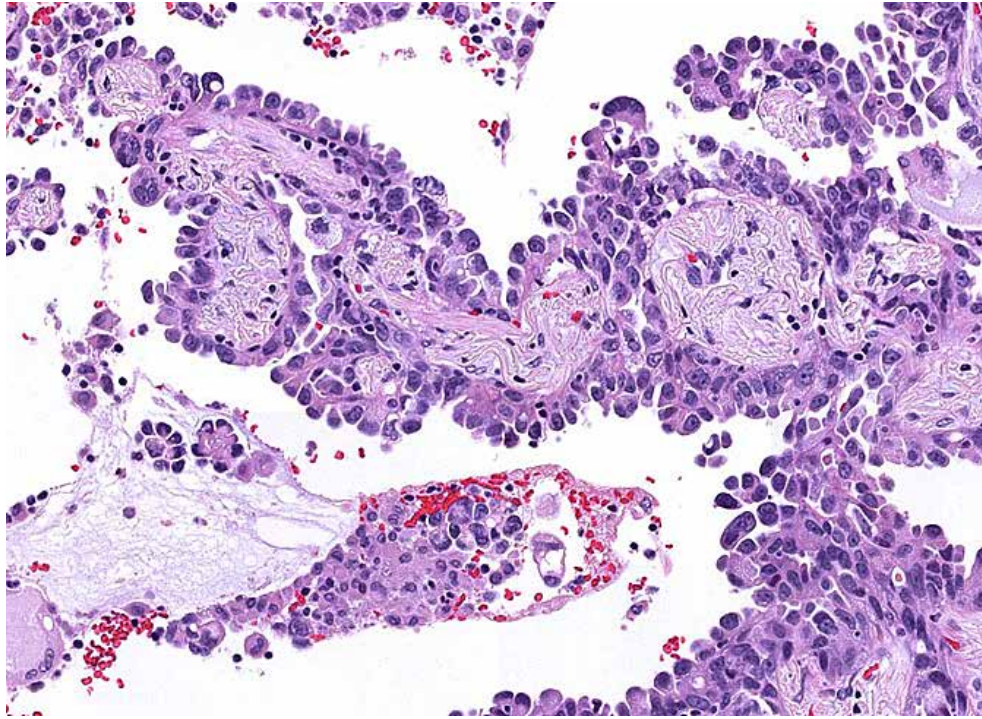
NSCLC, H&E and VENTANA PD-L1 (SP263) Assay: Various cases demonstrating the range of membrane and cytoplasmic staining in tumor cells (20x)



NSCLC, H&E and VENTANA PD-L1 (SP263) Assay: Tumor cells with basolateral pattern of membrane staining. (20x)



NSCLC, H&E and VENTANA PD-L1 (SP263) Assay: Unusual case with peri-nuclear dot-like staining within tumor cells. (40x)

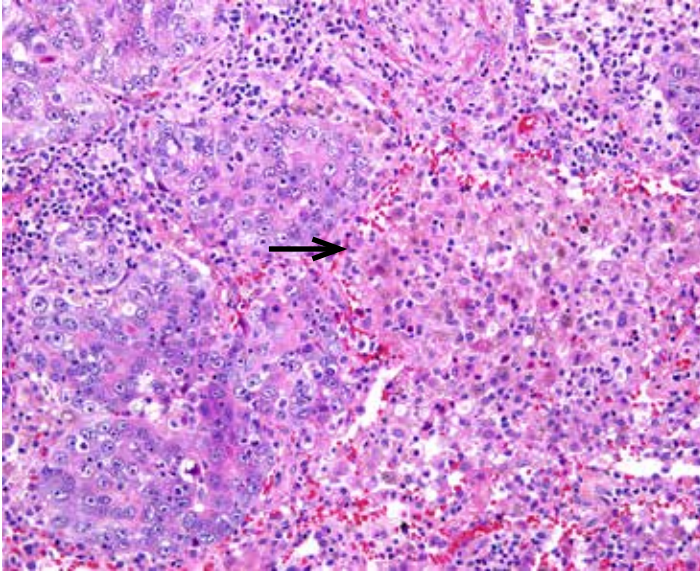


NSCLC, H&E and VENTANA PD-L1 (SP263) Assay: In cases demonstrating a basolateral pattern of tumor membrane staining only cells with definitive tumor cell expression should be included in the percent estimation (red arrow highlights tumor cells with basal and lateral tumor cell membrane staining). Areas where the staining could be attributed to immune cells, stromal elements or basement membrane, and not definitive tumor staining, should be disregarded (blue arrow highlights staining along base of tumor cells with no lateral staining). (20x)

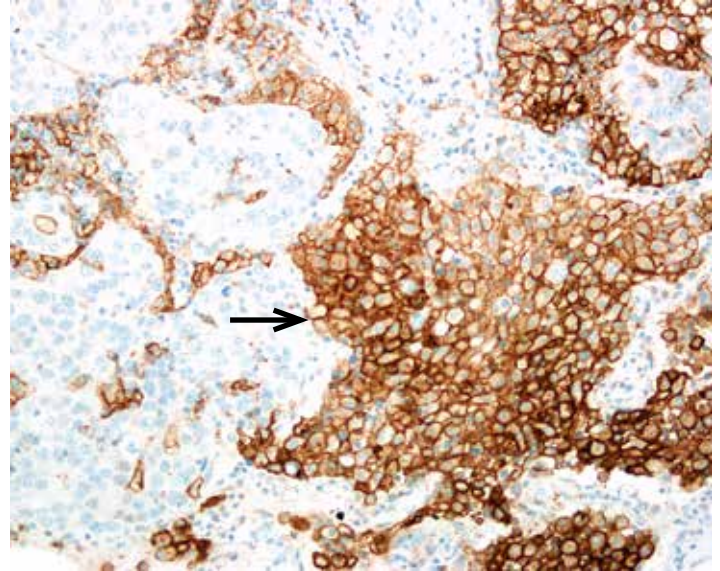
Immune Cell Staining Patterns

Immune cells exhibit a range of staining intensity: negative, weak diffuse cytoplasmic and/or weak to strong membranous signal. A punctate pattern of staining may be seen in association with lymphocytes. PD-L1 expression has been observed in lymphocytes, macrophages, histiocytes, plasma cells, and neutrophils.

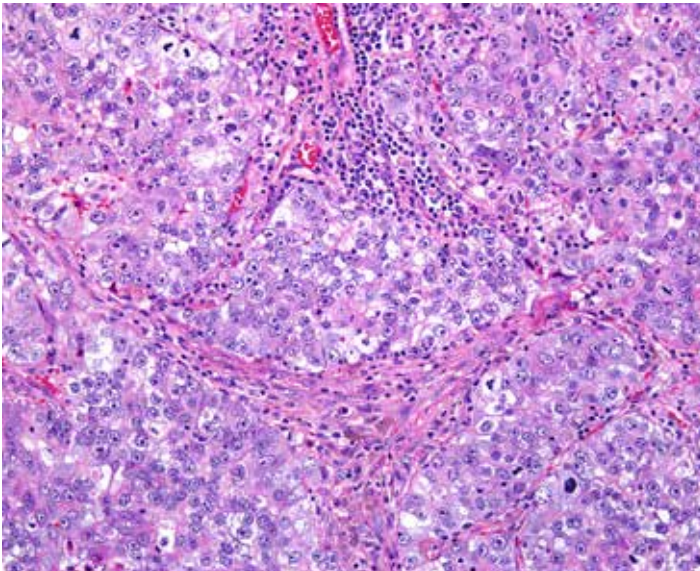
Representative images of immune cells stained with the VENTANA PD-L1 (SP263) Assay are provided below as a reference to assist the pathologist in differentiating between tumor cell and immune cell staining. NOTE: Immune cells are not included in the scoring of PD-L1 status.



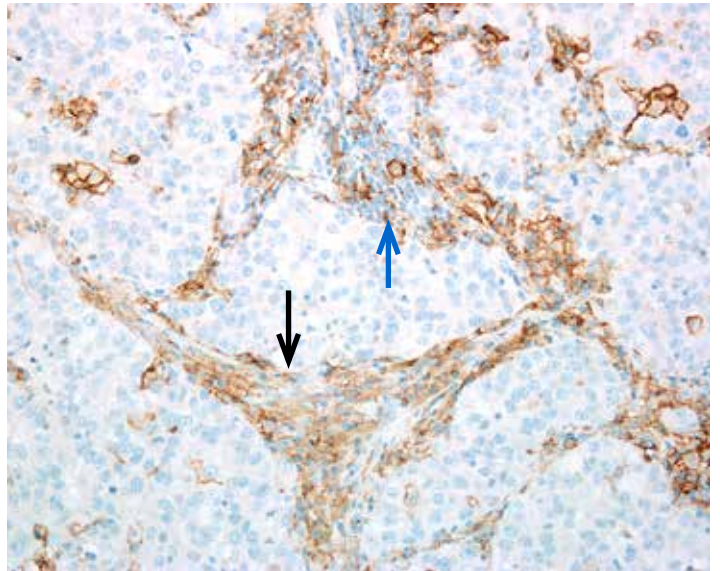
NSCLC, H&E: Tumor cells with alveolar macrophages (arrow). (20x)



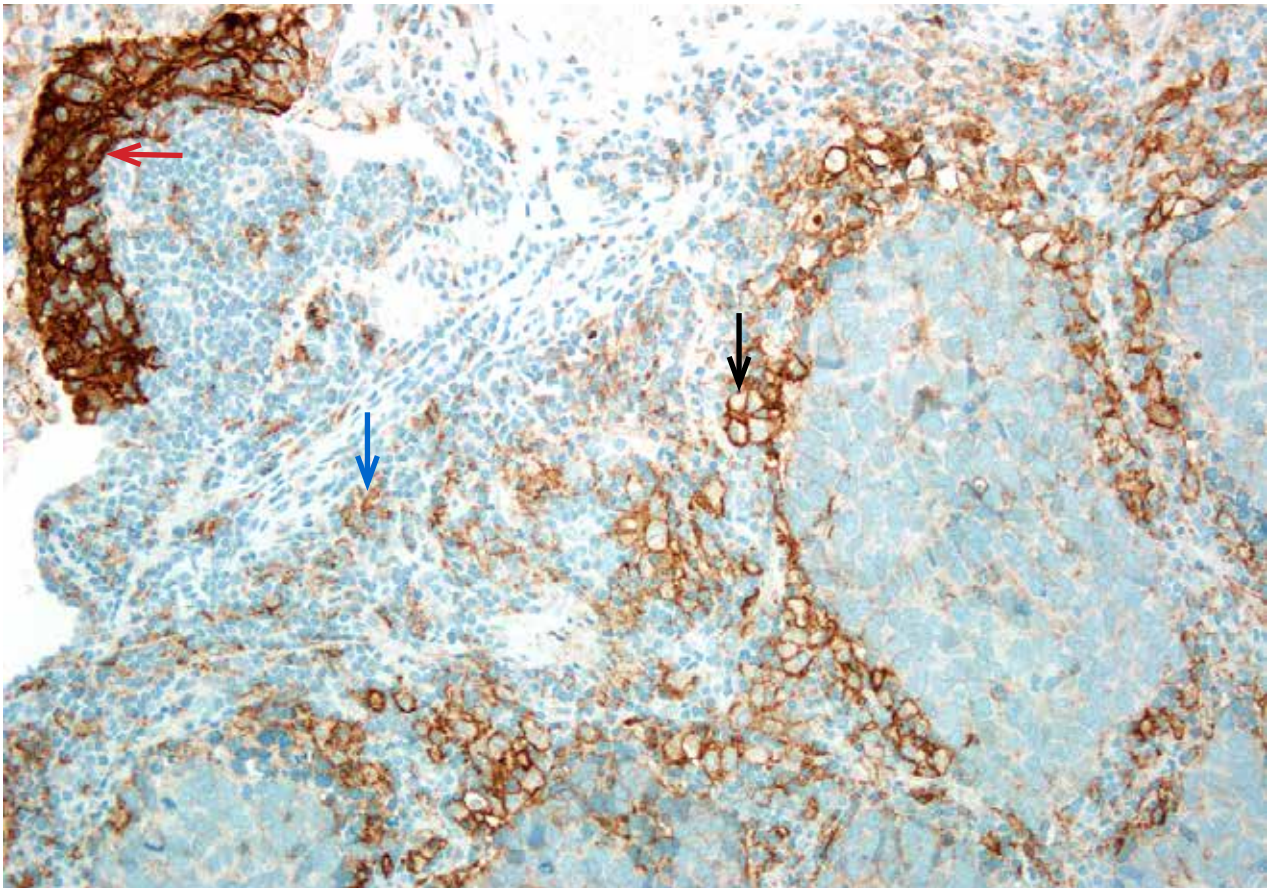

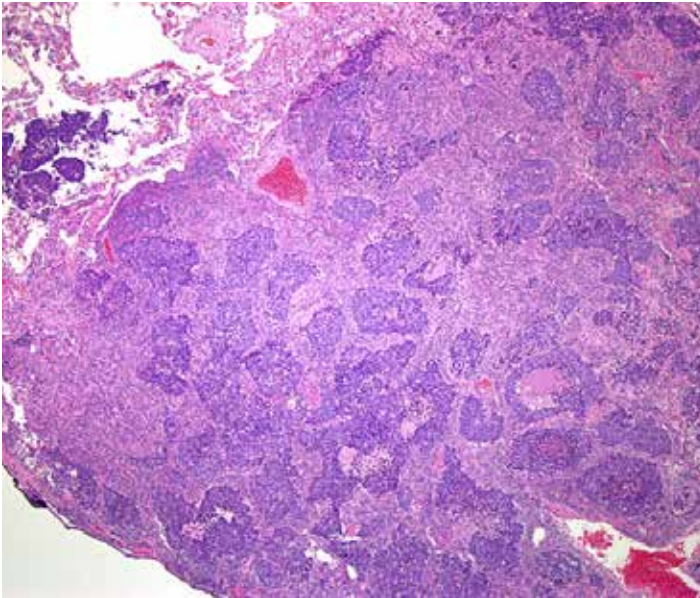
NSCLC, VENTANA PD-L1 (SP263) Assay: Positive alveolar macrophage staining (arrow) with adjacent PD-L1 negative tumor, zero percent staining. (20x)



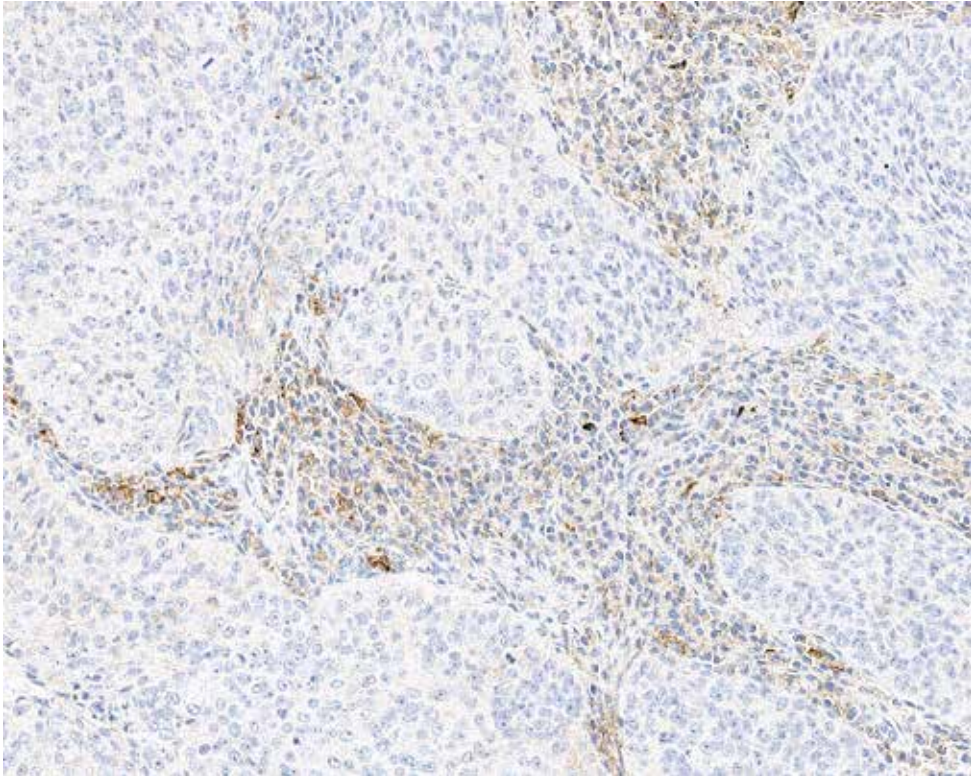
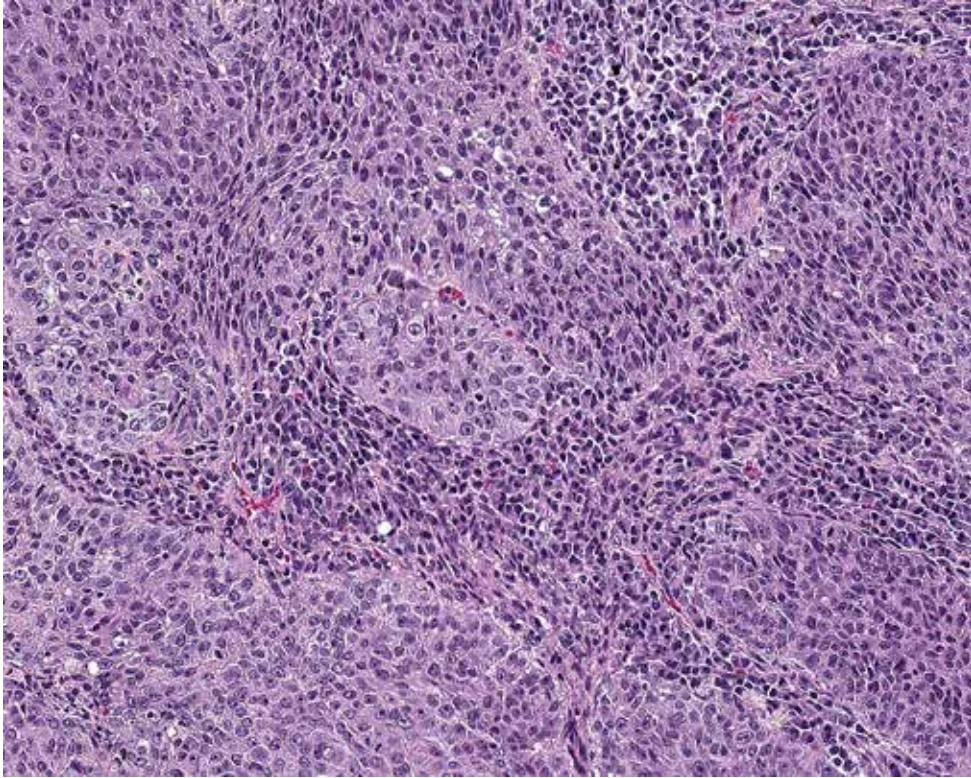
NSCLC, H&E: Tumor cells with lymphocytic and plasma cells immune cells. (20x)



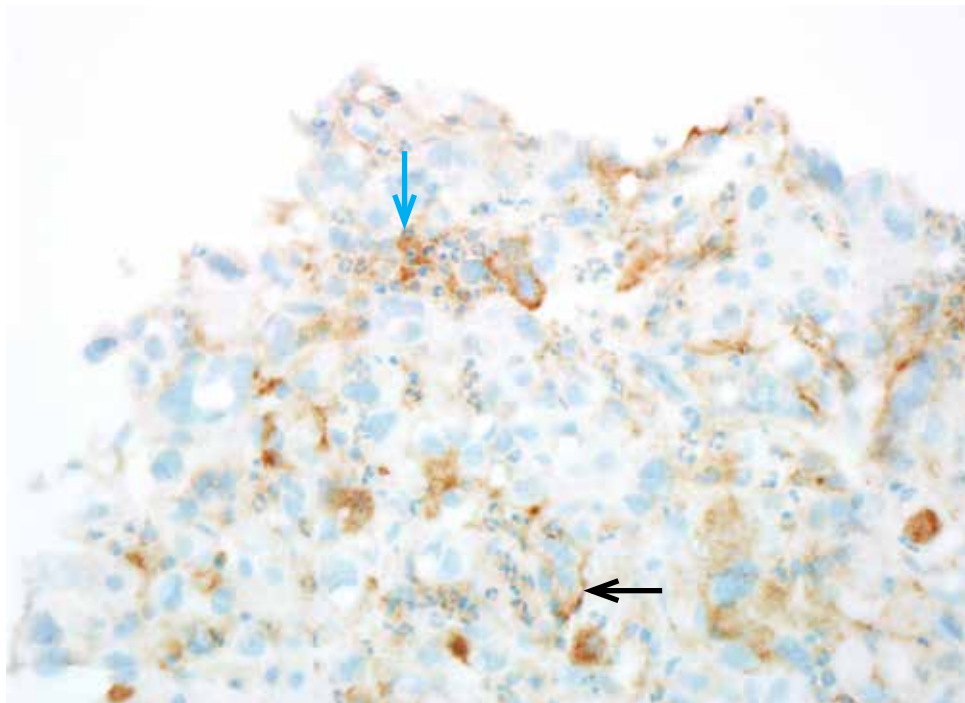
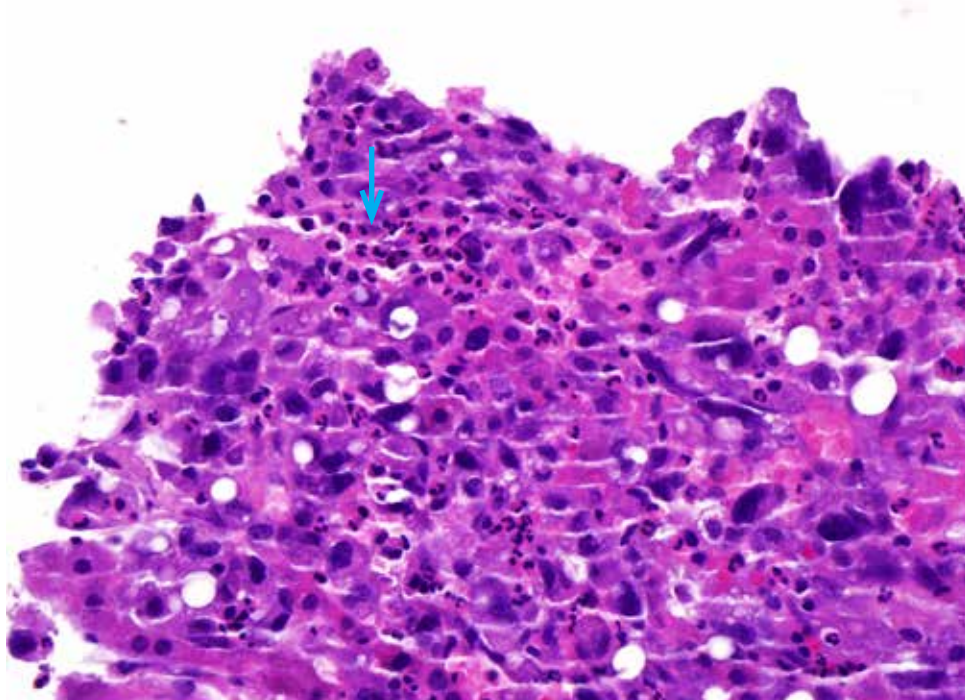
NSCLC, VENTANA PD-L1 (SP263) Assay: Punctate (blue arrow) and diffuse (black arrow) immune cell staining with adjacent PD-L1 negative tumor, zero percent staining. (20x)



NSCLC, H&E and VENTANA PD-L1 (SP263) Assay: At 4x (top panels), the staining pattern appears to contain significant tumor membrane staining. Examination at higher power (20x, bottom) reveals the tumor is mostly negative for PD-L1, with membranous (black arrow) and punctate (blue arrow) immune cell staining. Dendritic cell staining is also seen (red arrow).



NSCLC, H&E and VENTANA PD-L1 (SP263) Assay: Plasma cells with weak diffuse to moderate cytoplasmic staining. Surrounding tumor cells do not demonstrate staining. (20x)



NSCLC, H&E and VENTANA PD-L1 (SP263) Assay: Neutrophils from the H&E show PD-L1 expression (blue arrow). Case also has tumor cell membrane staining (black arrow). (40x)

Tissue Requirements

The VENTANA PD-L1 (SP263) Assay requires one serial tissue section for hematoxylin and eosin (H&E) staining, a second serial tissue section for negative control antibody staining, and a third serial tissue section for staining with the VENTANA PD-L1 (SP263) Assay. In addition, normal human term placenta tissue can be used as a control for the VENTANA PD-L1 (SP263) Assay. Placental tissue shows moderate to strong uniform staining of the membrane and weak to strong uniform staining of the cytoplasm of trophoblast-lineage cells. Placental stromal tissue and vasculature can be used for assessment of any background staining.

If H&E evaluation indicates that the patient specimen is inadequate then a new specimen should be obtained. Repeat staining of a specimen should be carried out on unstained slides if (1) the tissue run control slide does not exhibit acceptable staining; (2) the negative control case slide does not exhibit acceptable staining; or (3) the VENTANA PD-L1 (SP263) Assay stained case slide (the PD-L1 slide) is not evaluable. If the last of these slides is not interpretable due to artifacts, edge effects, necrosis, lack of tissue, or any other reason, then the slide cannot be used for clinical evaluation. If controls are acceptable and the VENTANA PD-L1 (SP263) Assay stained slide is evaluable, the slide can be evaluated by a trained pathologist as described in the Scoring Criteria.

Morphology and Background Acceptability Criteria

Tissue morphology and background acceptability are assessed for each patient case using the criteria described in Tables 1 and 2.

Table 1: Morphology Acceptability Criteria

Interpretation	Microscope Observation
Acceptable	Cellular elements of interest are visualized allowing interpretation of the stain.
Unacceptable	Cellular elements of interest are not visualized compromising interpretation of the stain.

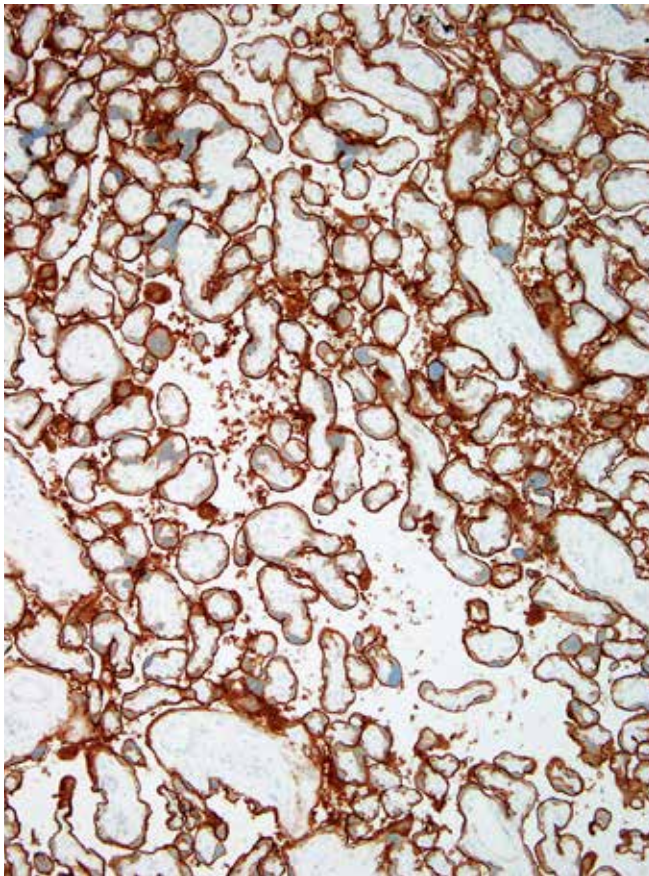
Table 2: Background Acceptability Criteria

Interpretation	Staining Description
Acceptable	Non-specific staining that is not obtrusive to interpretation of specific staining.
Unacceptable	Non-specific staining that is obtrusive to interpretation of specific staining.

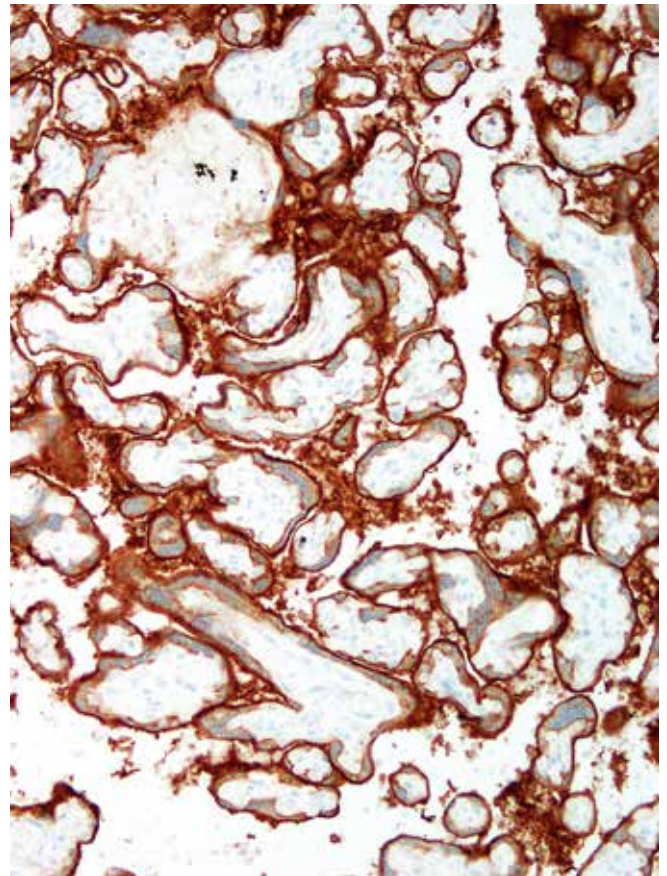
Positive Tissue Control

A known positive control tissue fixed and processed in the same manner as the patient specimens should be run for each set of test conditions and with every VENTANA PD-L1 (SP263) Assay staining procedure performed. The control tissue (an index case) should be a fresh autopsy, biopsy, surgical specimen prepared and fixed as soon as possible in a manner identical to patient specimens. This tissue may be used to monitor all steps of specimen processing and staining. A tissue section fixed or processed differently from the test specimen can be used as a control for reagents and staining but not for fixation or tissue preparation. A positive NSCLC case with moderate staining is more suitable for quality control than one with strong staining; it can be used to detect minor levels of reagent degradation or

out-of-specification issues that might be instrument-related. Positive membrane staining of neoplastic cells in the control tissue confirms that the VENTANA PD-L1 (SP263) antibody was applied and the instrument functioned properly. The positive tissue control should be used only to monitor performance; it should not be used to aid the clinical diagnosis of patient samples. Additionally, the VENTANA PD-L1 (SP263) Assay can utilize as a positive control normal human term placental tissue, which shows moderate to strong uniform staining of the membrane and weak to strong, uniform staining of the cytoplasm of trophoblast-lineage cells. Placental stromal tissue and vasculature can be used for assessment of any background staining.



Placenta, VENTANA PD-L1 (SP263) Assay: Strong uniform membrane staining and moderate cytoplasmic staining of trophoblast-lineage cells (10x)



Placenta, VENTANA PD-L1 (SP263) Assay: Stroma and vasculature within villi show no PD-L1 staining (20x)

Table 3: Placenta Tissue Control Evaluation Criteria for the VENTANA PD-L1 (SP263) Assay

Interpretation	Staining Description
Acceptable	Moderate to strong uniform membrane staining of trophoblast-lineage cells, and placental stroma and vasculature with no staining
Unacceptable	No to weak uniform membrane staining of trophoblast-lineage cells and/or specific staining within placental stromal and vascular tissue.

Scoring Criteria

A PD-L1 score in NSCLC is assigned by a pathologist based the percentage of tumor cells (% TC) with any membrane staining above background.

A PD-L1 score at the 1% expression level is assigned to cases as described in the PD-L1 Scoring Table below.

Non-evaluable cases include, but are not limited to, cases with insufficient viable tumor, interfering background or decalcification. NSCLC cases with sufficient viable tumor cells (as determined by the scoring pathologist) and no interfering background on the PD-L1 slide are acceptable for evaluation.

Images of various staining patterns and expression levels are provided in the subsequent sections.

PD-L1 Scoring Table

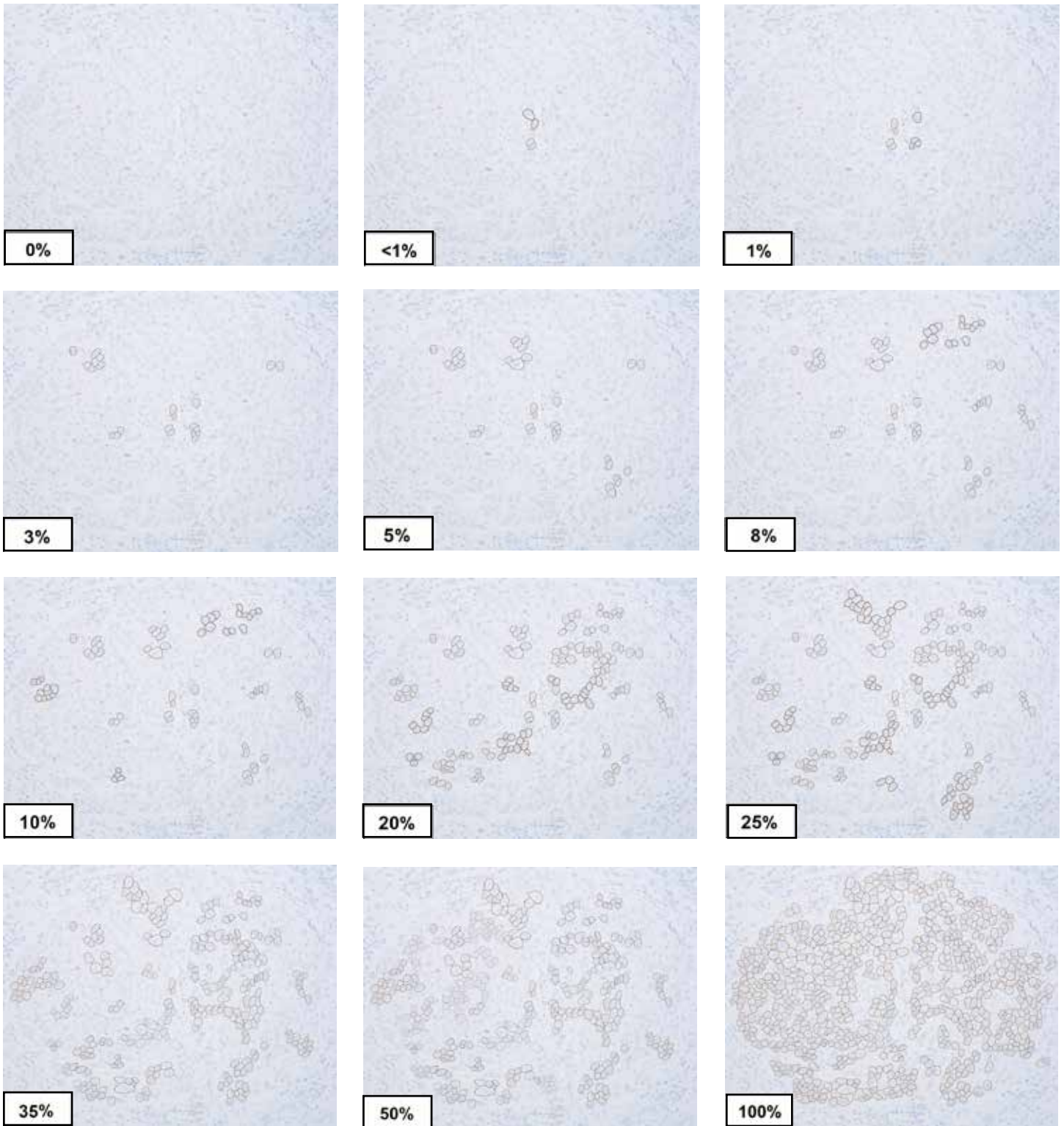
Table 4: VENTANA PD-L1 (SP263) Assay Scoring Algorithm for Tumor Cells - 1% Expression Level

Interpretation	Staining Description
PD-L1 Expression Level < 1%	< 1% of tumor cells with membrane positivity for PD-L1 at any intensity above background staining as noted on the corresponding negative control.
PD-L1 Expression Level ≥ 1%	≥ 1% of tumor cells with membrane positivity for PD-L1 at any intensity above background staining as noted on the corresponding negative control.

Evaluation of percent membrane staining

The following pictorial guide demonstrates a quantitative spectrum of tumor cell membrane staining on a sample field of NSCLC containing viable tumor cells for the sake of illustration only. Expression levels of 0% to 100% of tumor cells with membrane staining have been

illustrated as a representative gauge in order to assist the pathologist when evaluating PD-L1 staining. It is at the discretion of the pathologist to determine sample sufficiency.

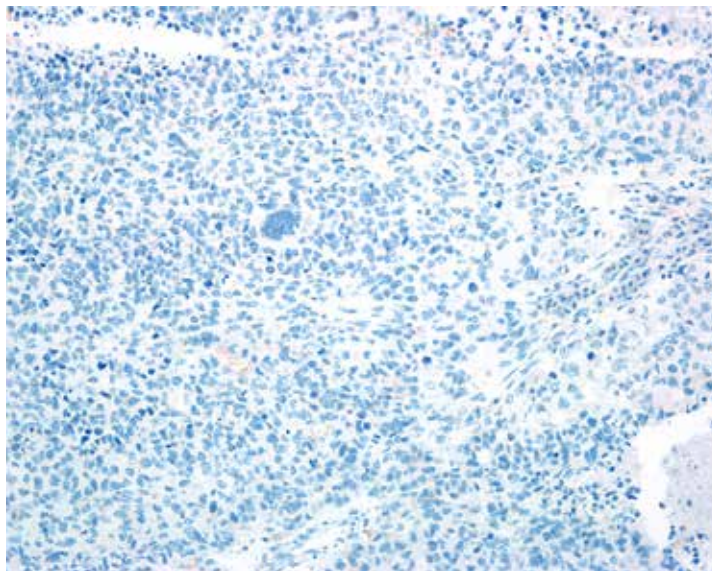
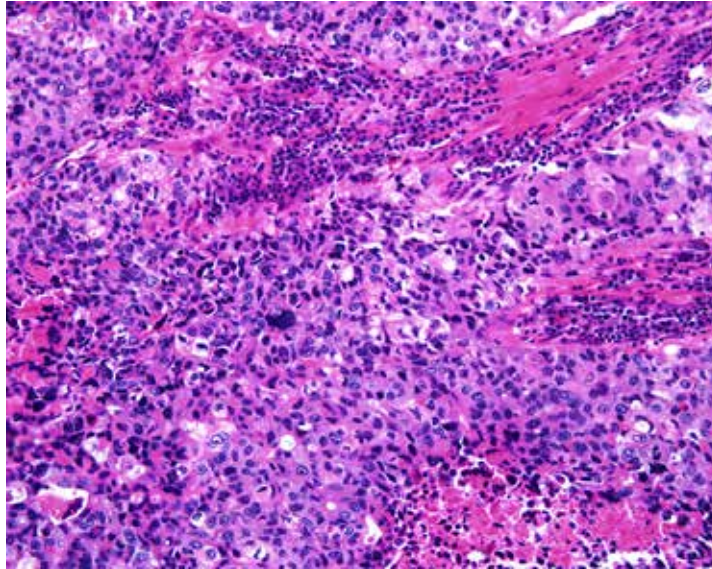


PD-L1 Expression Atlas in NSCLC

Photo Gallery

Staining is characterized by the presence of any detectable signal above background as noted on the corresponding negative isotype control by membranous staining of neoplastic cells. This expression atlas contains examples of expression levels in various fields of view.

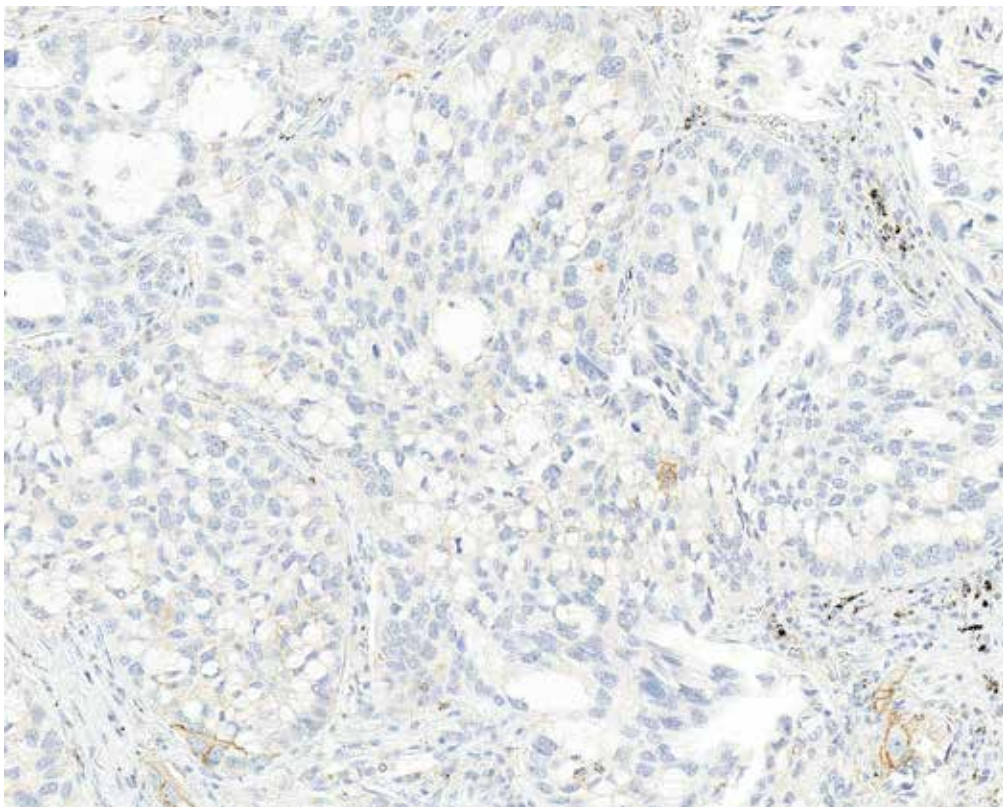
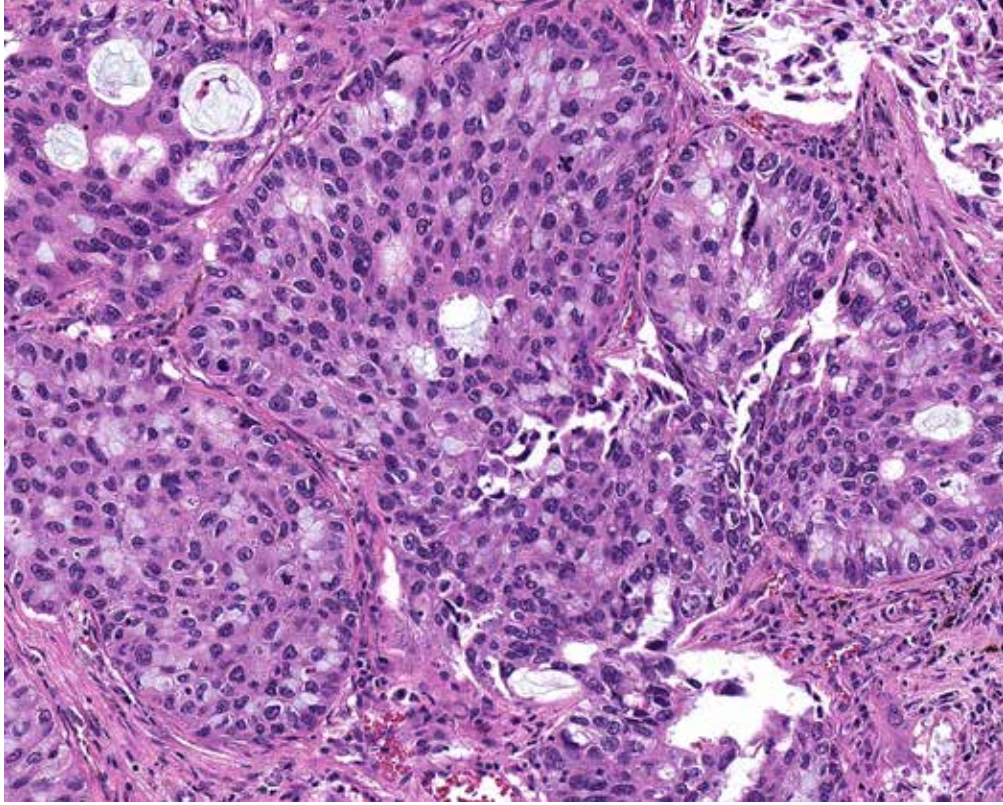
Light tumor cell membrane staining is not easily discerned at lower power and may require patient and methodical examination of the stained slide at higher power, especially in cases where there is accompanying weak cytoplasmic staining.



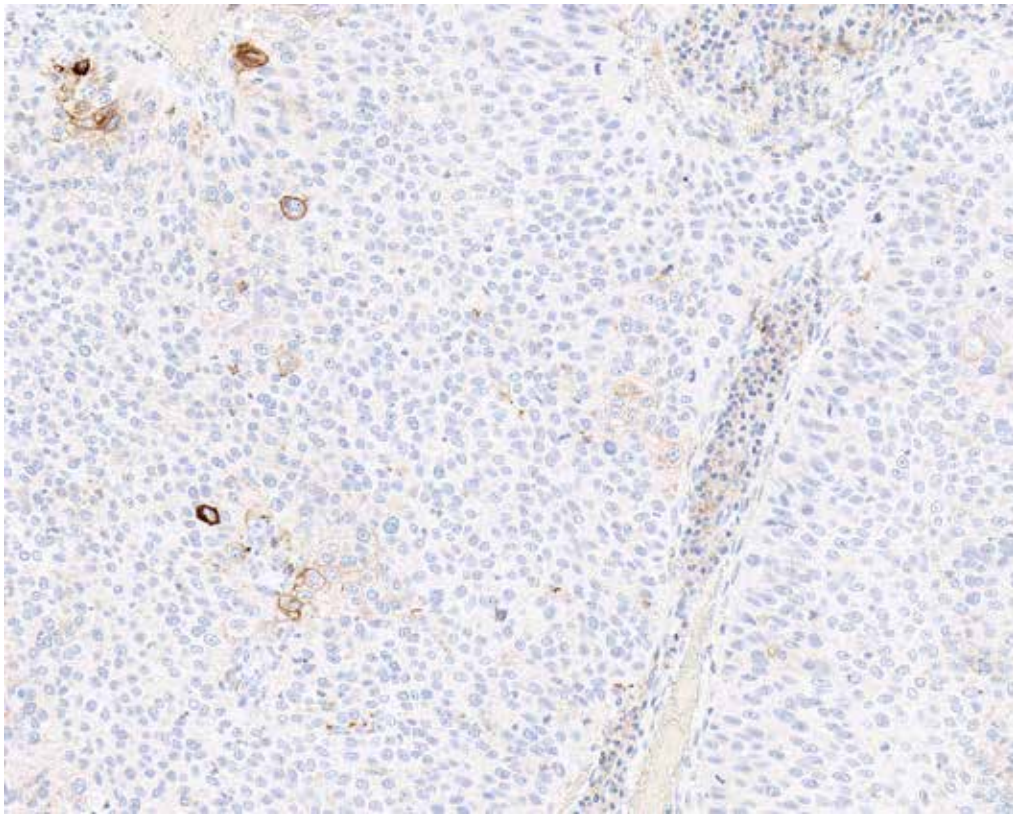
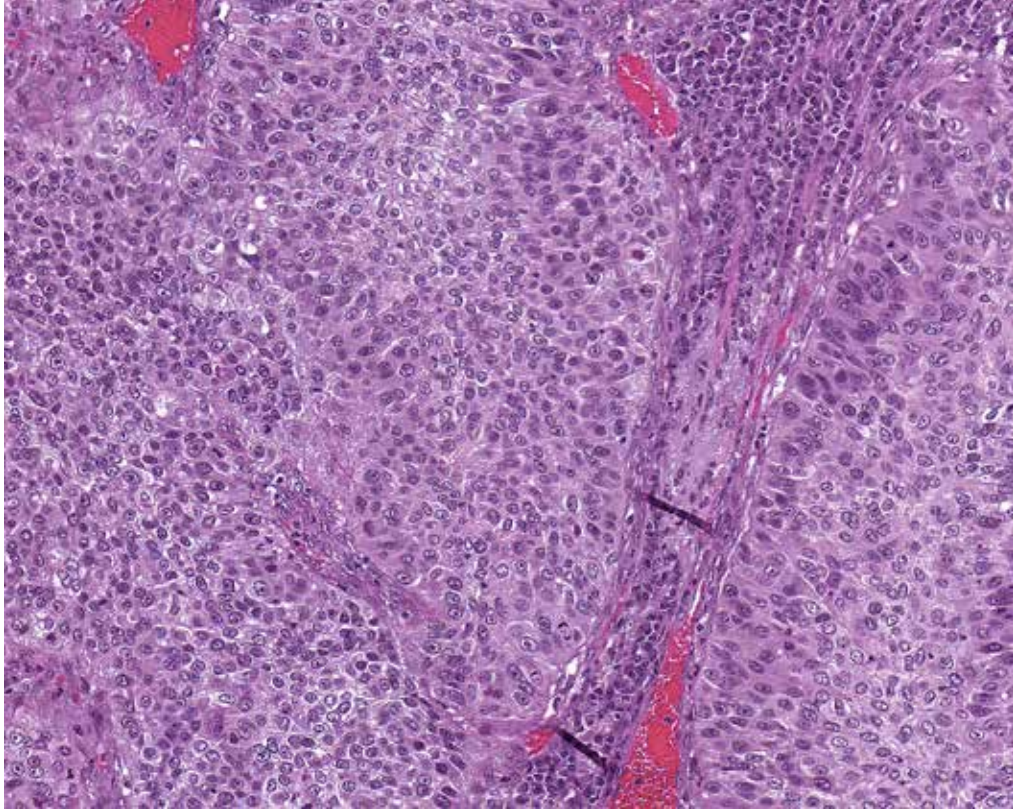
Case 1: Negative tumor and immune cell staining (zero percent). (20x)

For cases demonstrating PD-L1 expression at the low end of the spectrum, any alveolar macrophage or histiocytic membrane staining must be identified in order to avoid misinterpretation as tumor cell staining. Referring back to the H&E slide can aid in the differentiation between tumor and immune cells. Because the difference between

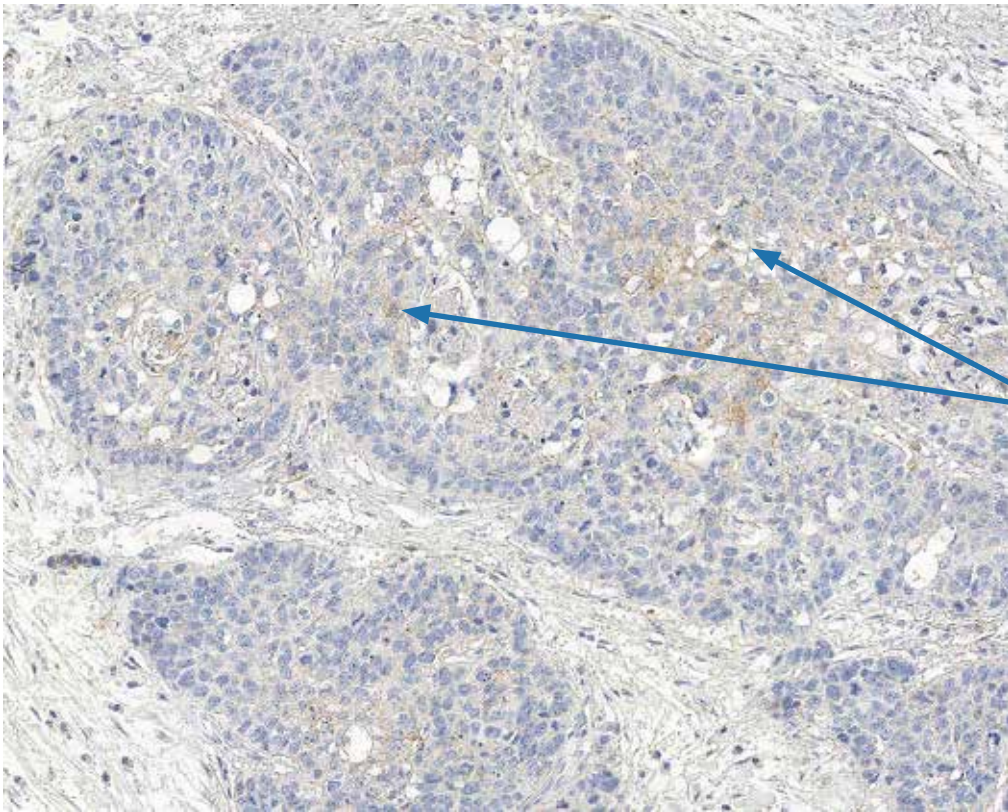
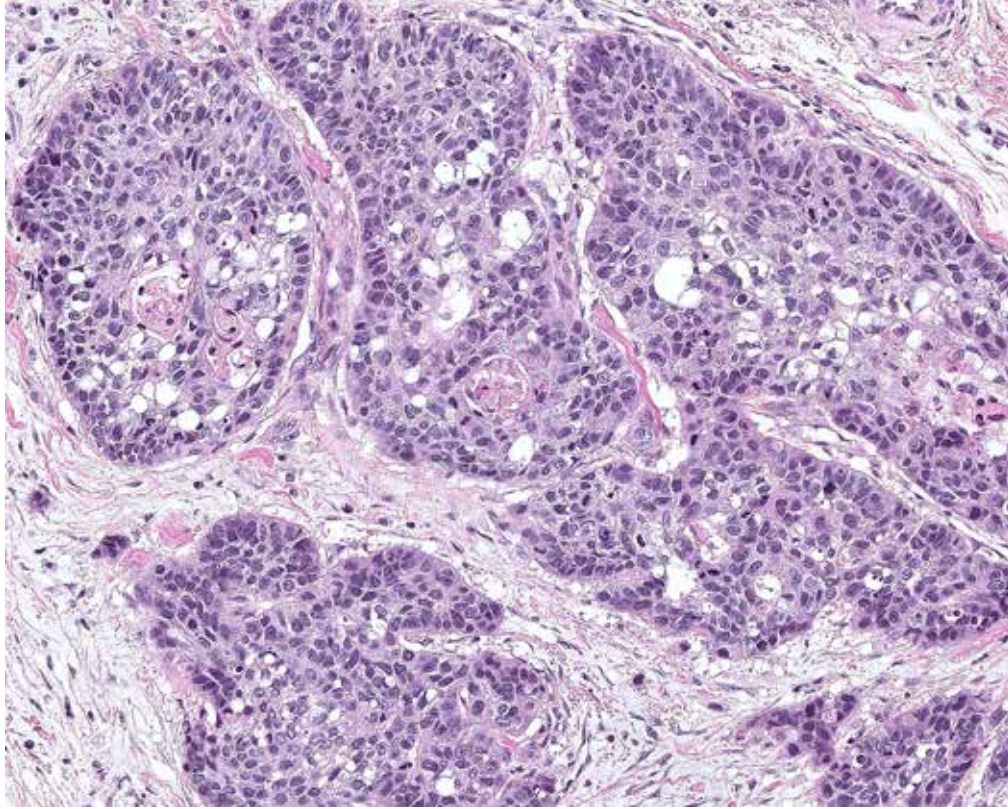
less than 1% and 1% PD-L1 expression are subtle, it is important that the pathologist become calibrated to slight expressions. Using visual estimation to approximate the number of stained tumor cells and total number of tumor cells, one can become adept at calibrating for slight differences in expression level.



Case 2: Less than 1% of tumor cells exhibit membrane staining. (10x)

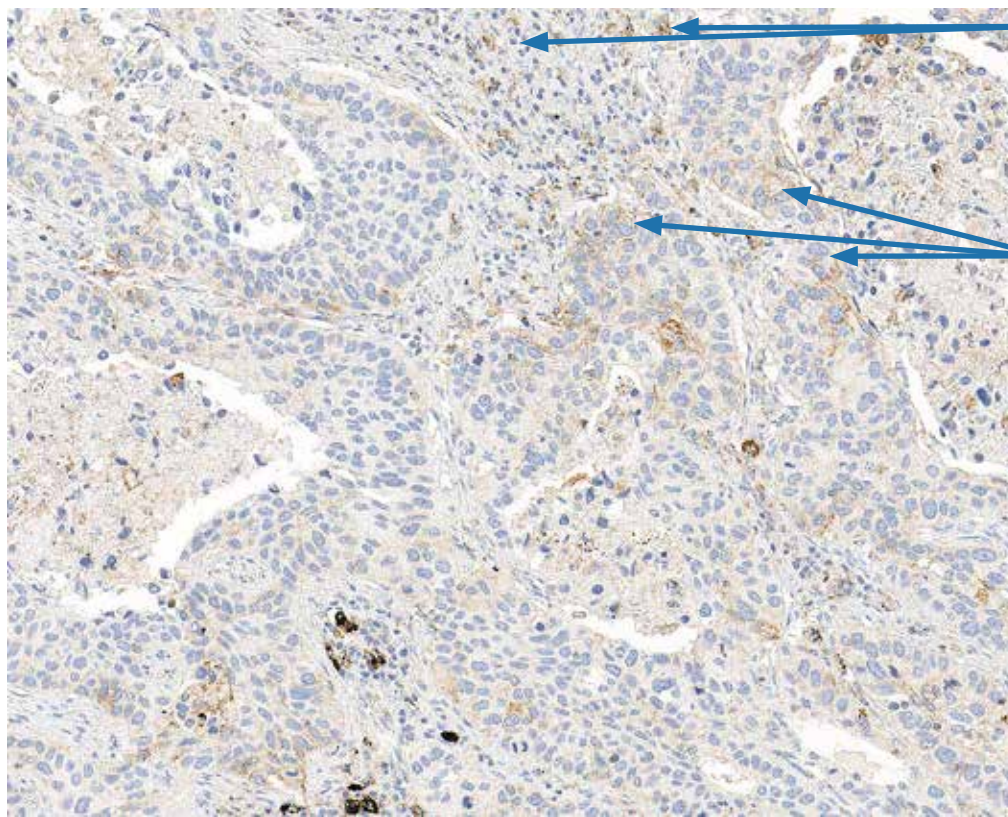
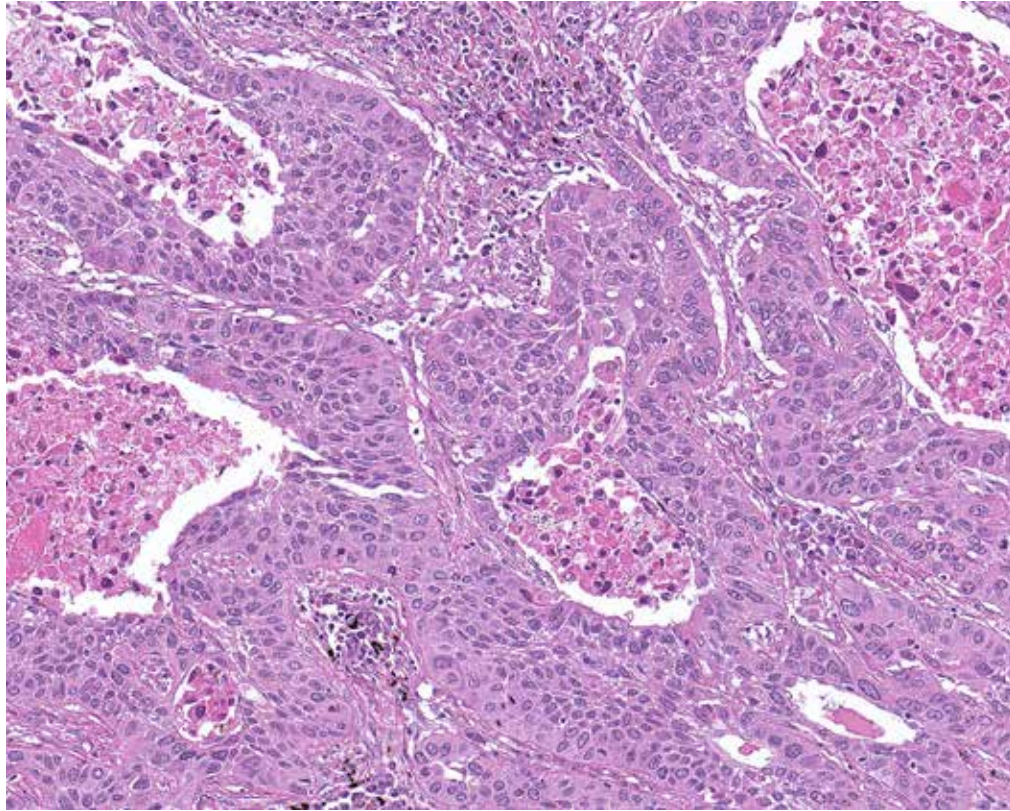


Case 3: 2% of tumor cells exhibit membrane staining. (10x)



Weak TC
membrane staining

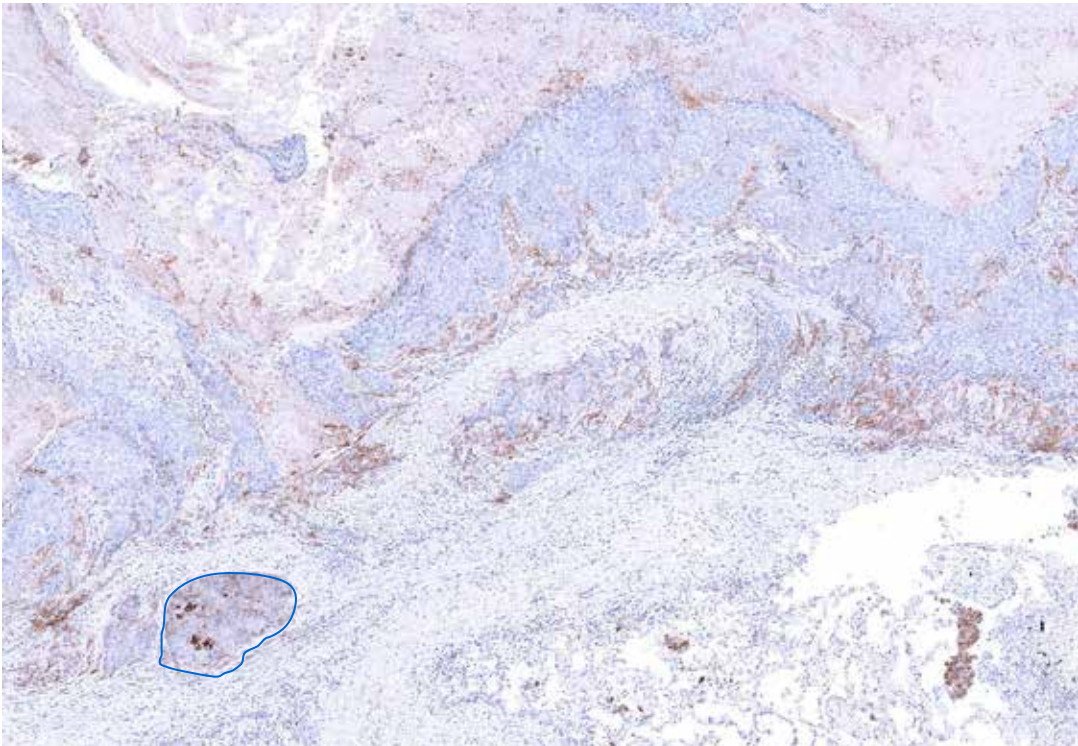
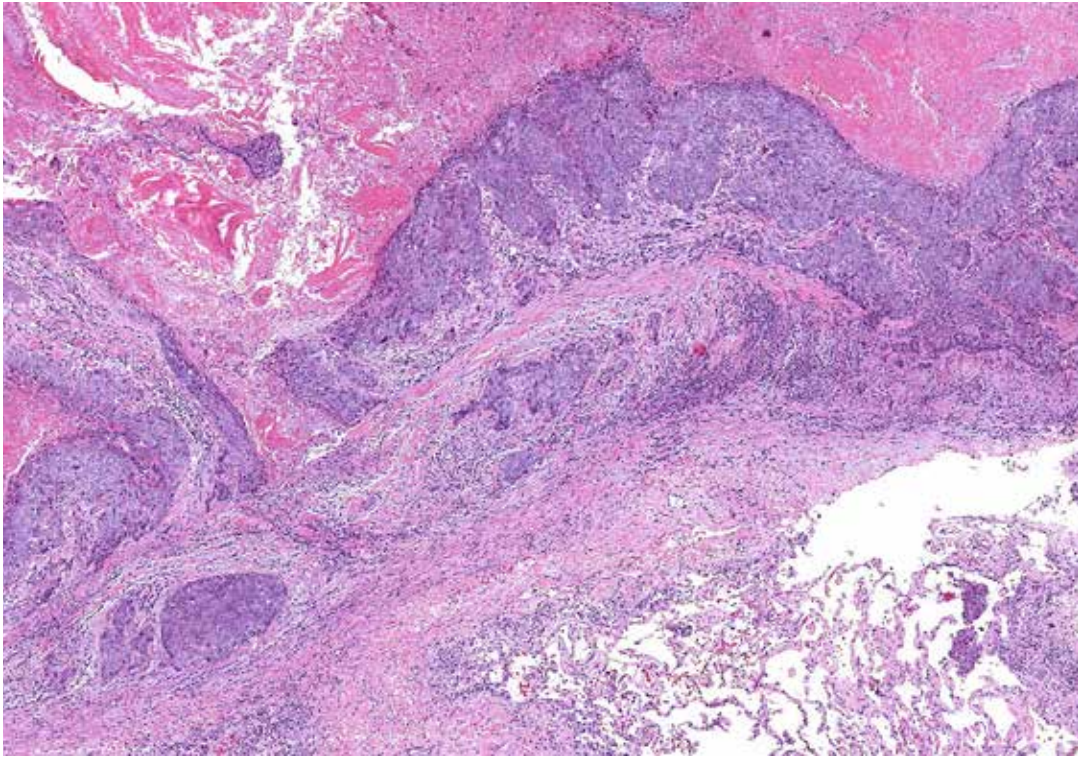
Case 4: 3% of tumor cells exhibit membrane staining. Faint cytoplasmic blush is also present, which does not count towards score estimation. (10x)



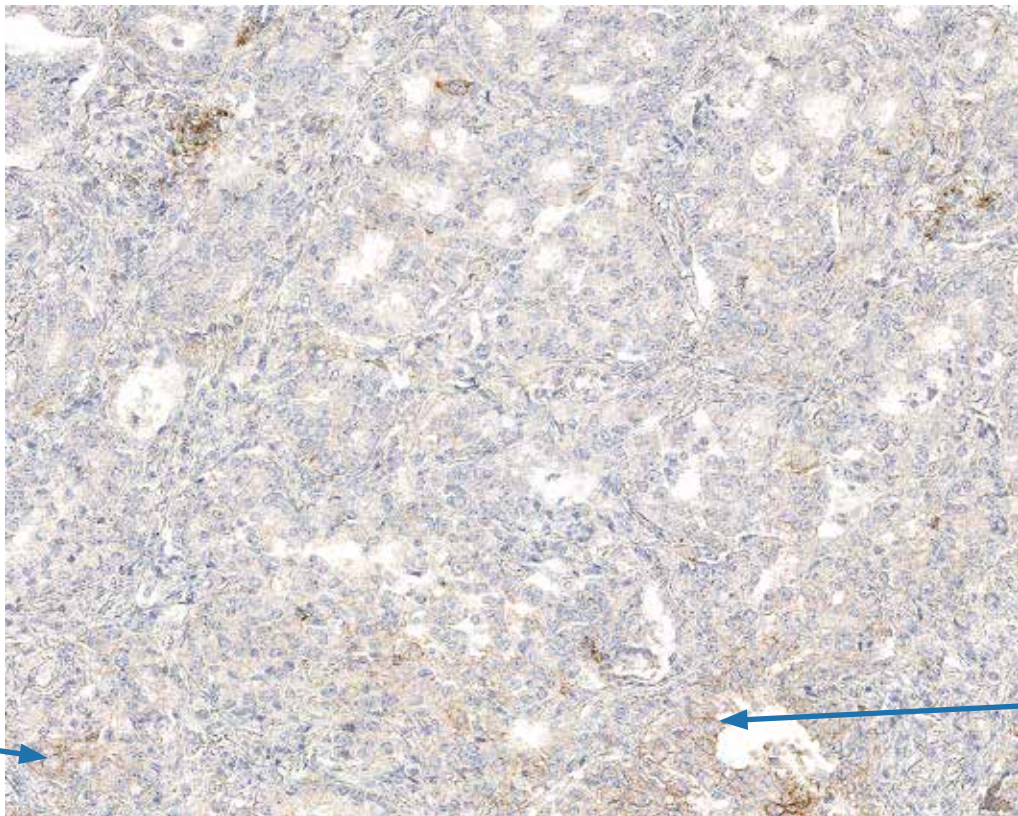
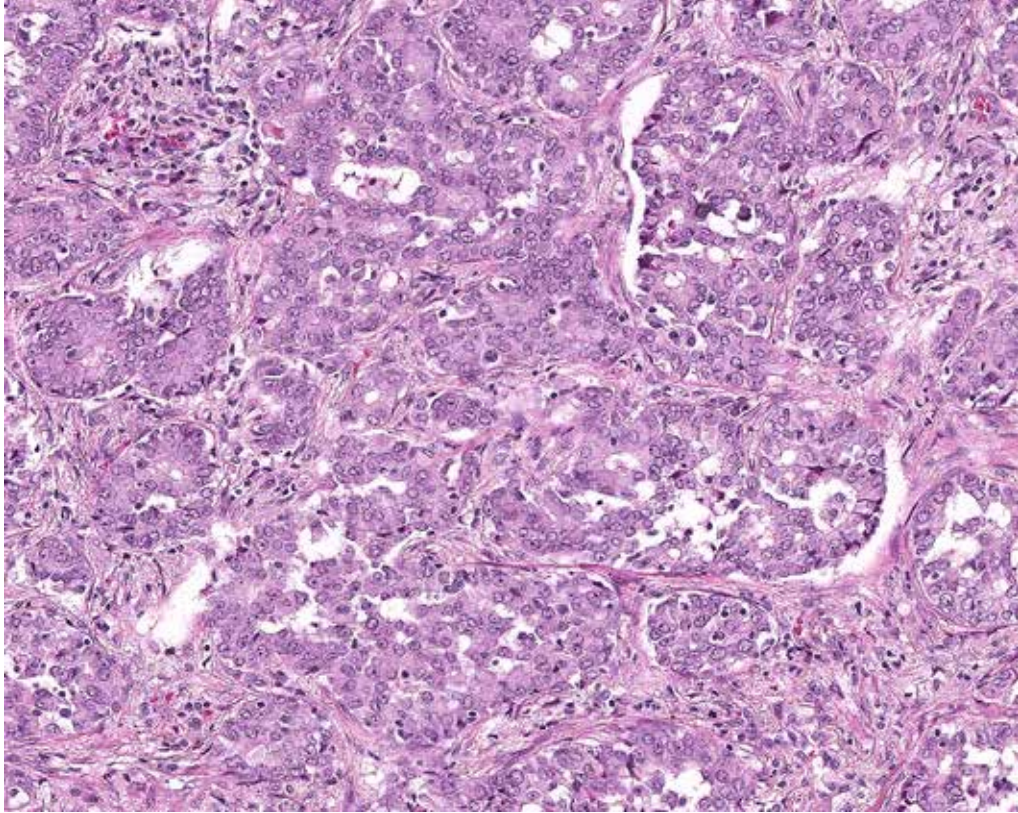
IC staining

Weak TC membrane staining

Case 5: 4% of tumor cells exhibit membrane staining. IC also exhibit PD-L1 staining. Ensure that only TC membrane staining is counted towards score estimation. (10x)



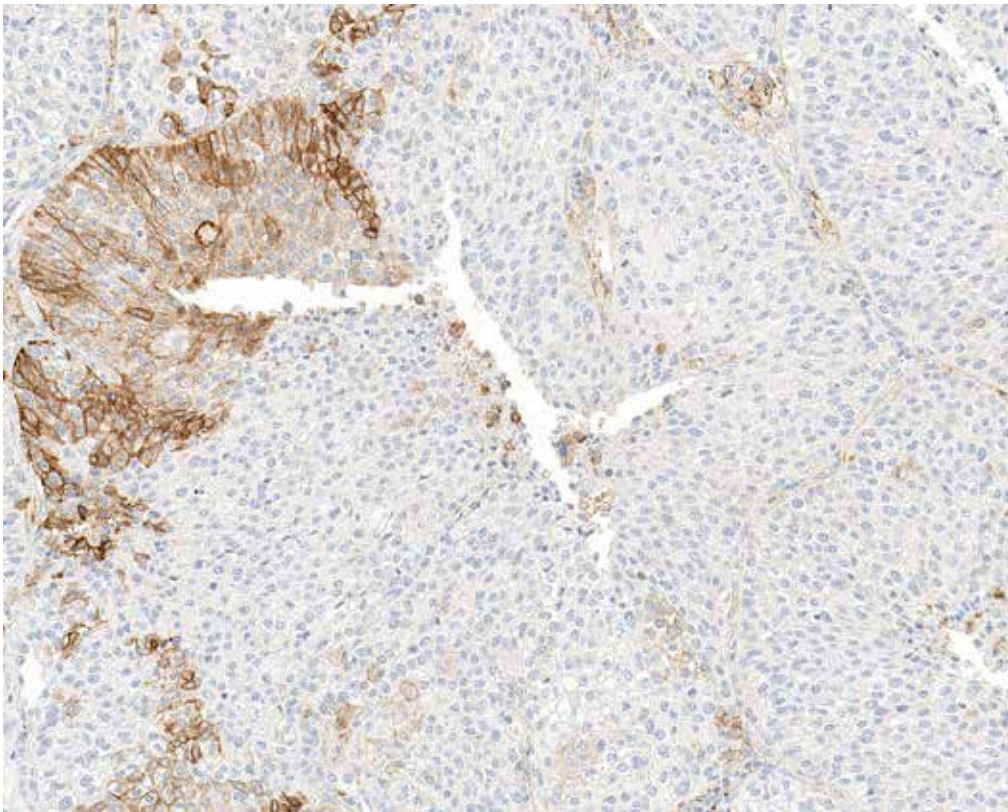
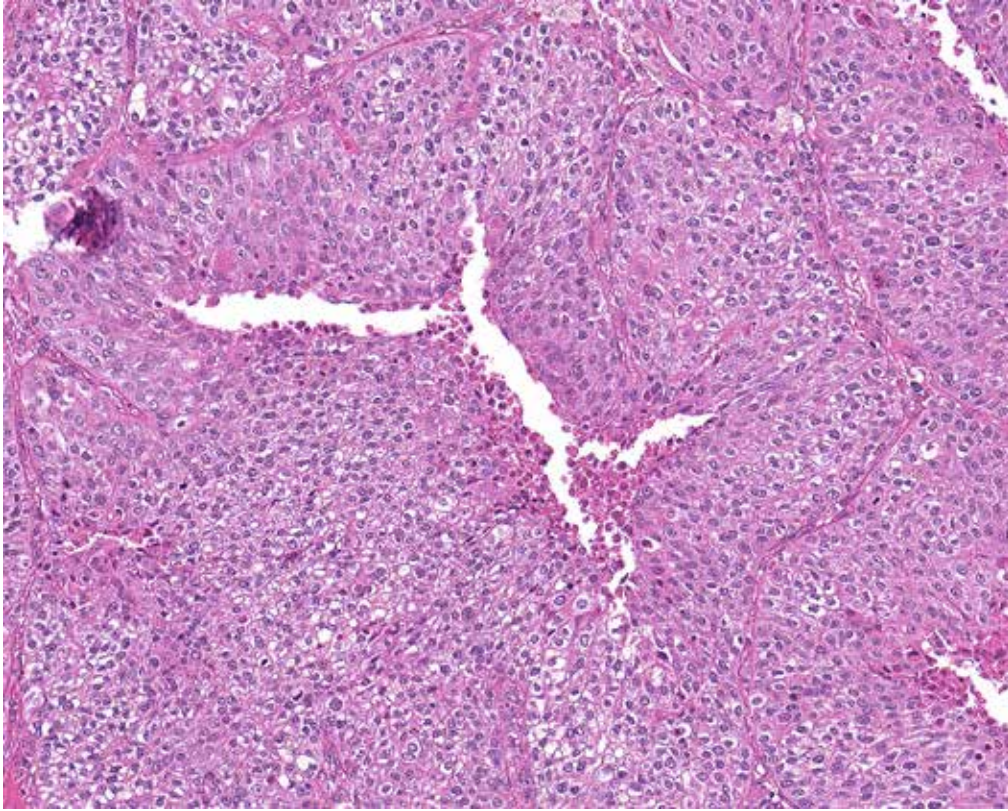
Case 6: Tumor with 5% cells demonstrating membrane staining outlined in blue. Tumor area (consisting of viable tumor and surrounding desmoplasia and inflammation) contains focal areas with immune cells showing PD-L1 expression. (4x)



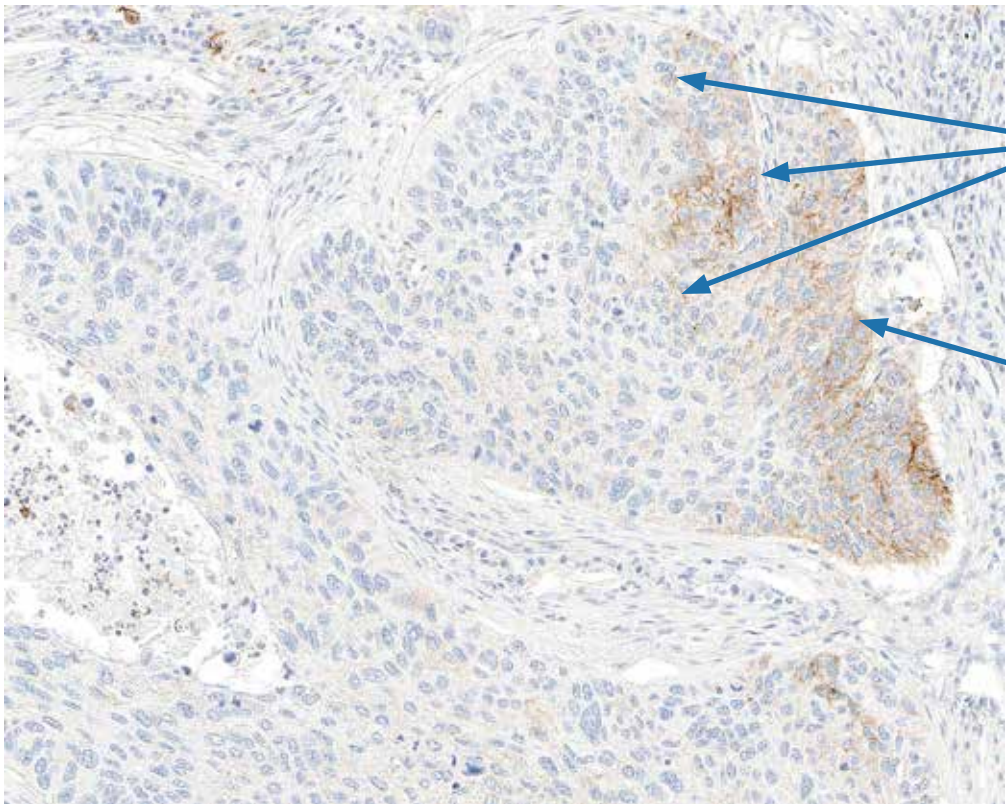
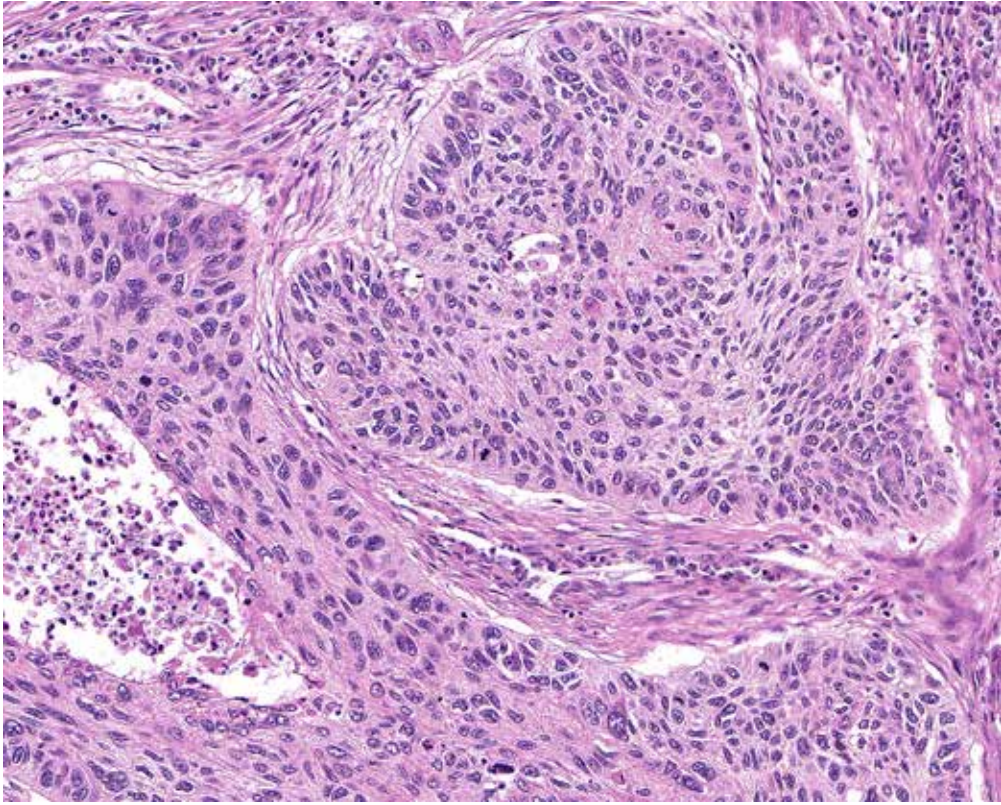
TC membrane staining

TC membrane staining

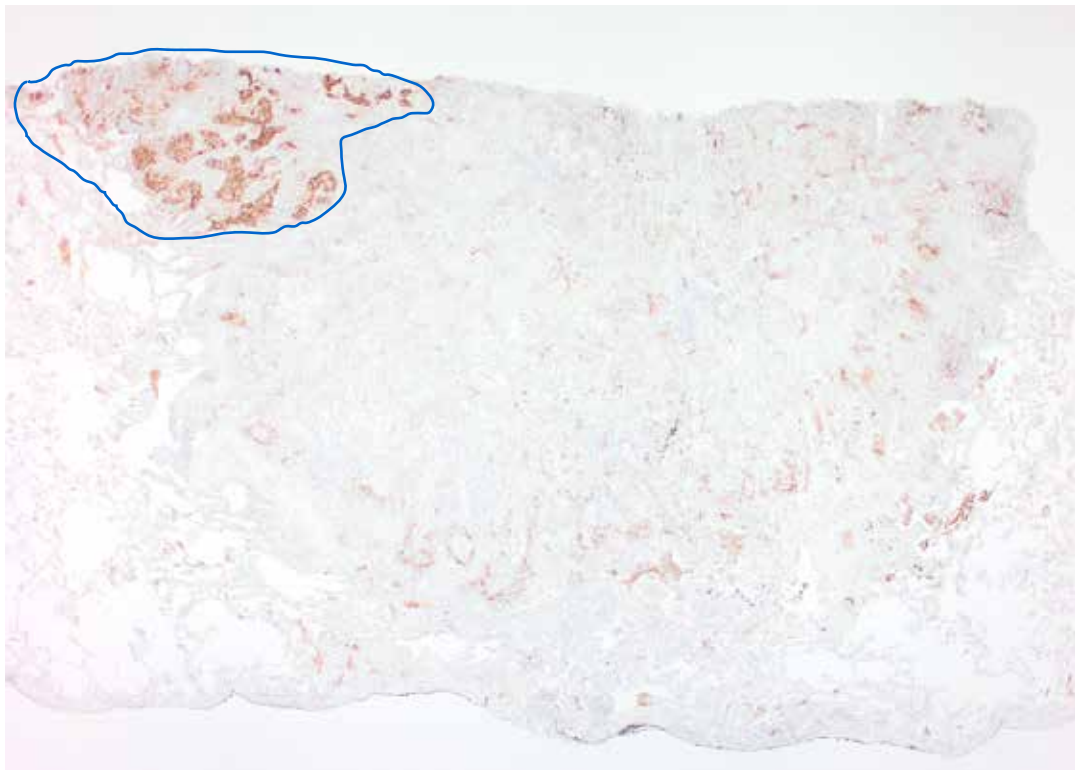
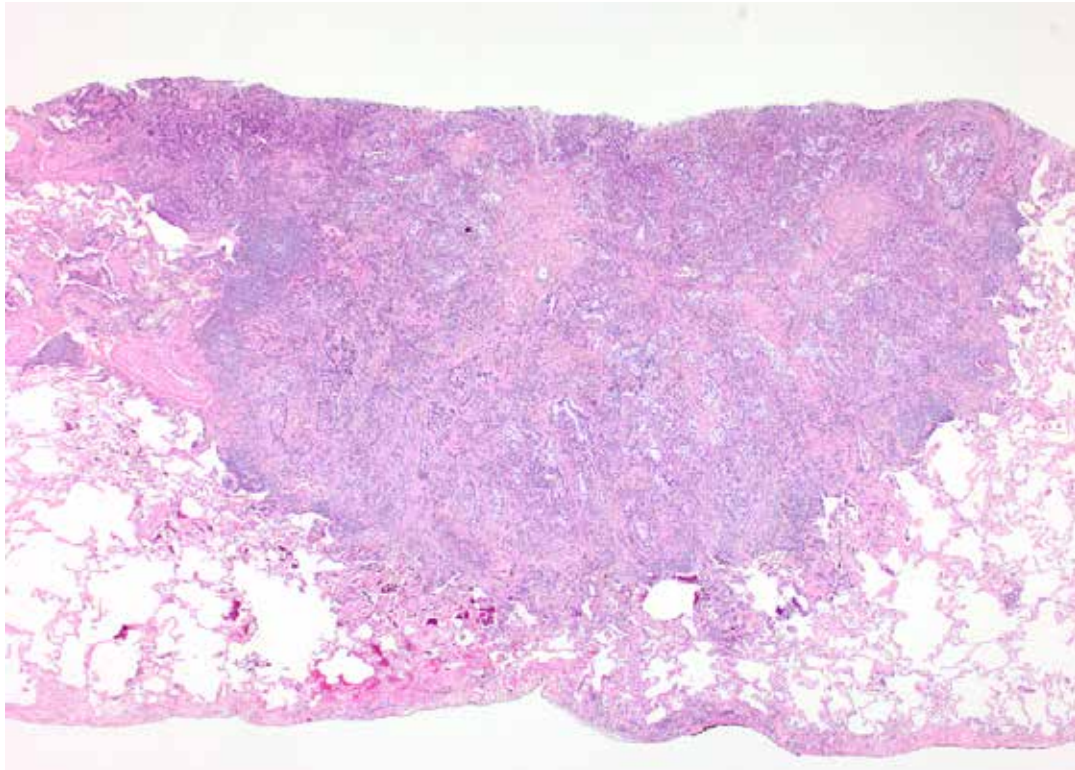
Case 7: 7% of tumor cells exhibit membrane staining. (10x)



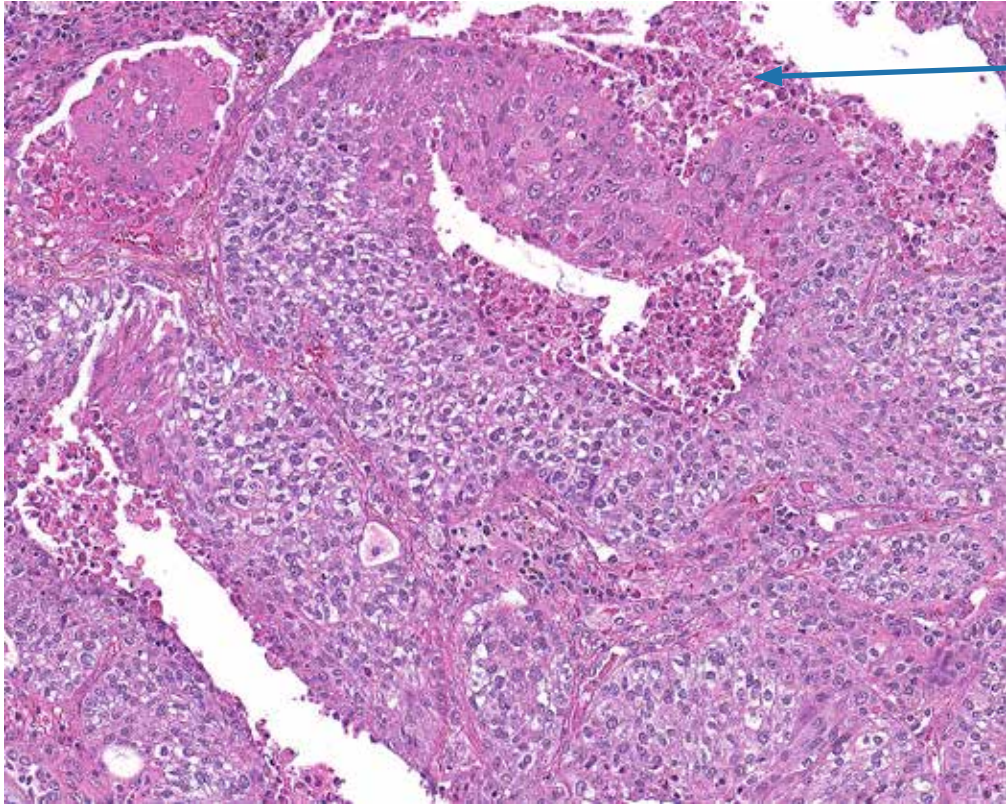
Case 8: 9% of tumor cells exhibit membrane staining. Darker staining is easier to identify from low power, but utilize higher power objectives to ensure weak membrane staining is not missed. (10x)



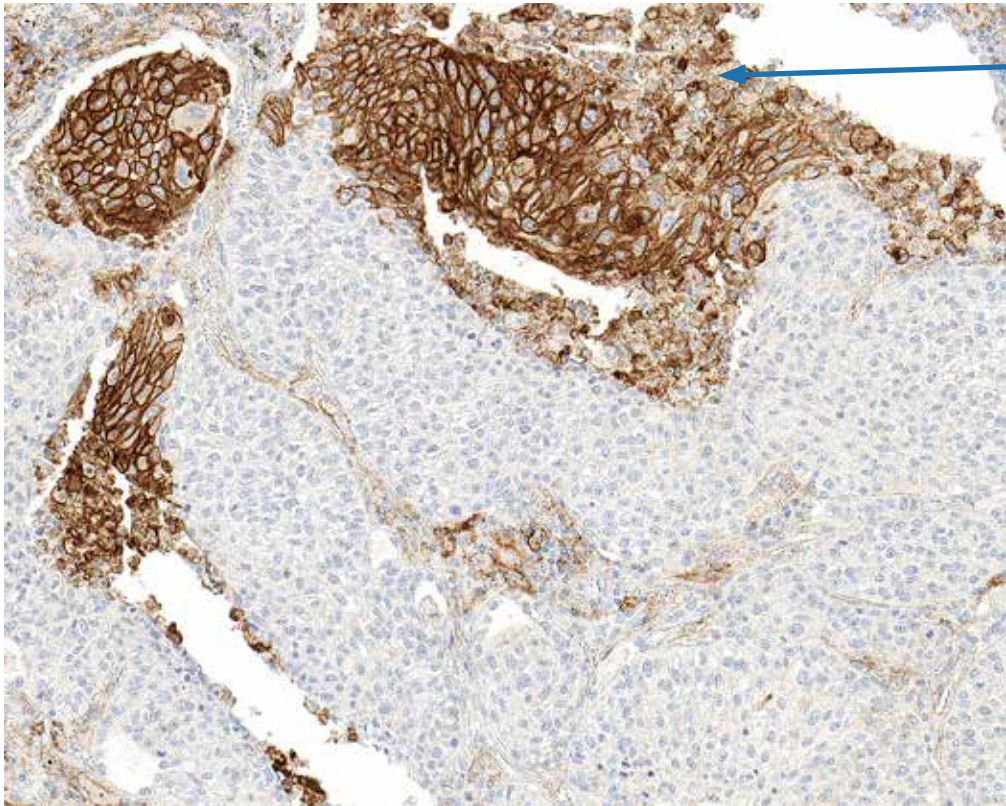
Case 9: 12% of tumor cells exhibit membrane staining. (10x). Scan at low power and then resolve cytoplasmic staining from membrane staining at higher powers.



Case 10: Tumor with 15% of cells showing membrane staining (blue outline). Tumor-associated immune cell staining is also seen (2x)

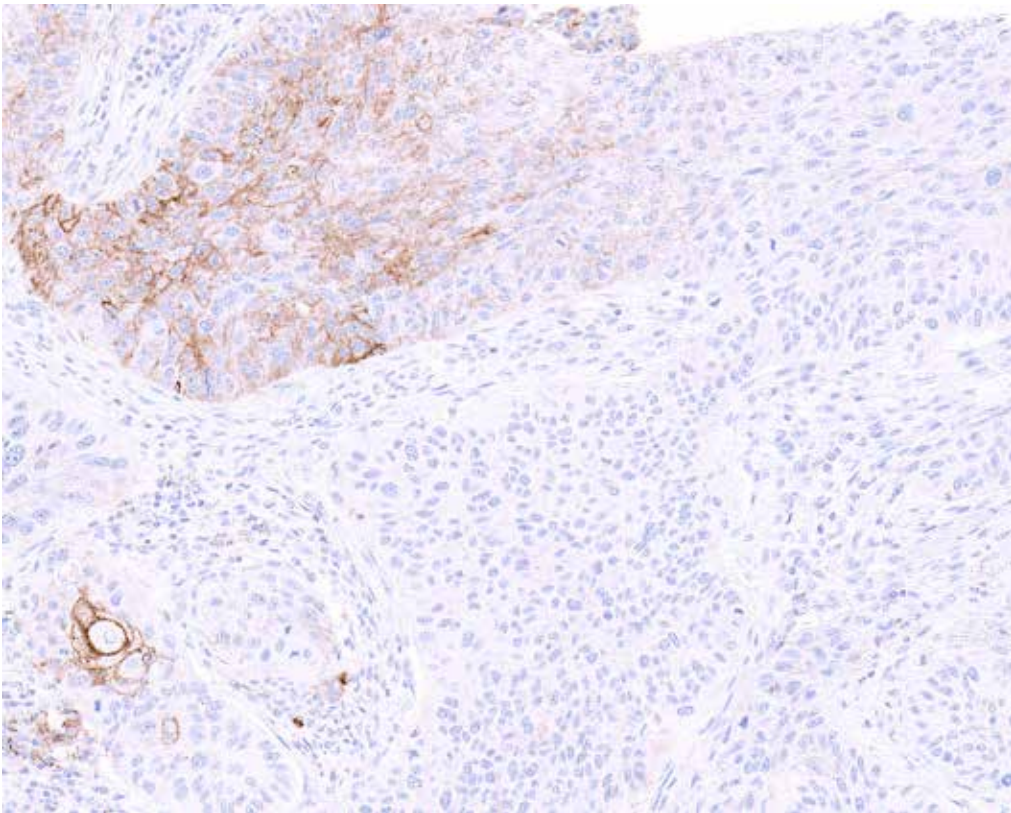
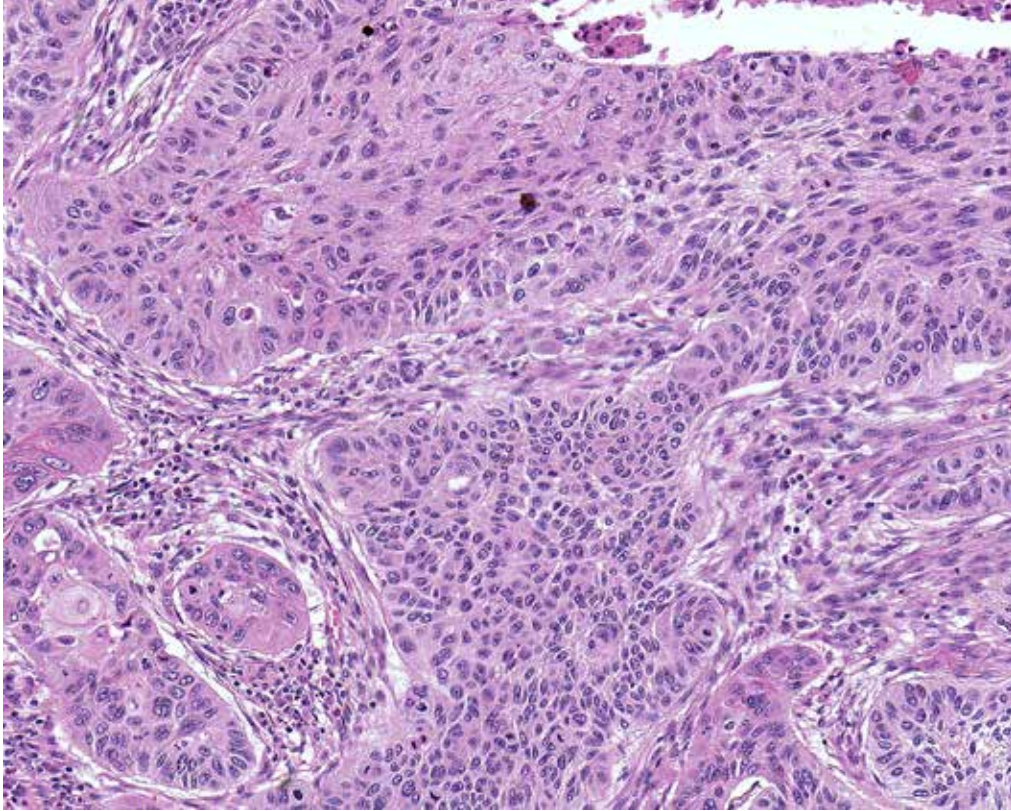


Area of necrosis

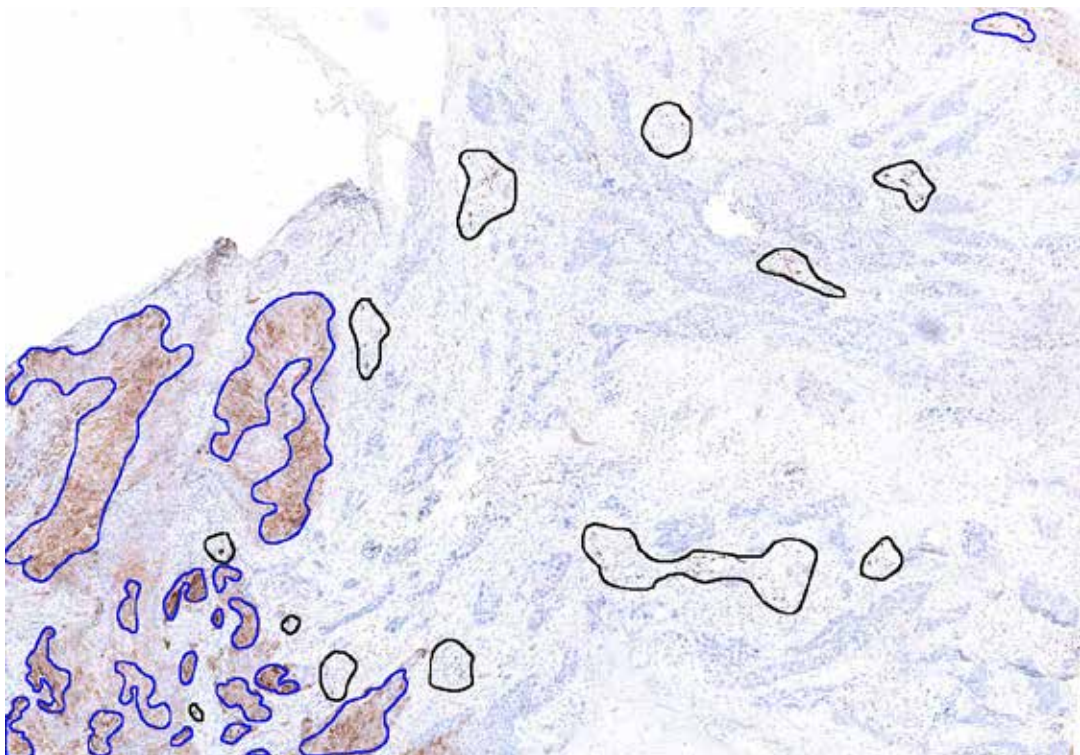
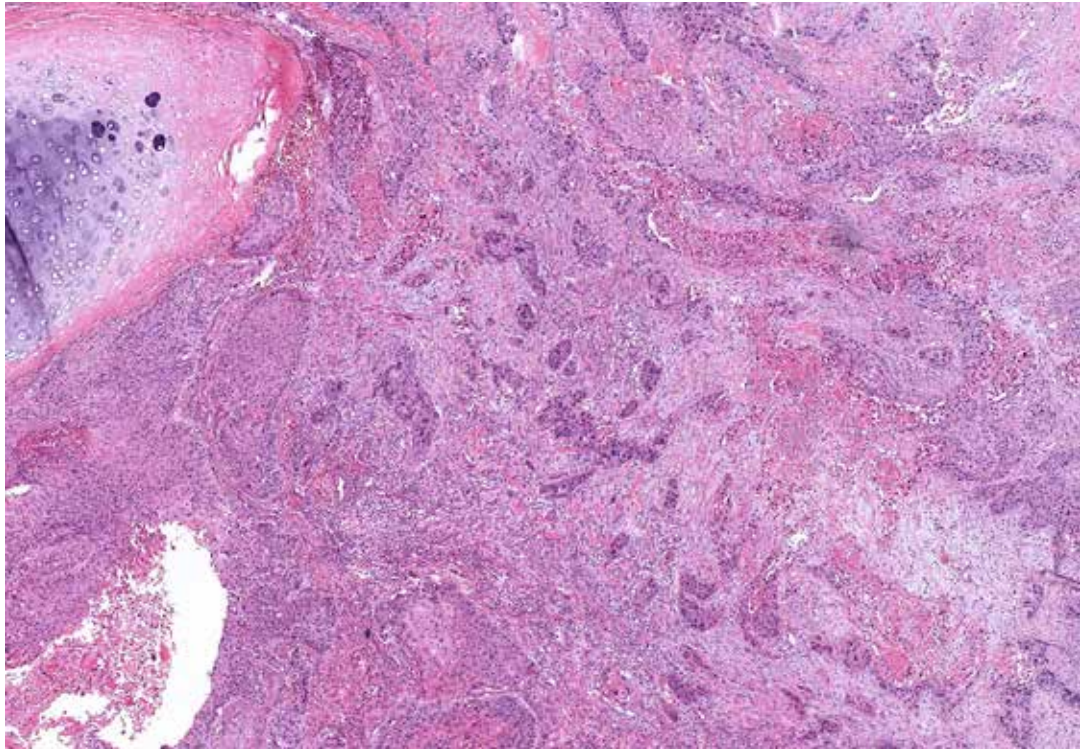


Area of necrosis

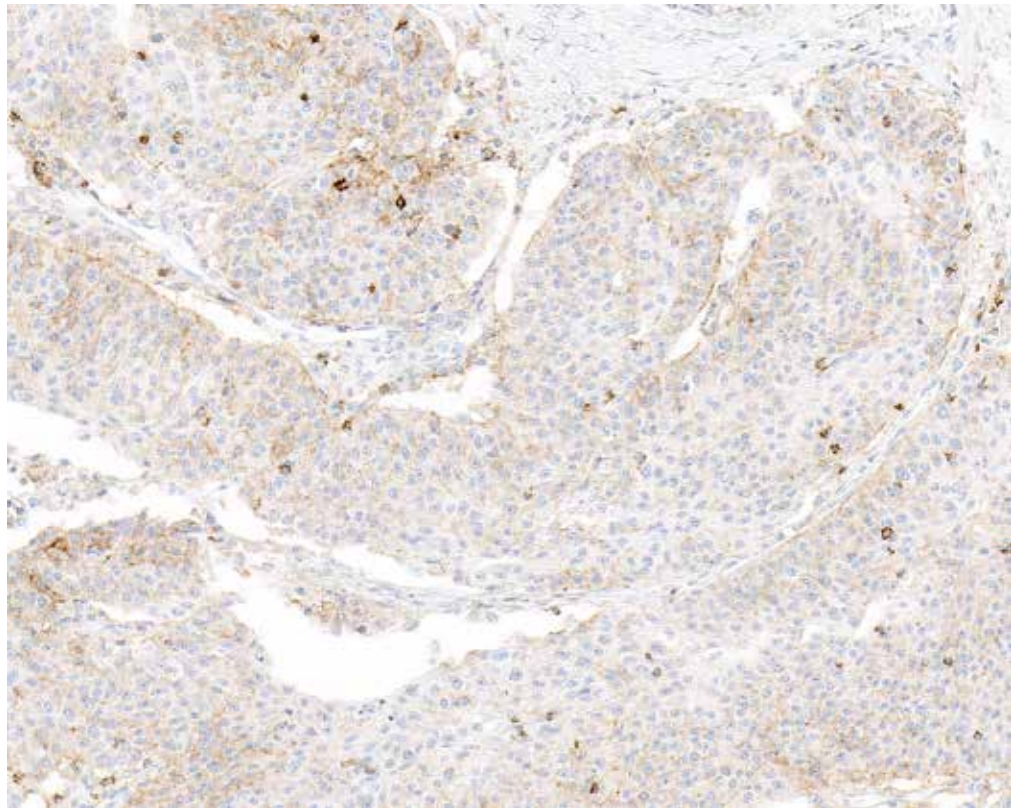
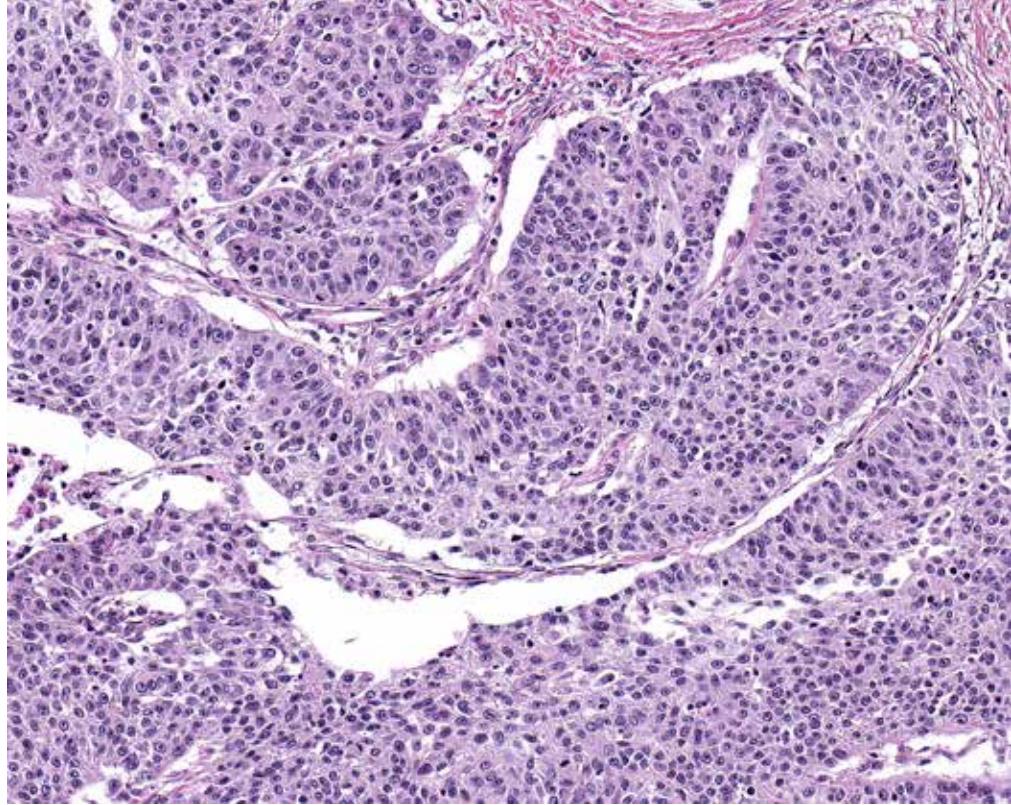
Case 11: 20% of tumor cells exhibit membrane staining. Take care to exclude signal in necrosis and IC from score estimation. (10X)



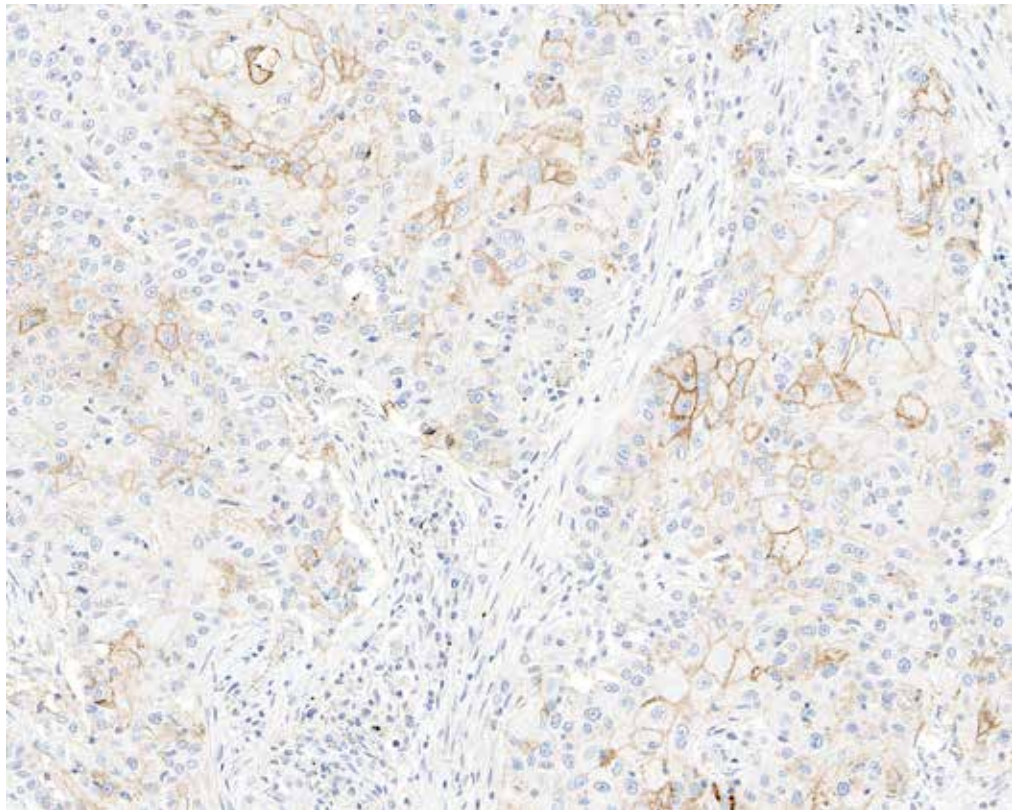
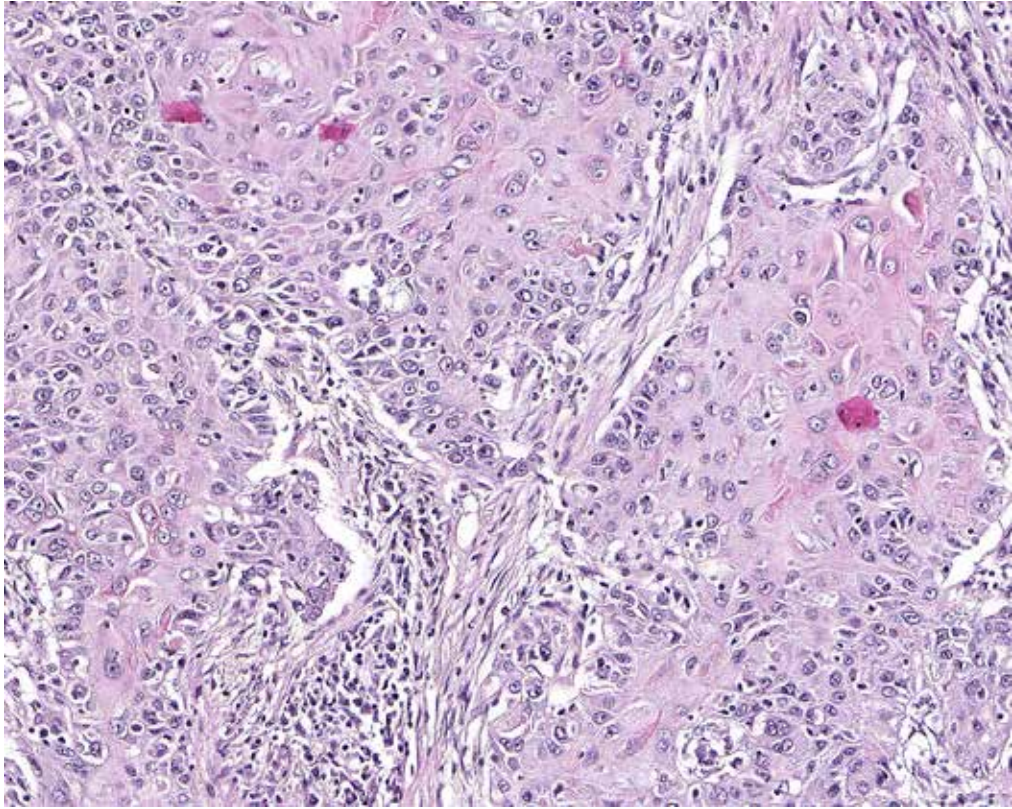
Case 12: 25% of tumor cells exhibit membrane staining. (10x)



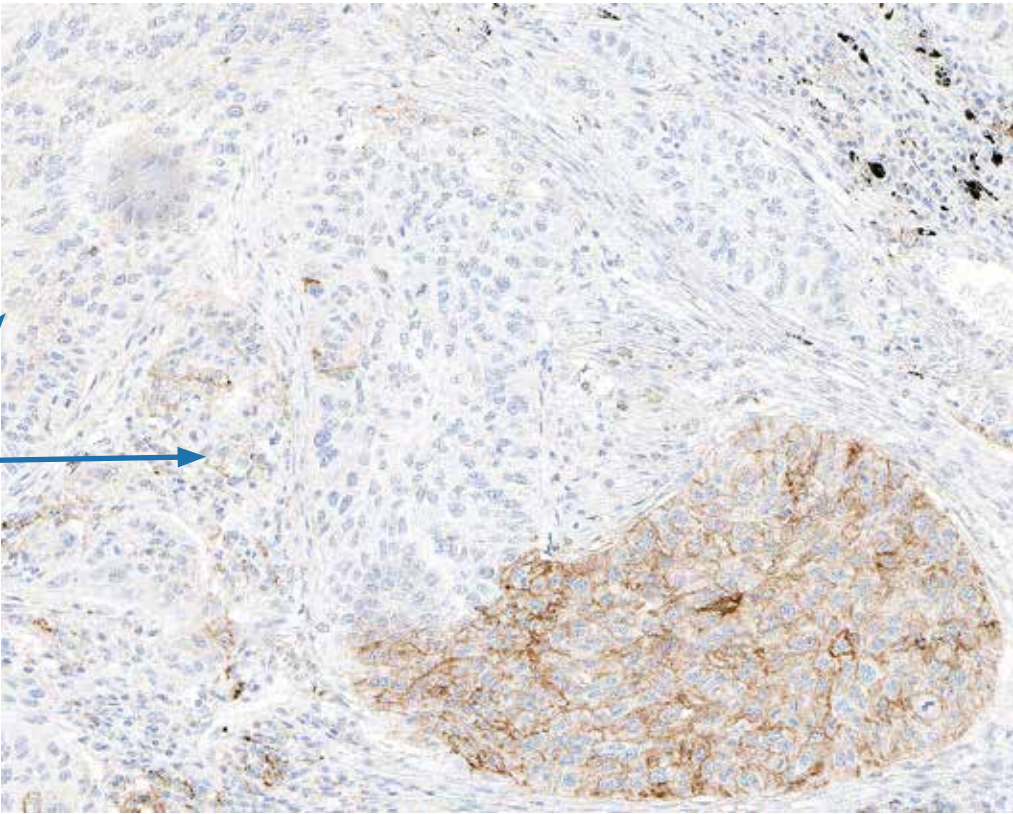
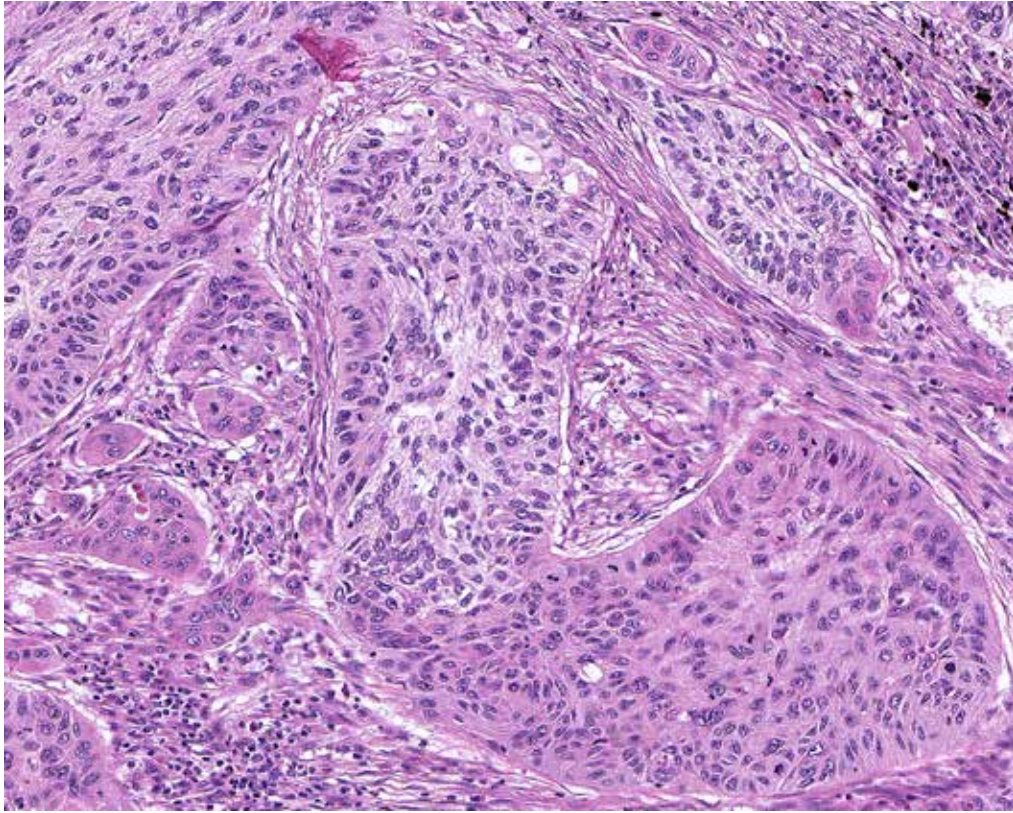
Case 13: Tumor with 35% of cells demonstrating membrane staining in this field (blue outlines). Tumor area contains some immune cells with PD-L1 expression (black outlines). (4x)



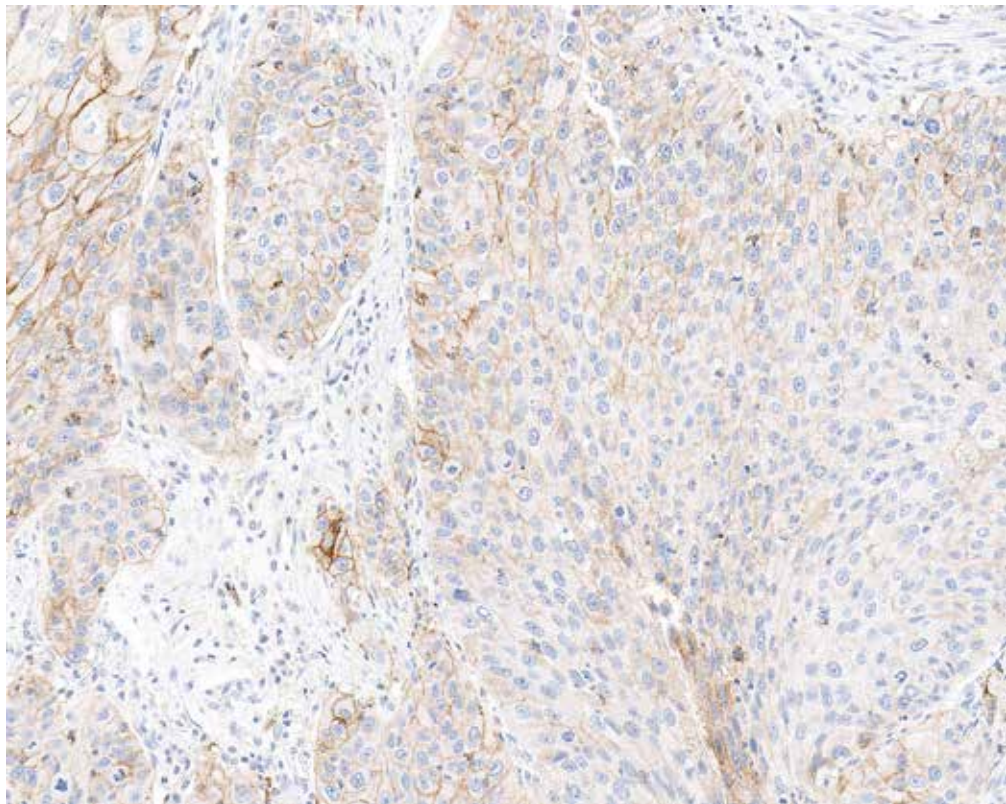
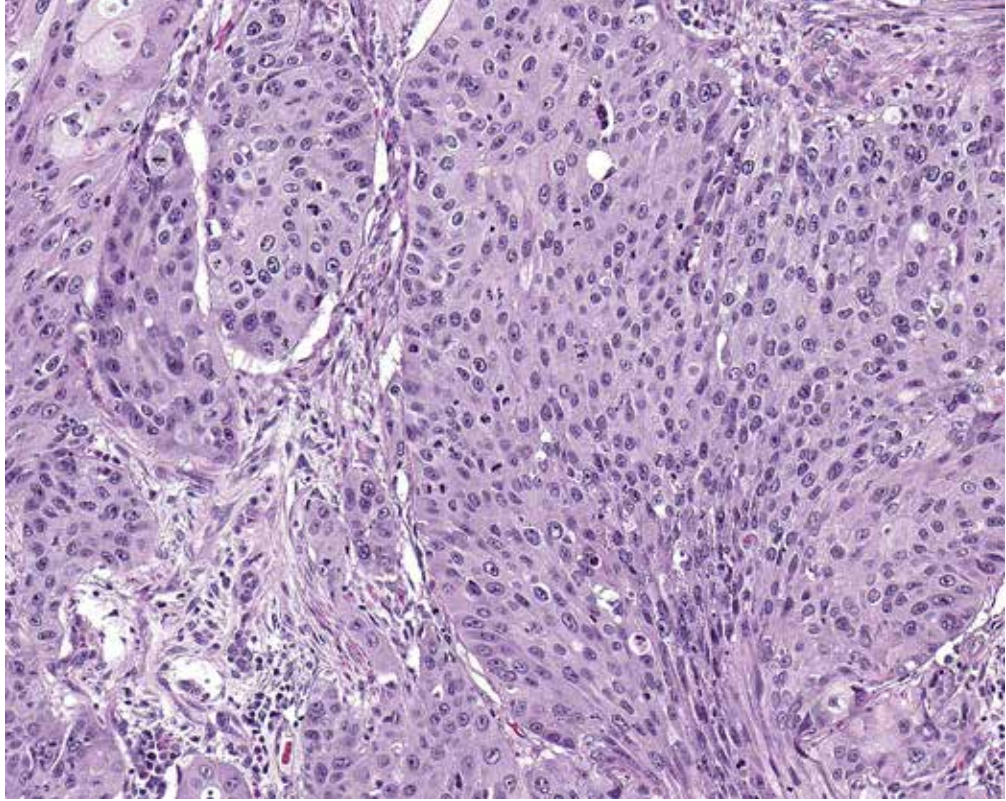
Case 14: 35% of tumor cells exhibit membrane staining. The majority of TC exhibit cytoplasmic blush with roughly a third of TC exhibiting weak to moderate membrane staining. (10x)



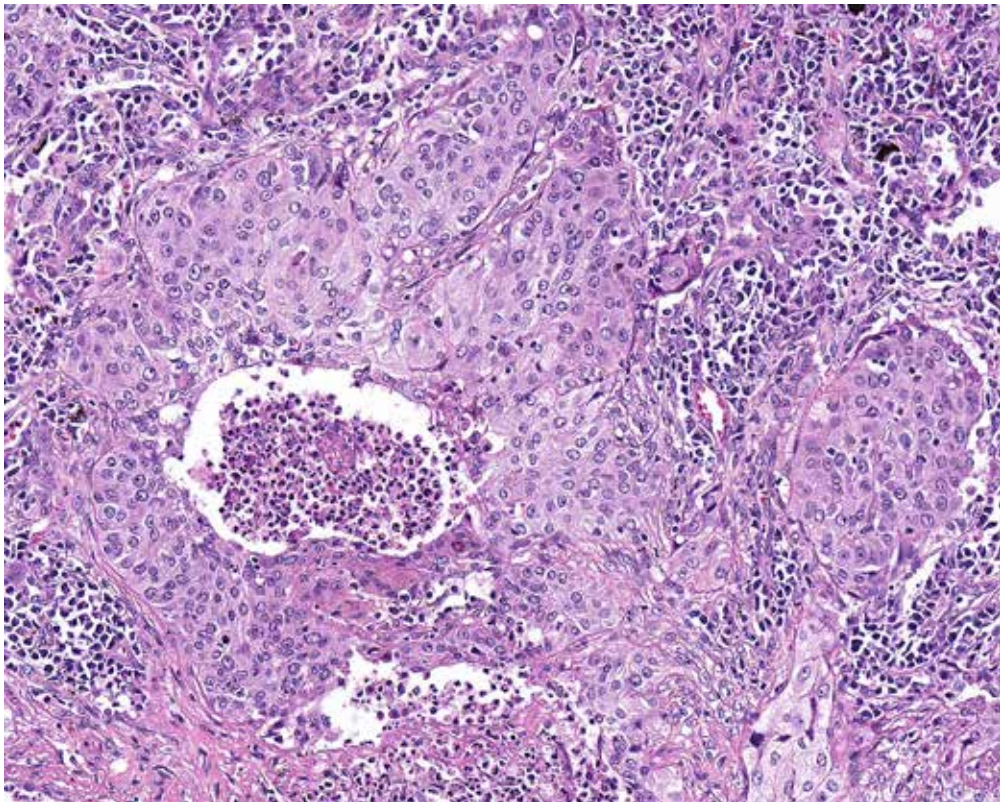
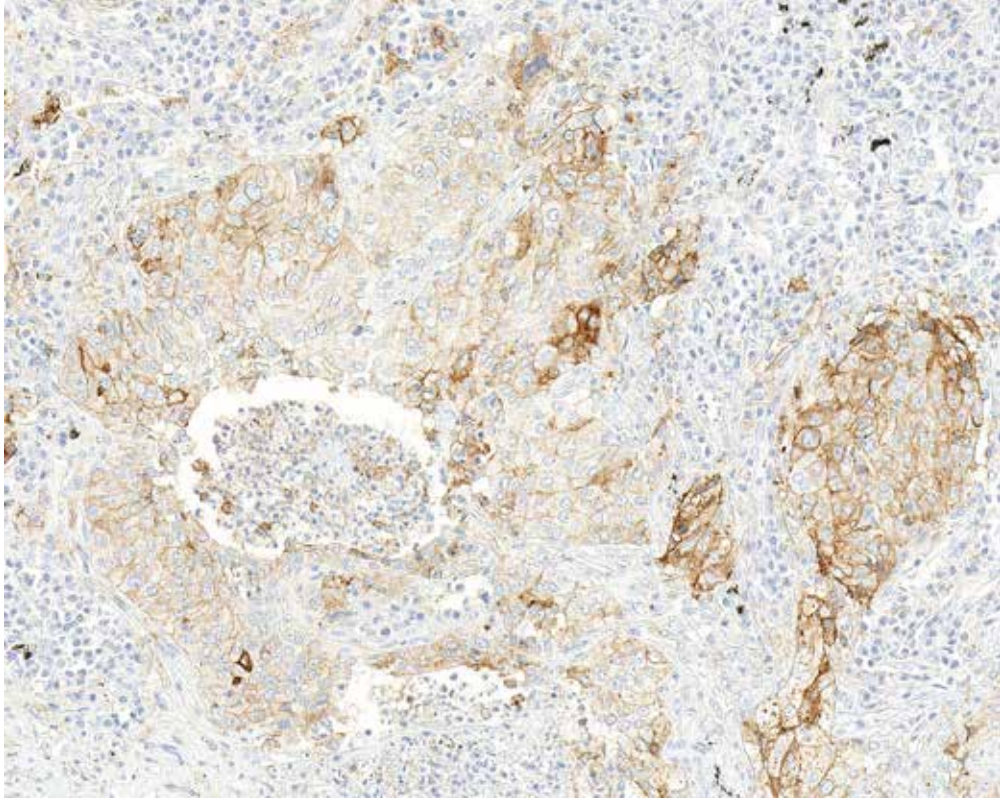
Case 15: 40% of tumor cells exhibit membrane staining. Note that majority of TC exhibiting PD-L1 staining show weak membrane staining. (10x)



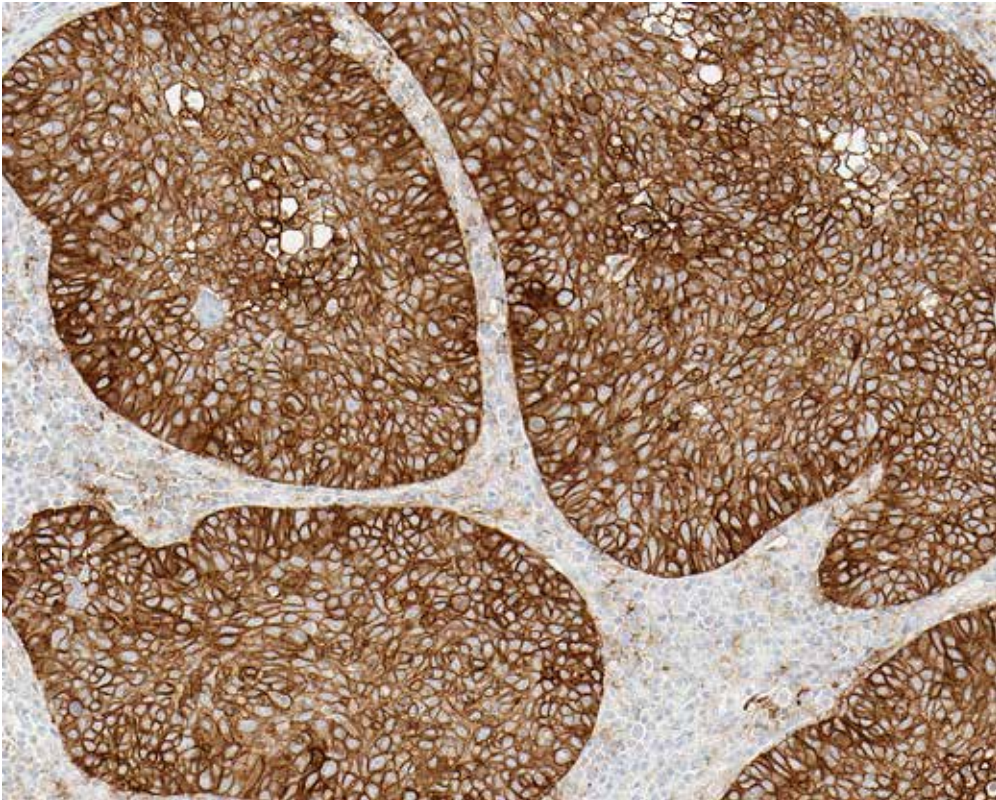
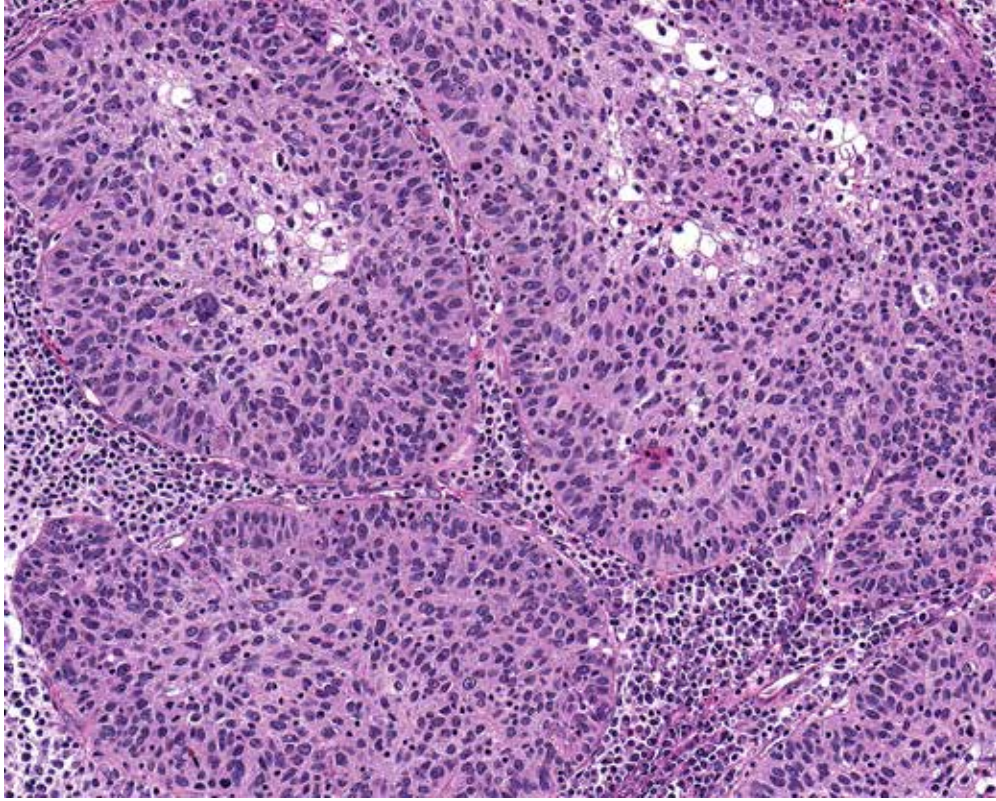
Case 16: 50% of tumor cells exhibit membrane staining. (10x)



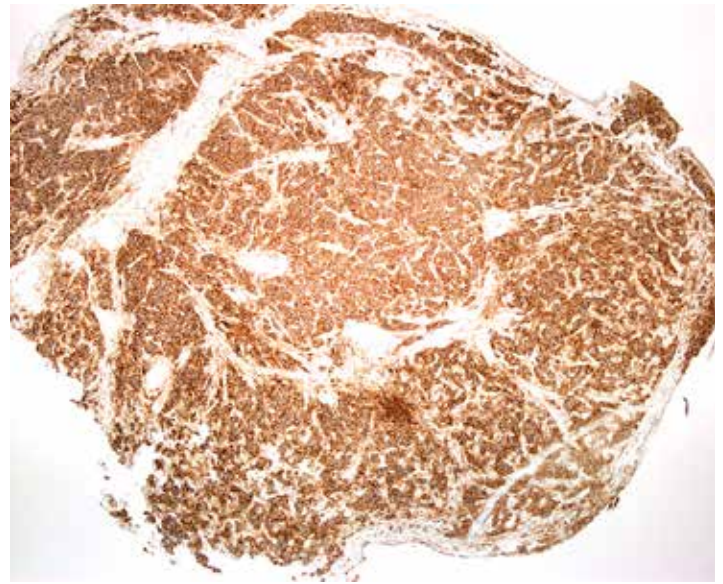
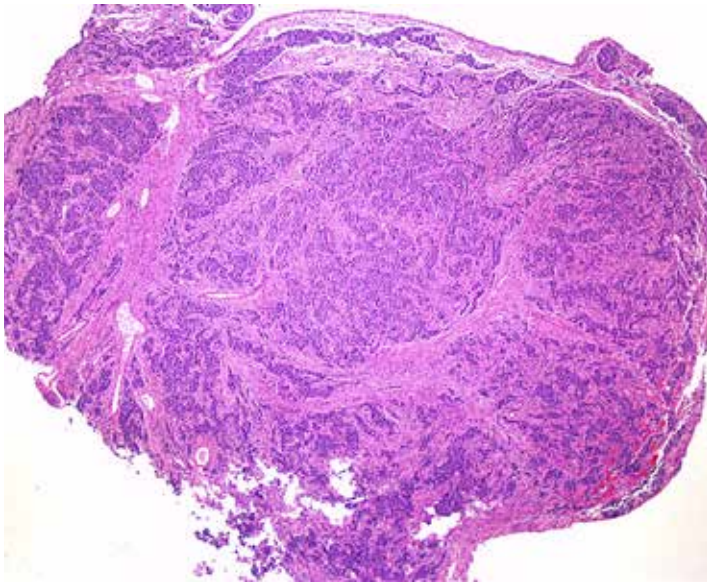
Case 17: 75% of tumor cells exhibit weak to moderate membrane staining. (10x)



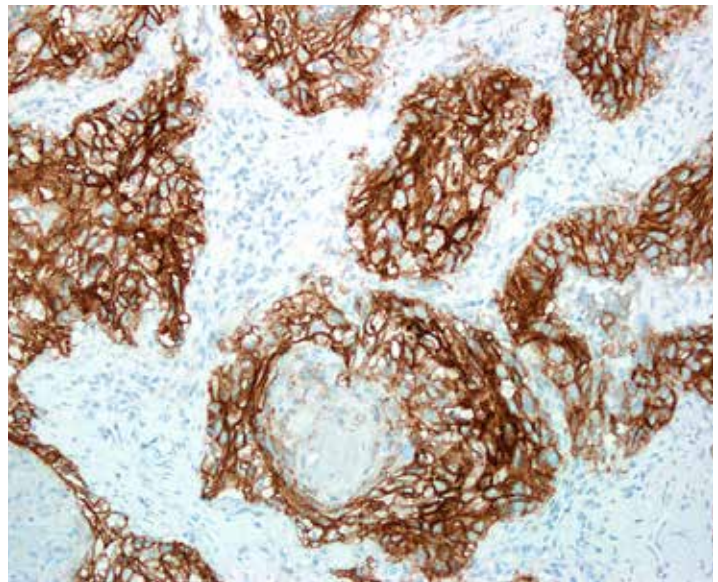
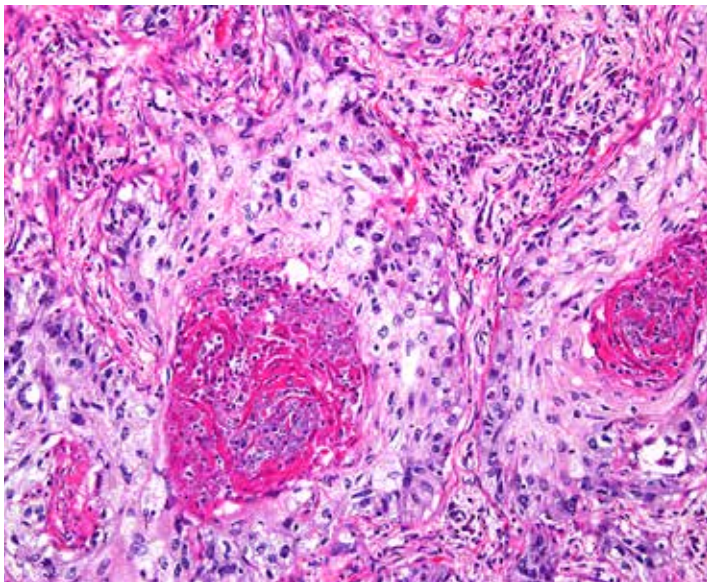
Case 18: 85% of tumor cells exhibit membrane staining. (10x)



Case 19: 100% of tumor cells exhibit membrane strong membrane staining. (10X)



Photoset 20: Tumor cell membrane staining at 100% (4x)



Case 21: Positive tumor cell membrane staining (100%) with no tumor-associated immune cell staining (20x)

Challenging Features

Various staining patterns and morphologic features may make interpretation and quantification of tumor membrane staining difficult. Some cases may be particularly challenging due to the following issues:

- **Weak Cytoplasmic Staining**

Some specimens may exhibit weak tumor cell cytoplasmic staining of the tumor cells that may be confused at low power with weak tumor cell membrane staining. For this reason when evaluating VENTANA PD-L1 (SP263) Assay stained slides, weak staining should be confirmed with examination at higher powers to distinguish between tumor cell membranous and cytoplasmic staining.

- **Strong Immune Cell Staining Overlapping with Tumor Cell Staining**

Some tumors may contain an extensive inflammatory component both surrounding and infiltrating the tumor. In instances when strong staining is seen for both tumor and immune cells it can be challenging to differentiate and quantify the PD-L1 expression level for tumor cells. The presence of immune cells infiltrating the tumor should be confirmed using the H&E slide. The pattern of PD-L1 staining along with cellular nuclear features is utilized to help attribute expression to immune cells (punctate staining) and tumor cells (linear membrane staining).

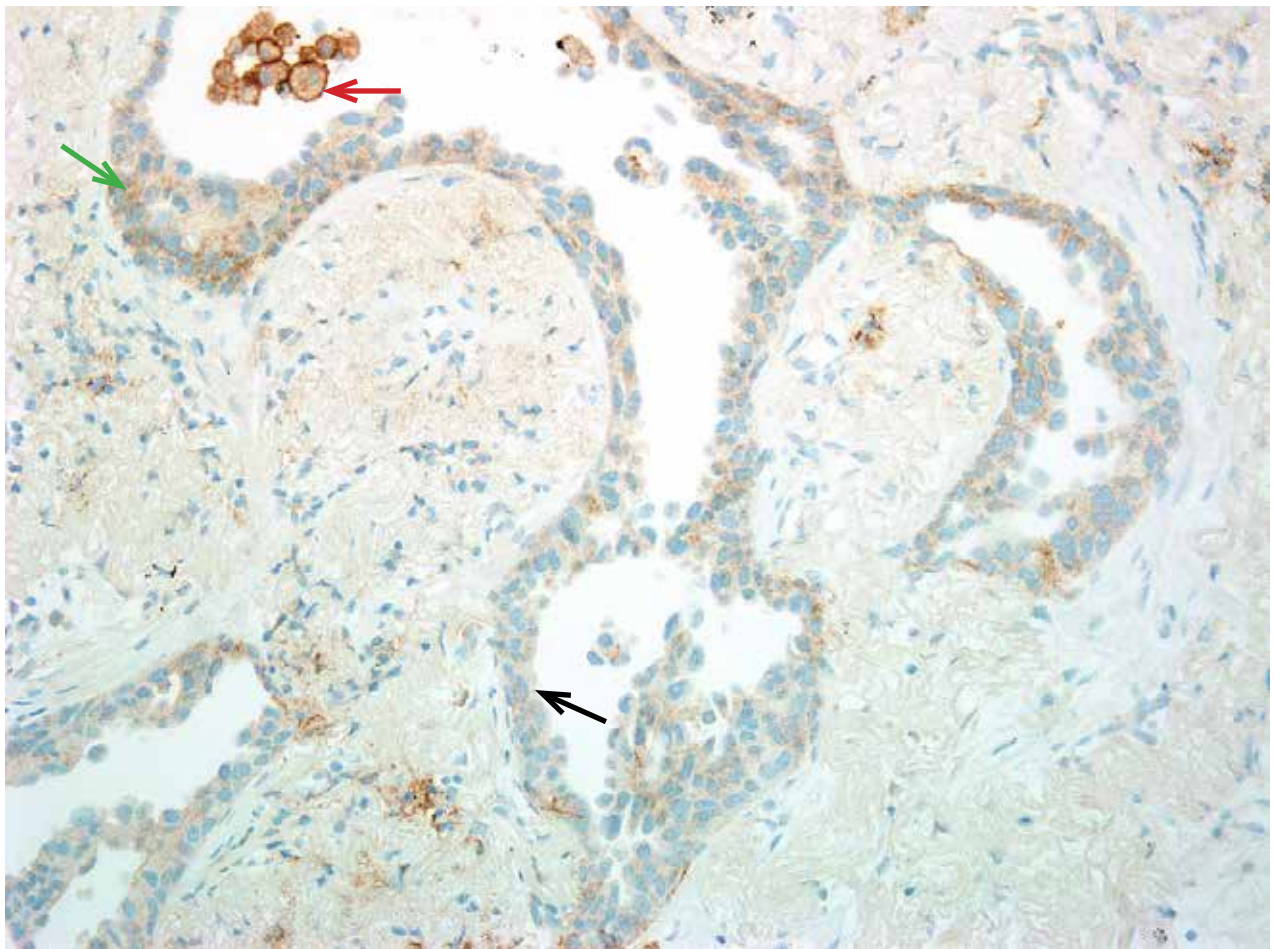
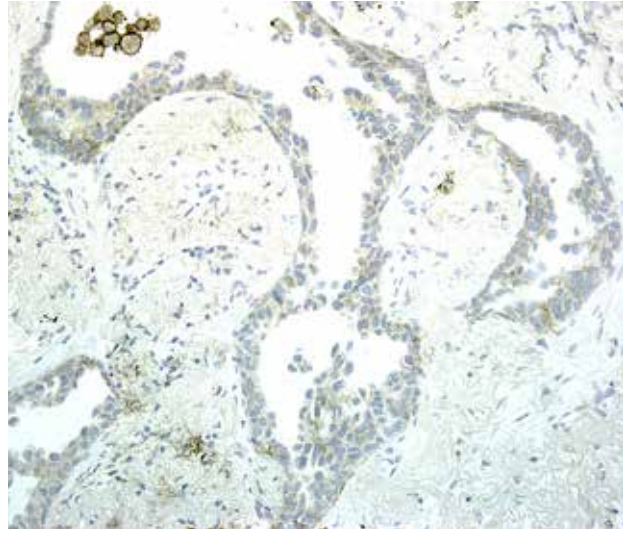
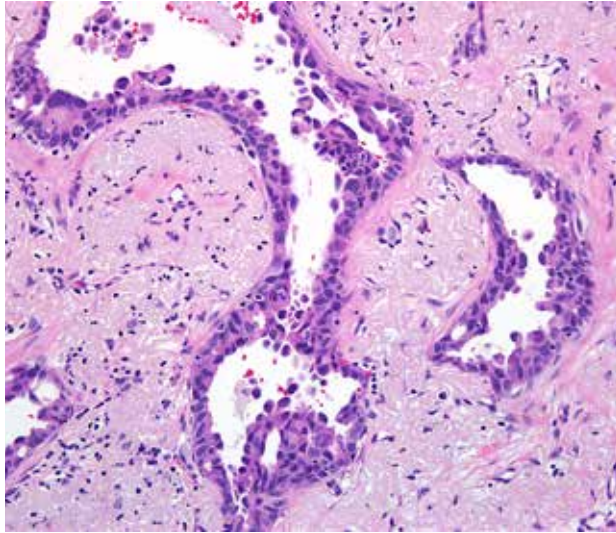
- **Obscuring Endogenous and Exogenous Material**

Occasionally in NSCLC samples endogenous and/or exogenous material, such as anthracotic pigment, melanin pigment or hemosiderin, may obscure and interfere with interpretation of VENTANA PD-L1 (SP263) Assay staining of tumor and immune cells. Comparison of the negative isotype control slide with the PD-L1 stained slide can aid in differentiating between biomarker staining and endogenous or exogenous material. In NSCLC tumors with significant keratin formation, a histiocytic response in the form of foreign body giant cells may be elicited. Such an immune response can mimic tumor cell staining with membrane staining of the giant cells.

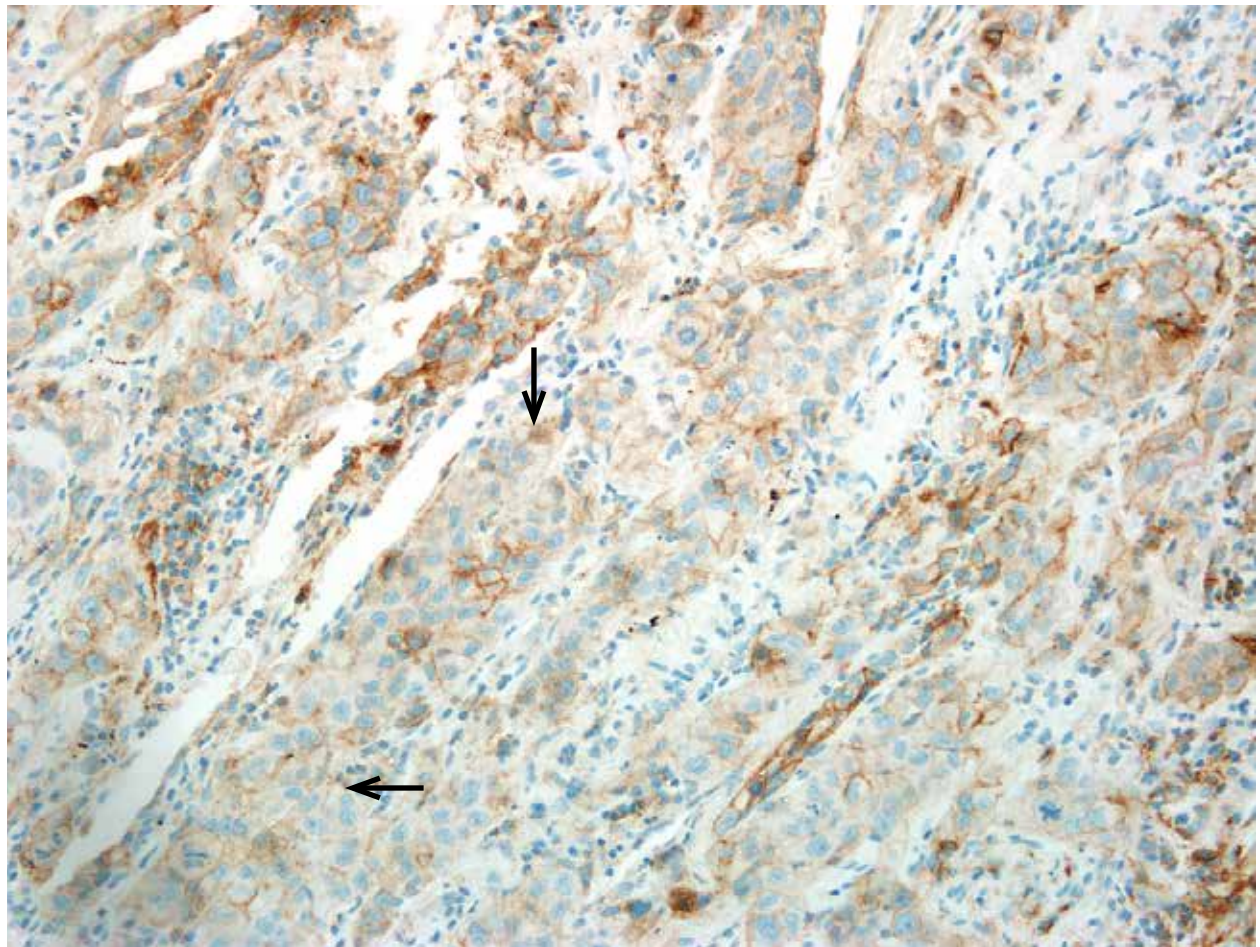
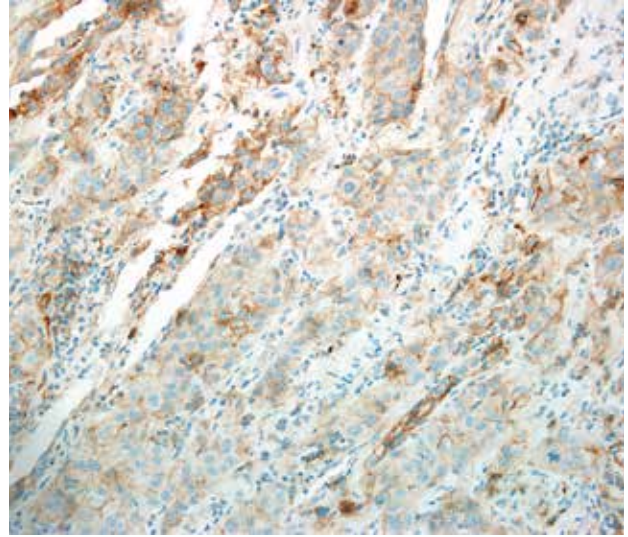
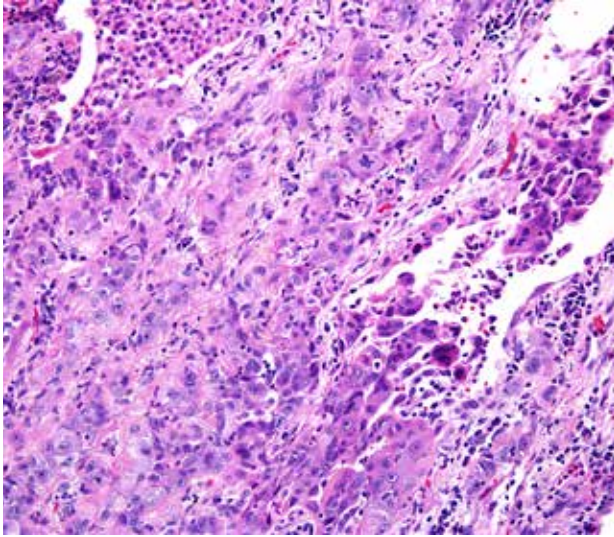
- **Heterogeneity**

When heterogeneous distribution of expression is seen, estimating the total percentage of tumor membrane staining can be challenging. A systematic approach where dividing the tumor into smaller yet equal amounts of viable tumor which are then evaluated for percentage of tumor cells with membrane and averaged can be helpful.

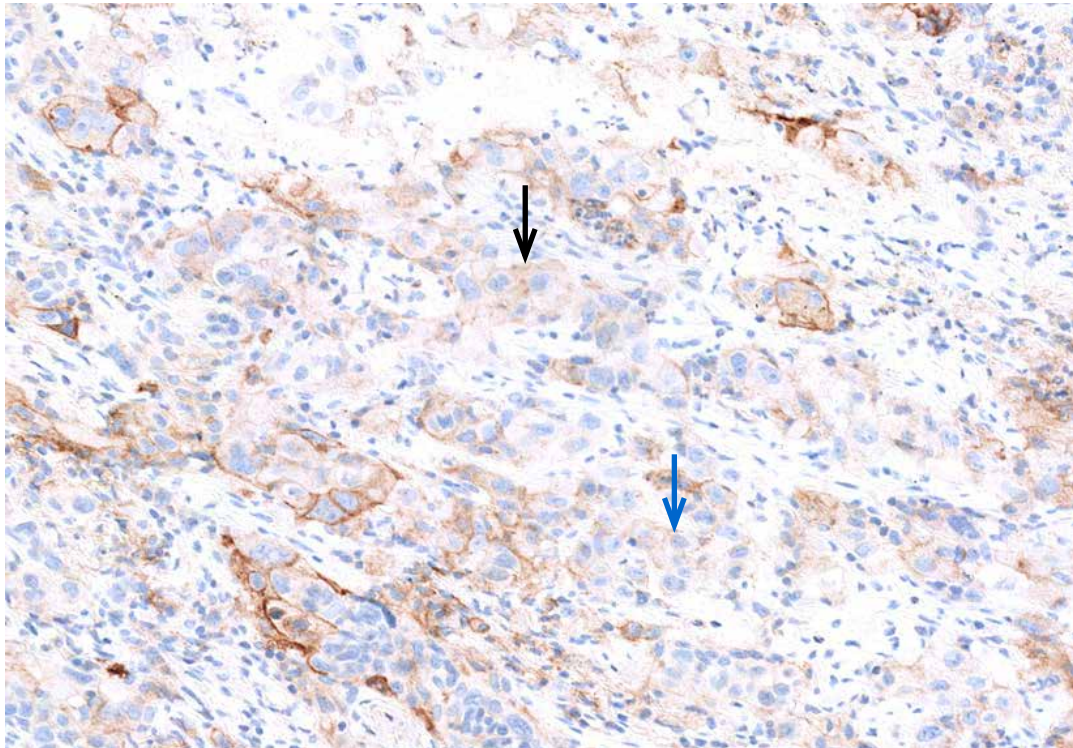
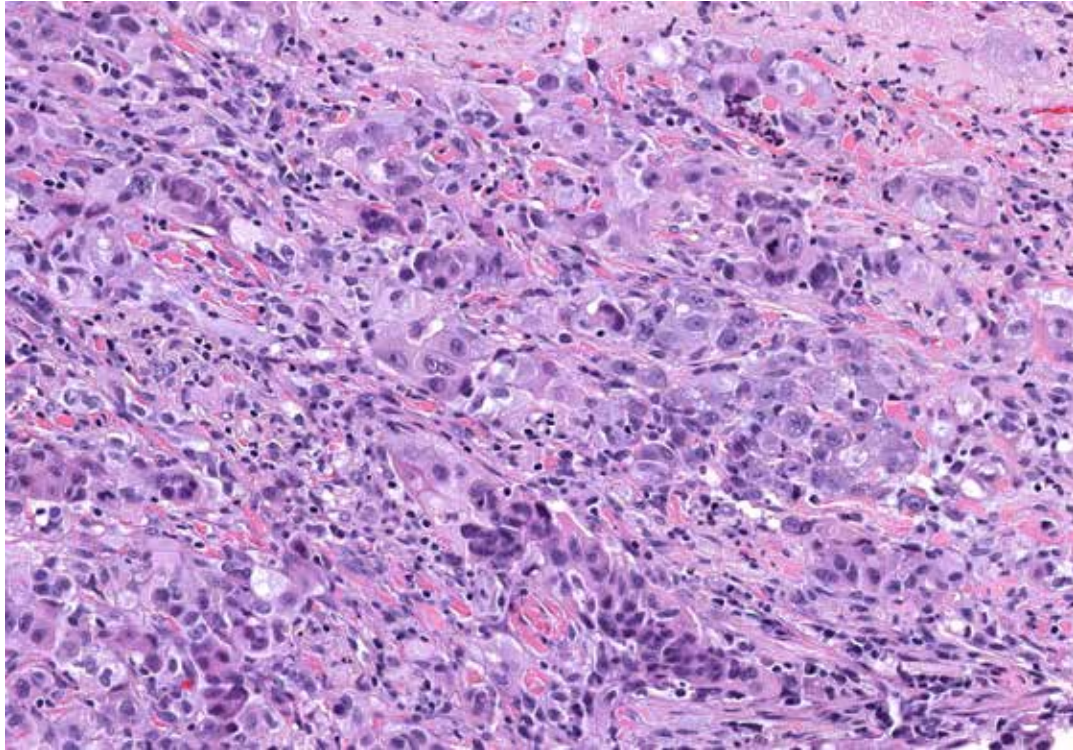
Some examples of challenging cases are shown on the next pages.



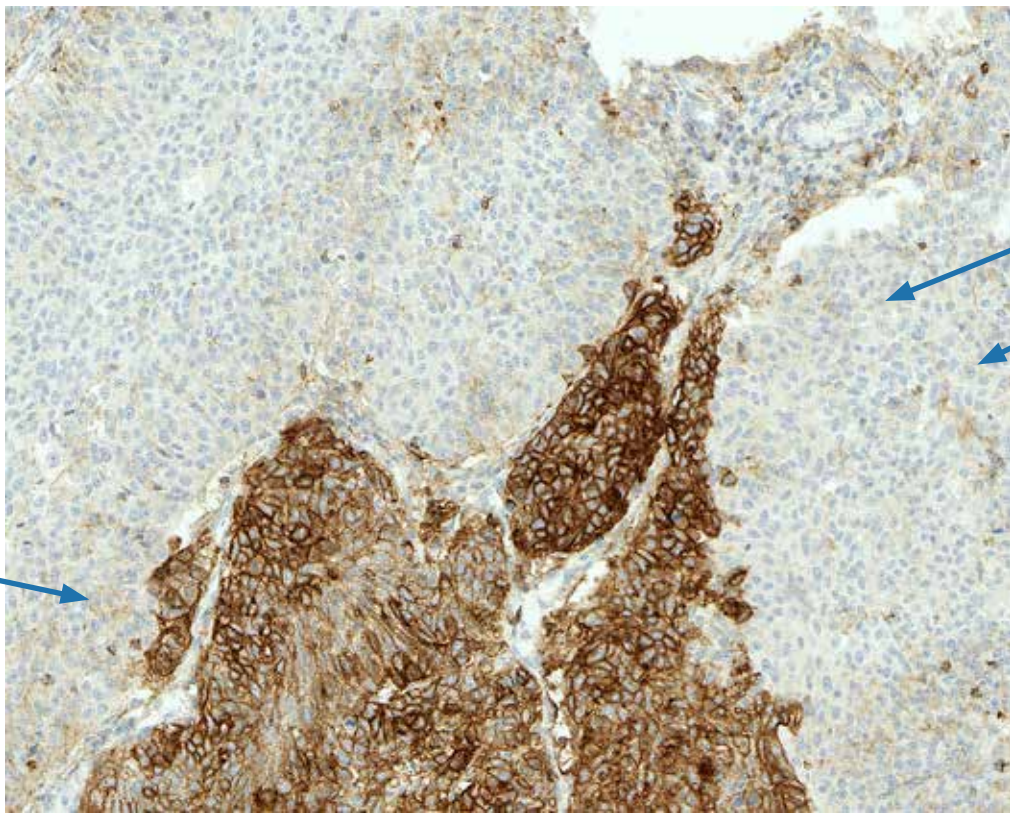
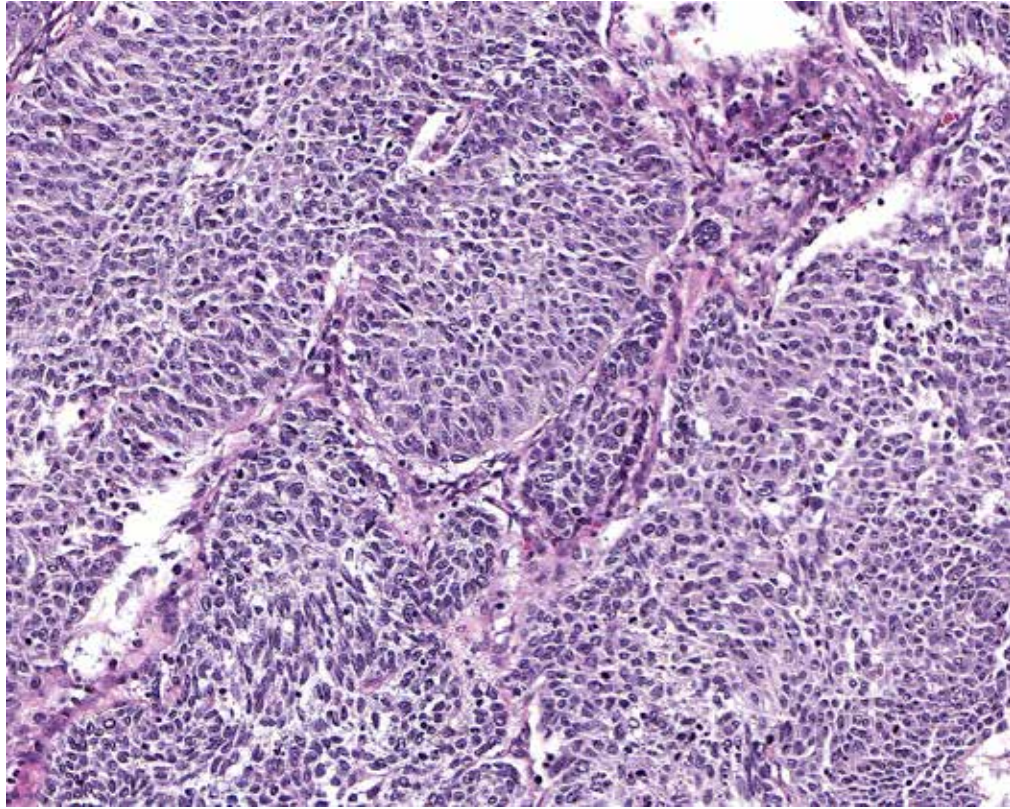
Challenging Case 1: VENTANA PD-L1 (SP263) Assay stained NSCLC case with weak cytoplasmic (black arrow) and weak membrane staining (green arrow) of the tumor cell. Examination at higher power is necessary to differentiate between weak cytoplasmic and membranous staining. Staining of alveolar macrophages is also seen (red arrow). In this field, 10% of tumor cells exhibit membrane staining. (20x)



Challenging Case 2: VENTANA PD-L1 (SP263) Assay stained NSCLC case with weak tumor membrane staining (black arrow). Many tumor cells show an accompanying cytoplasmic blush. In this field, 90% of tumor cells exhibit membrane staining. (20x)



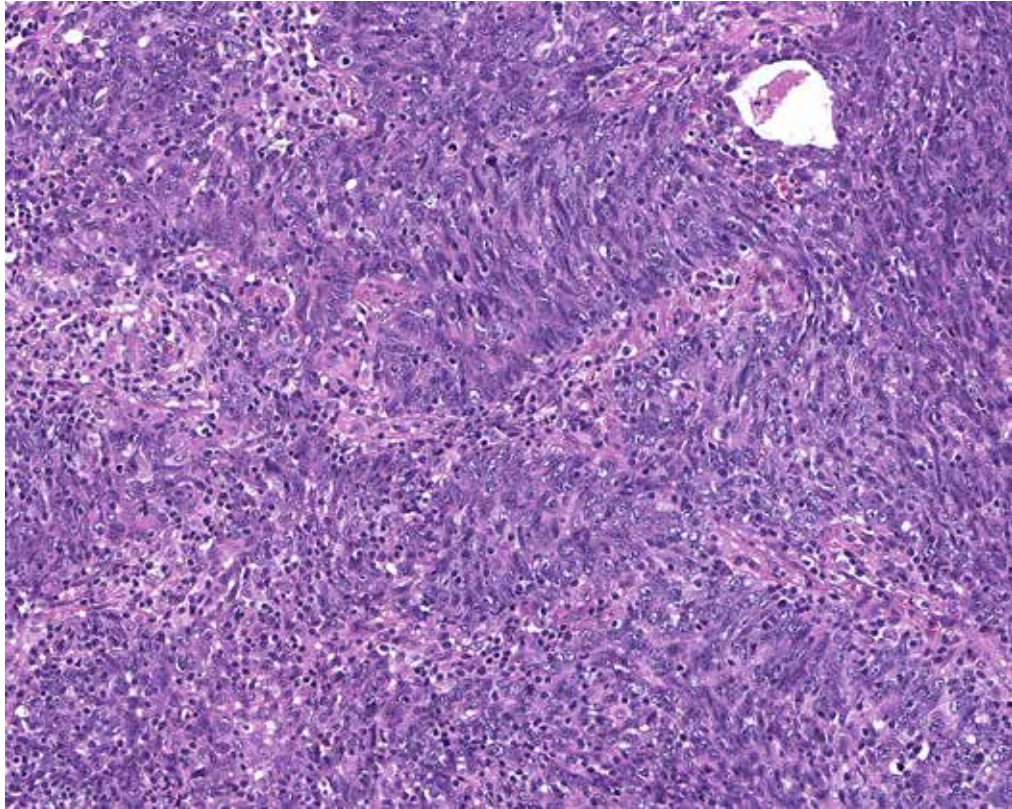
Challenging Case 3: Tumor depicts cells with both weak cytoplasmic and weak membrane staining (black arrow) and only weak membrane staining (blue arrow). In this field, 90% of tumor cells exhibit membrane staining. (20x)



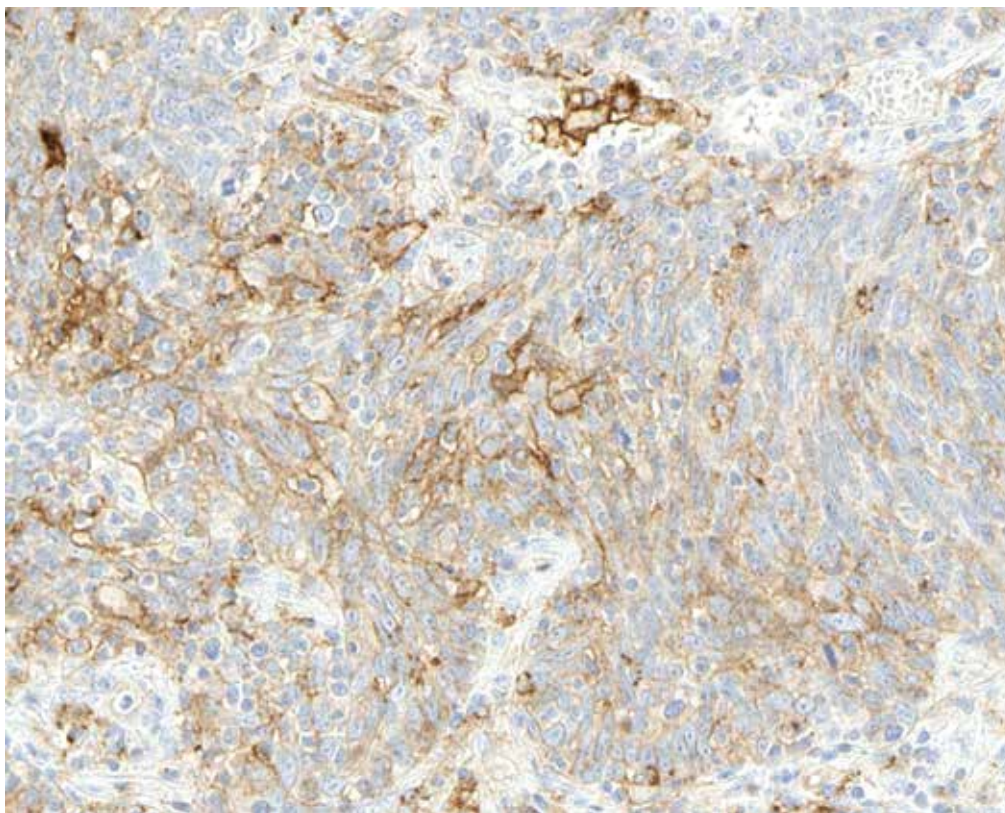
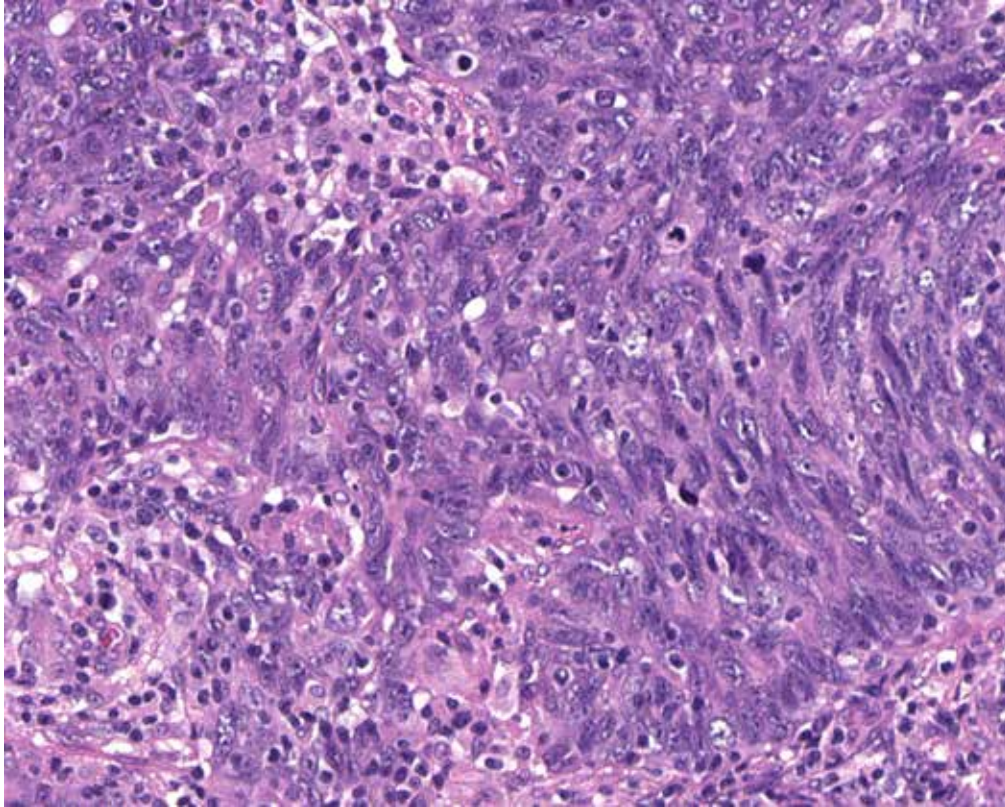
Weak membrane staining

Cytoplasmic blush

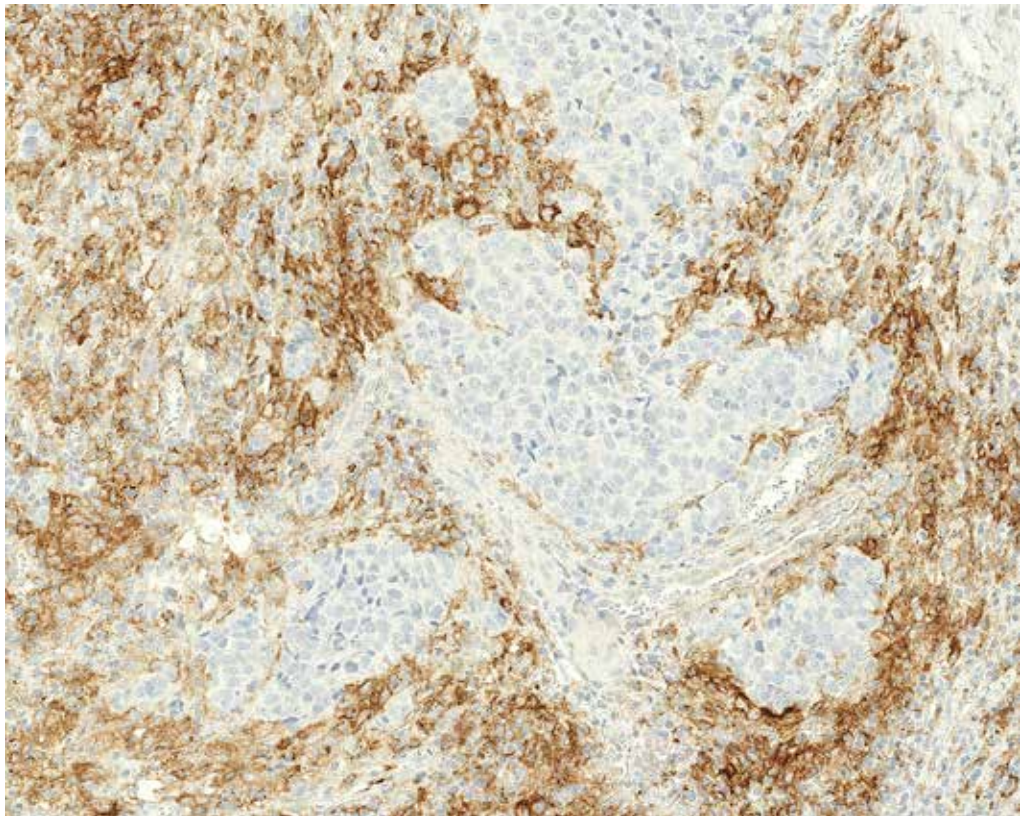
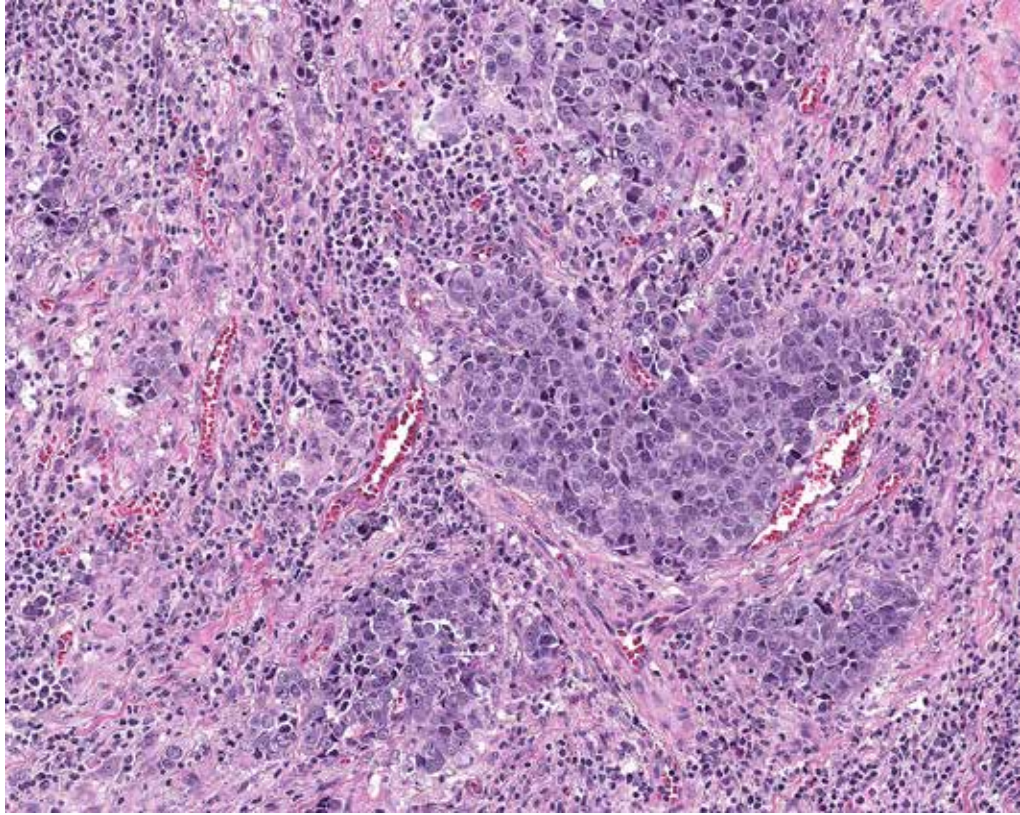
Challenging Case 4: Strong membrane staining is apparent at low power. Ensure that weak membrane staining is not discounted. Especially challenging in the presence of cytoplasmic blush. (10x)



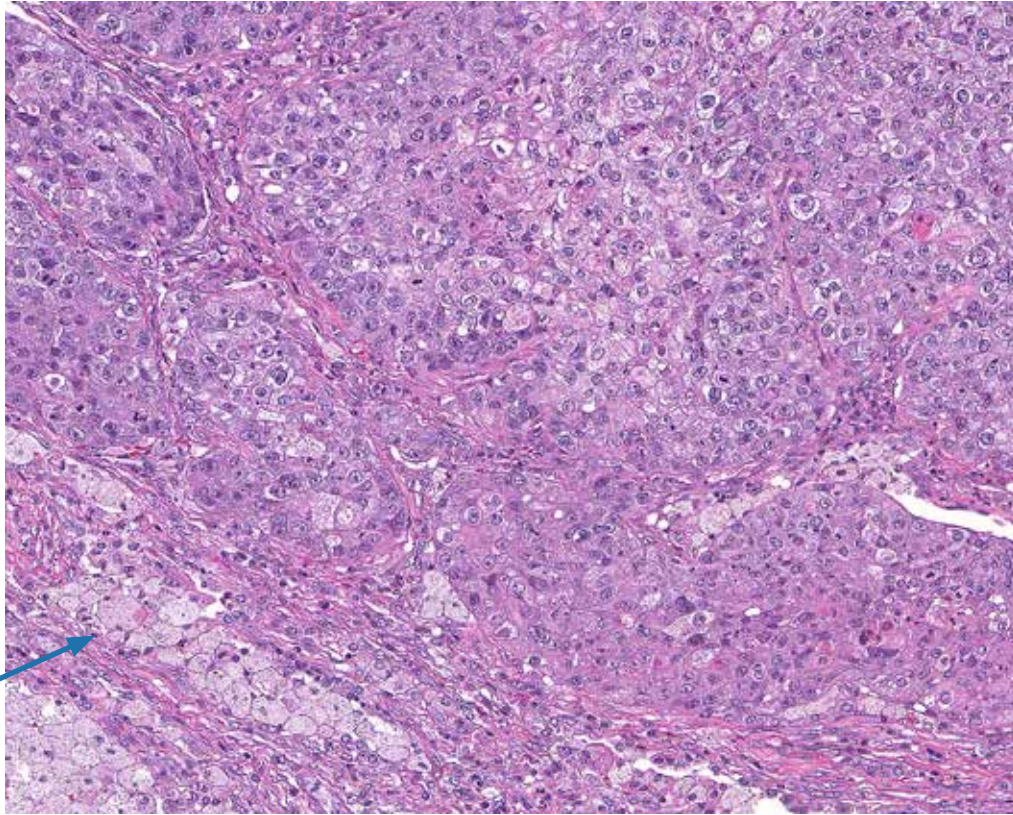
Challenging Case 5: TC and IC staining. It can be challenging determining whether signal is attributable to TC or IC. This example also exhibits cytoplasmic blush in a significant percentage of TC. (10x). (Continued on next page).



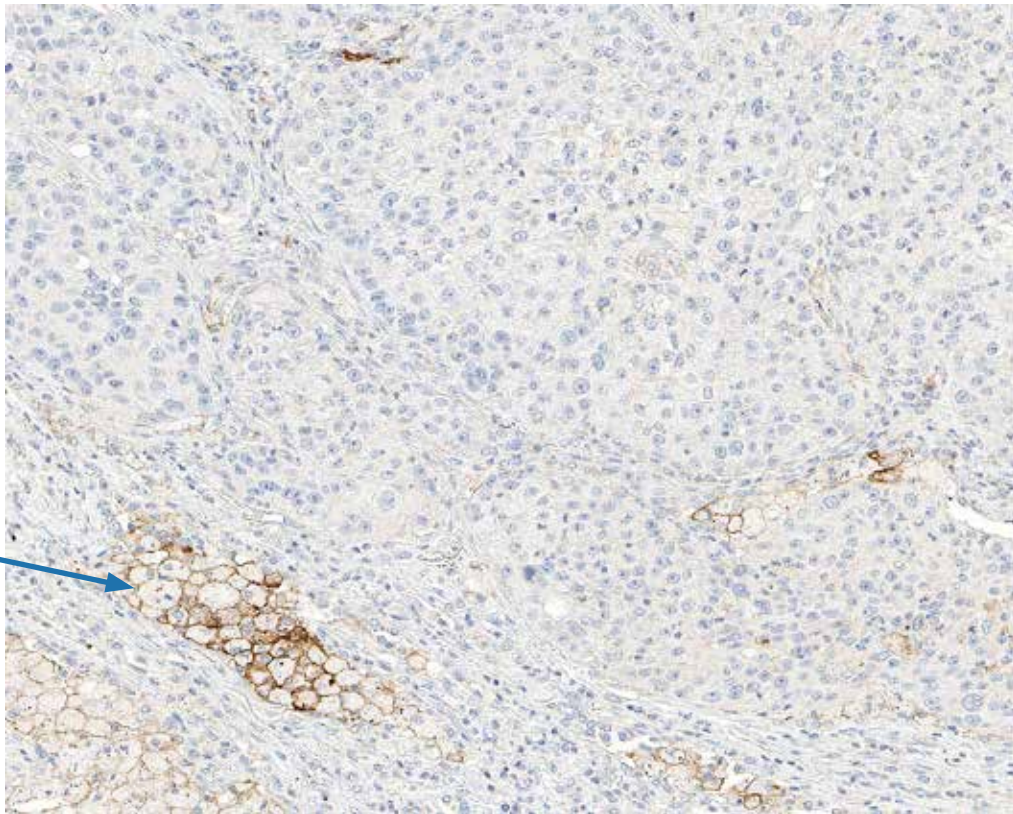
Challenging Case 5 (contd.): Use higher magnification and comparison to H&E to ascertain staining characteristics. This example exhibits TC membrane staining (included in score), TC cytoplasmic staining (not included), and IC staining (not included). (20x)



Challenging Case 6: Predominantly IC staining. IC exhibiting PD-L1 signal do not count towards score estimation. (10x)

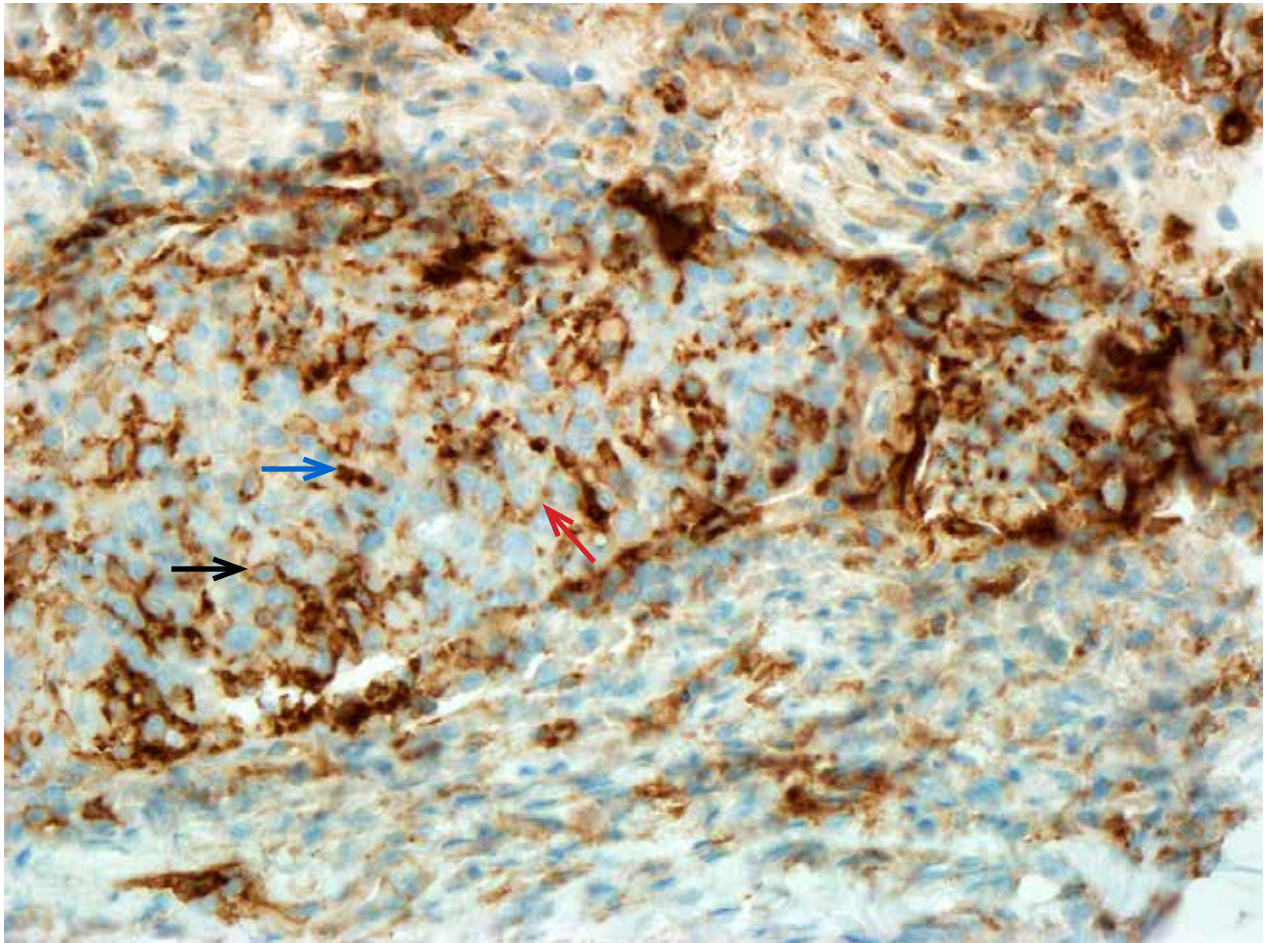
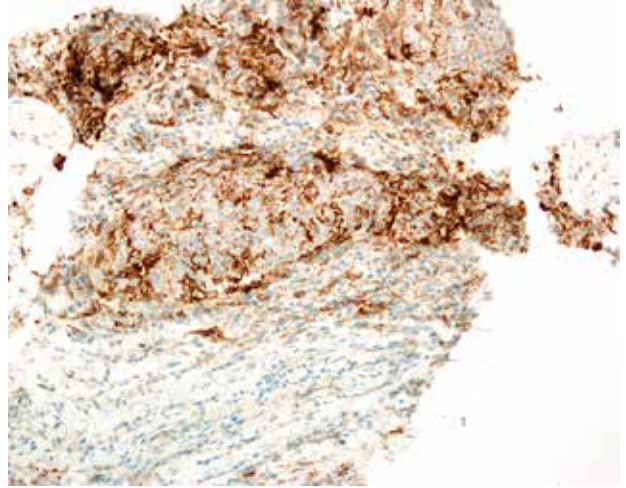
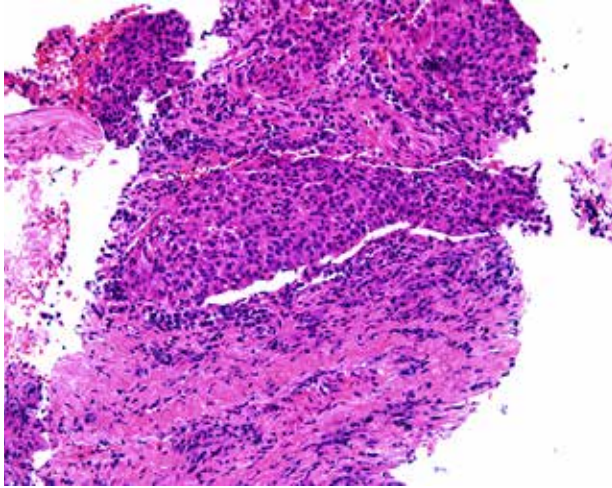


Macrophages with membrane staining

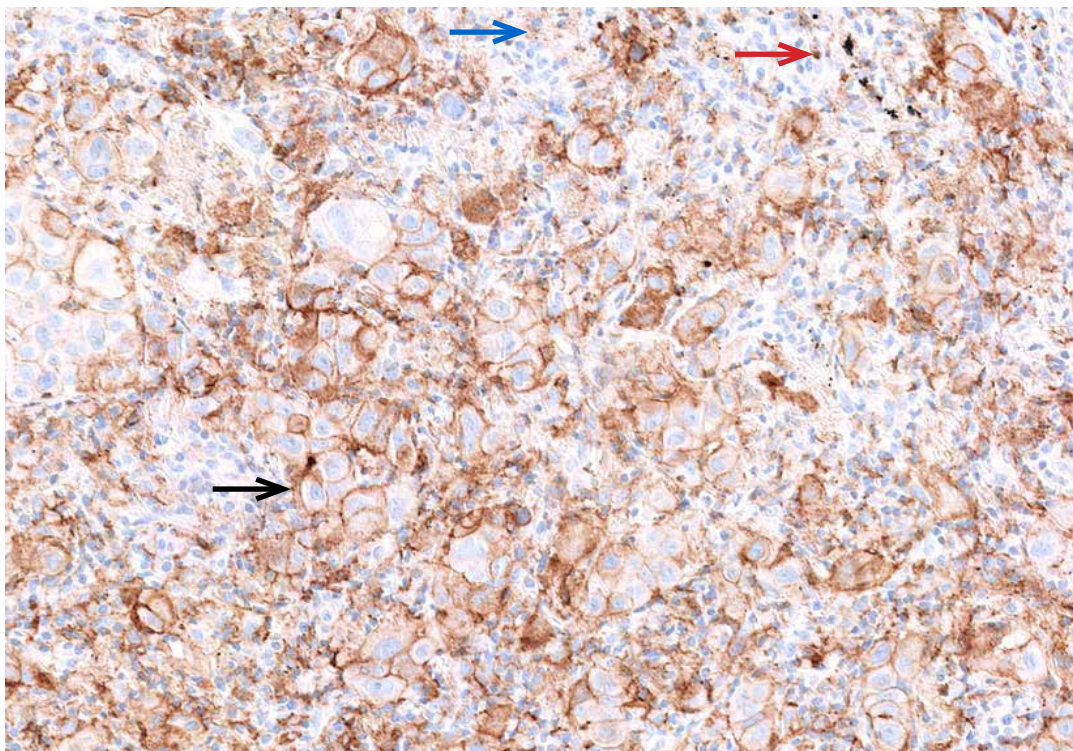
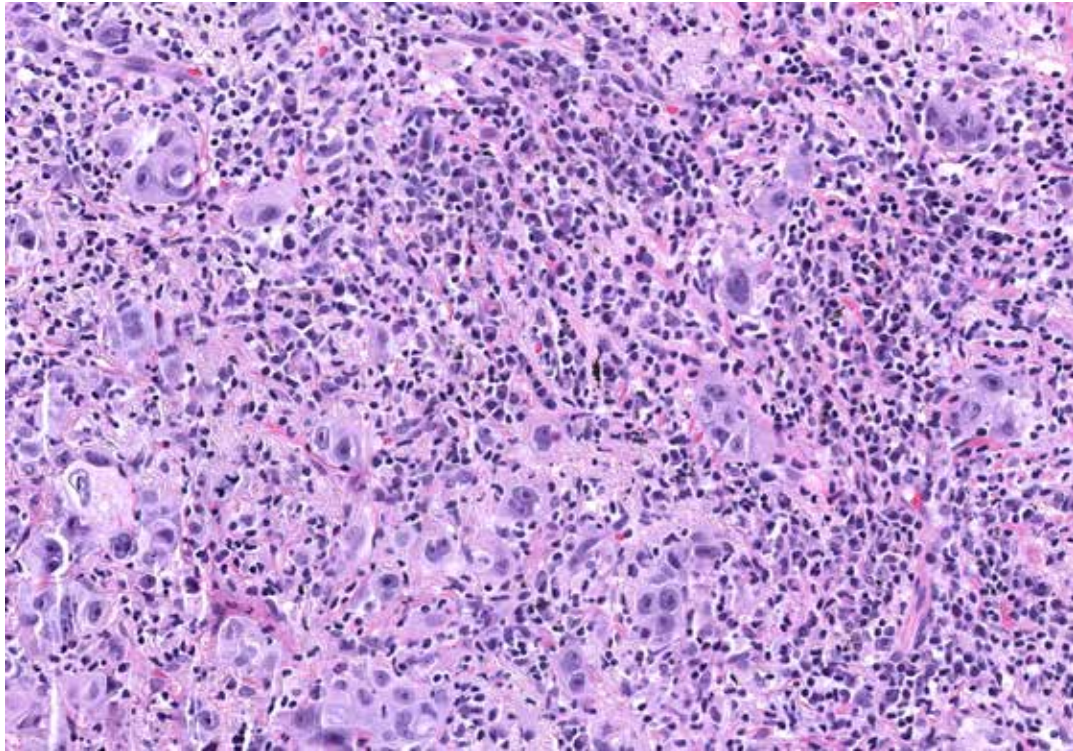


Macrophages with membrane staining

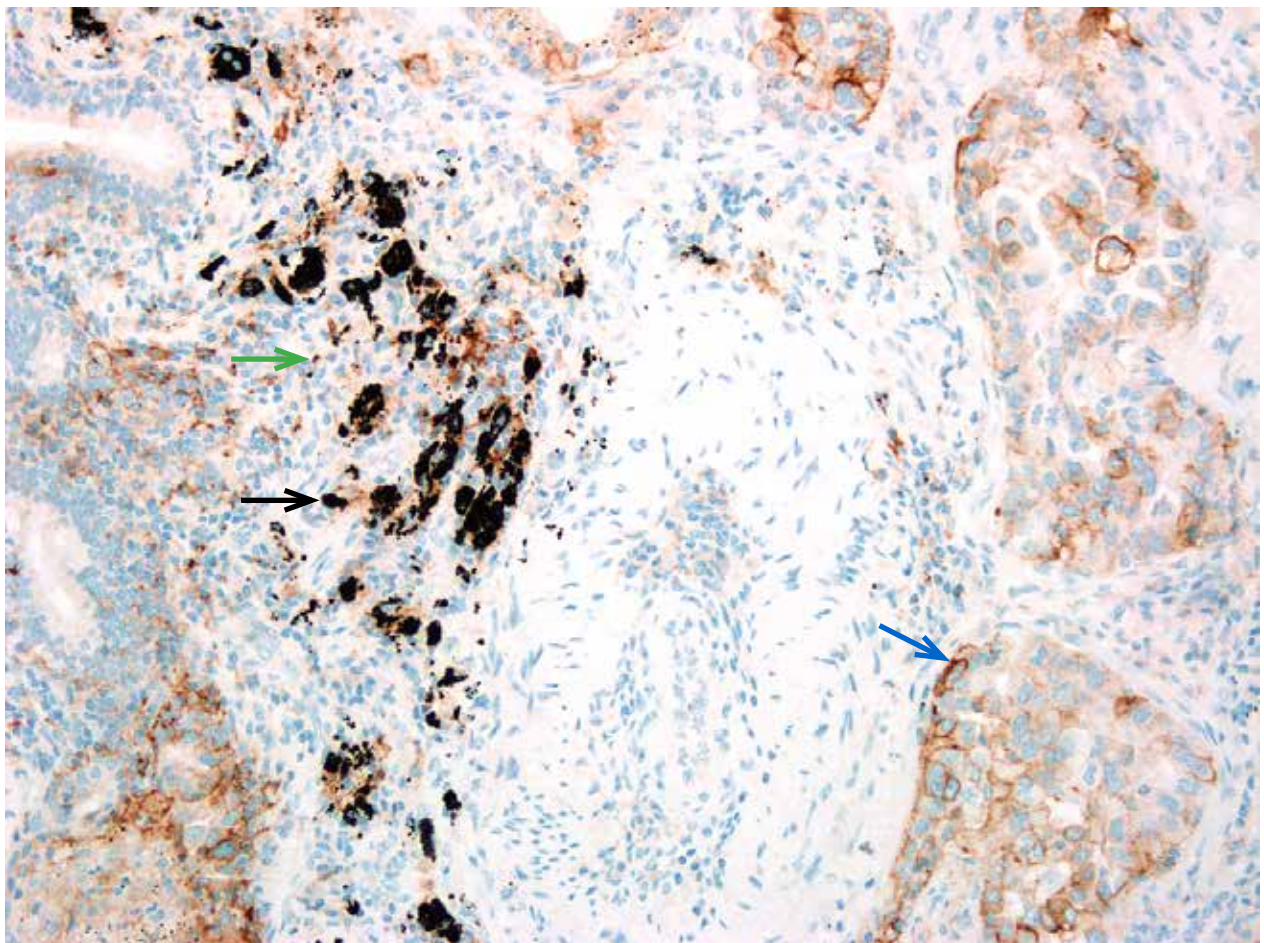
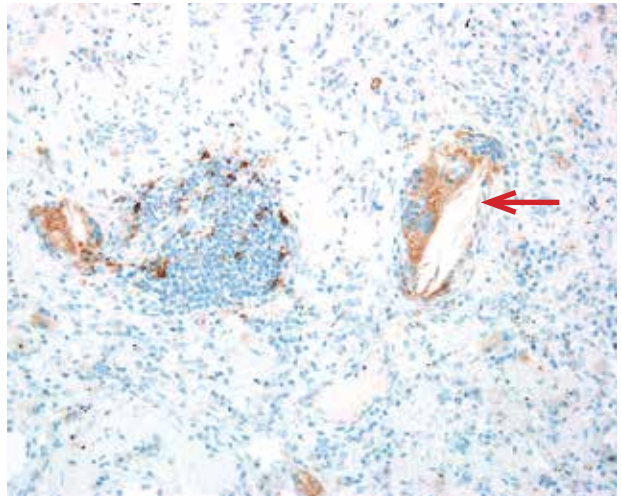
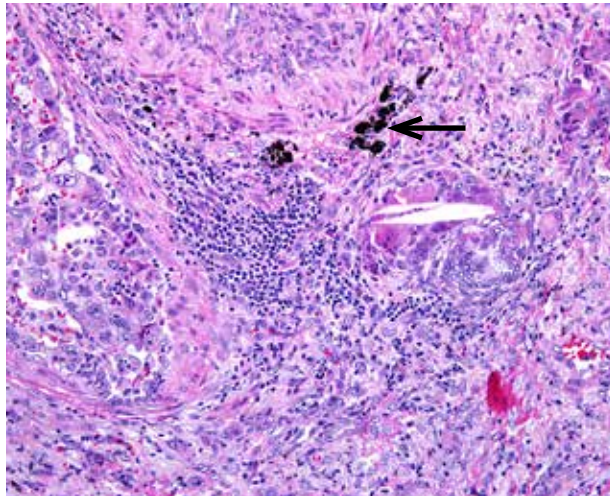
Challenging Case 7: Macrophage staining. Macrophages occasionally exhibit moderate to strong membrane staining that does not count towards score estimation. (10x)



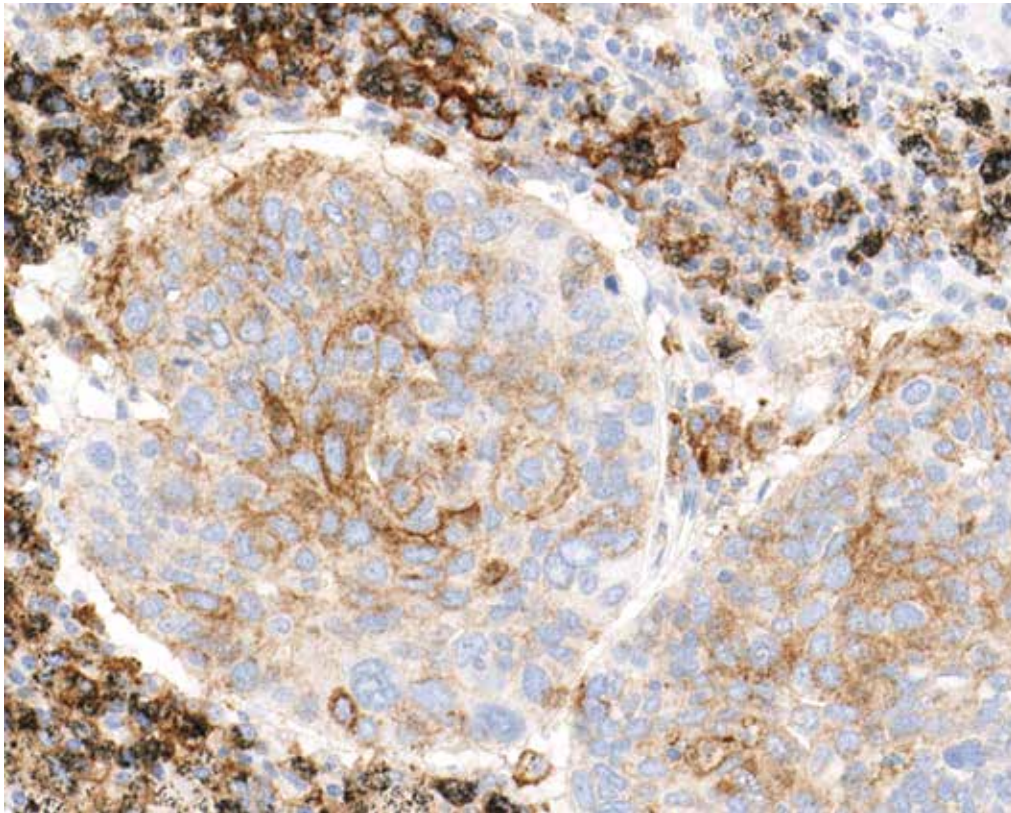
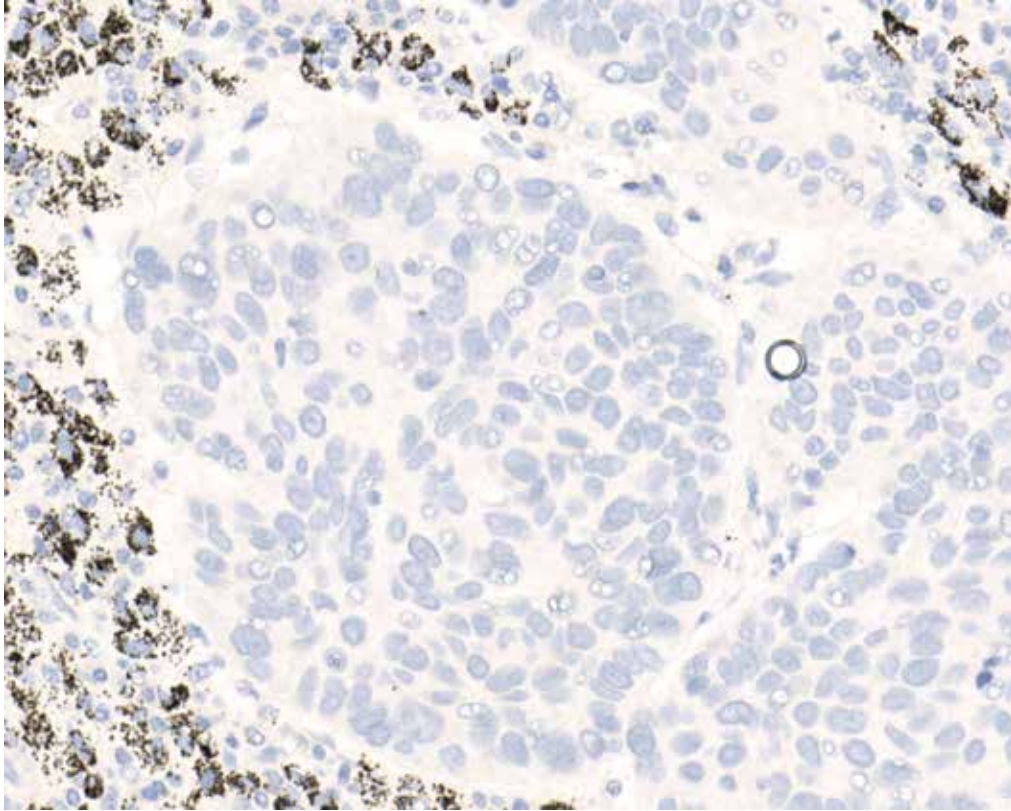
Challenging Case 8: VENTANA PD-L1 (SP263) Assay stained NSCLC case with significant intermixed inflammation. Membranous immune cell staining (black arrow) and punctate immune cell staining (blue arrow) are seen commingled with tumor cells showing partial linear membrane staining (red arrow). In this field, 40% of tumor cells exhibit membrane staining. Heavily inflamed tumor is seen in the H&E. (40x)



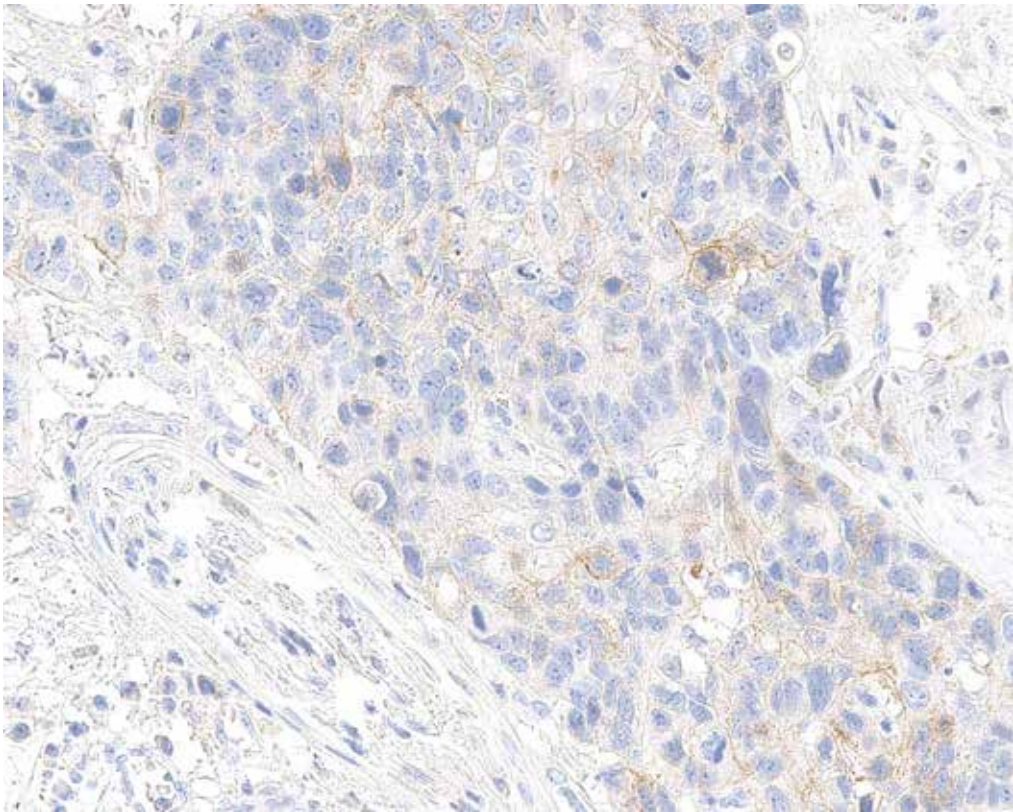
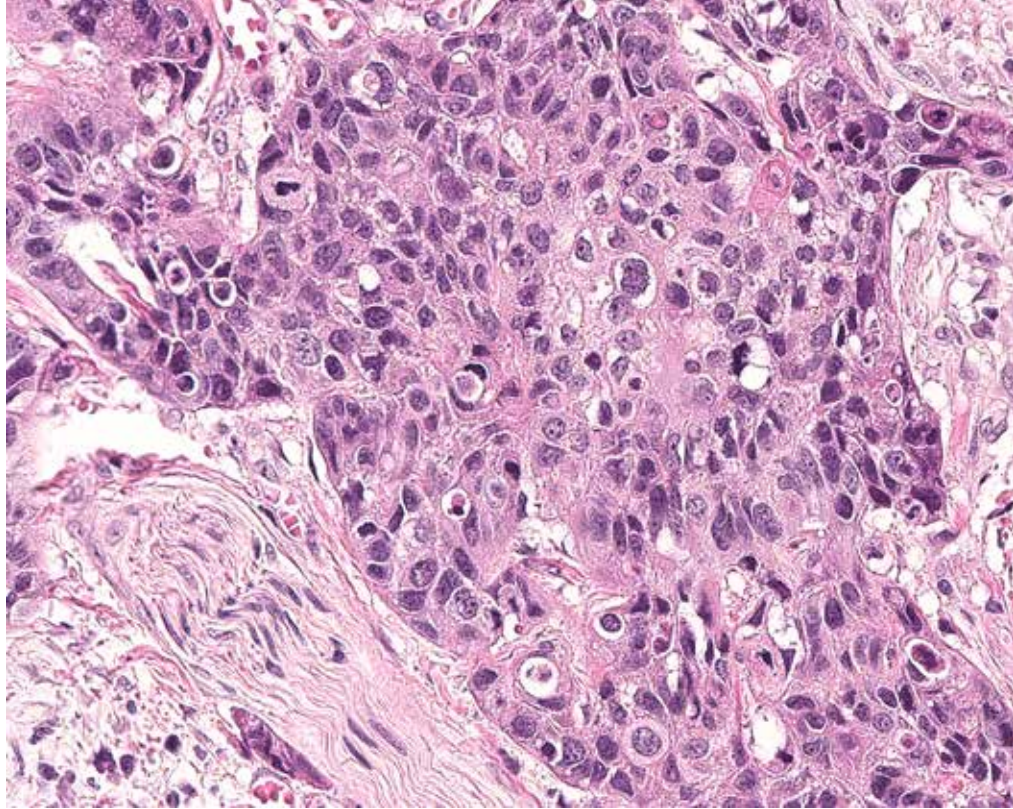
Challenging Case 9: Tumor cell membrane staining (black arrow) intermixed with diffuse (blue arrow) and punctate (red arrow) immune cell staining. In this field, 100% of tumor cells exhibit membrane staining. (20x)



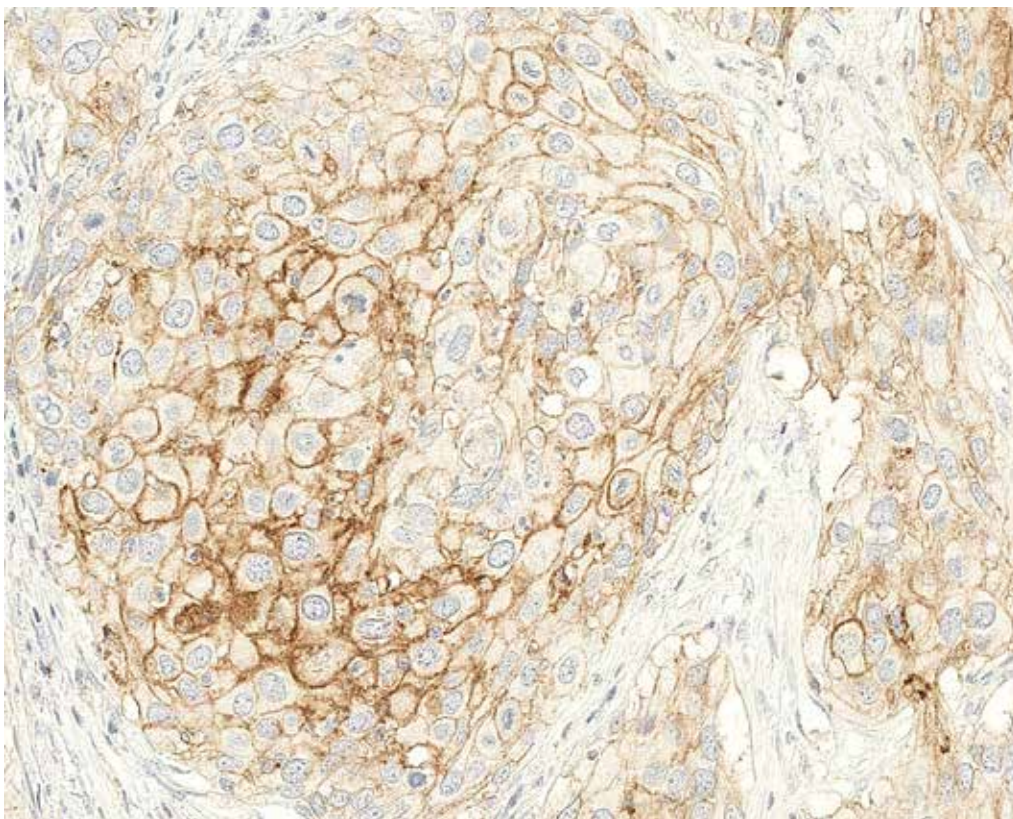
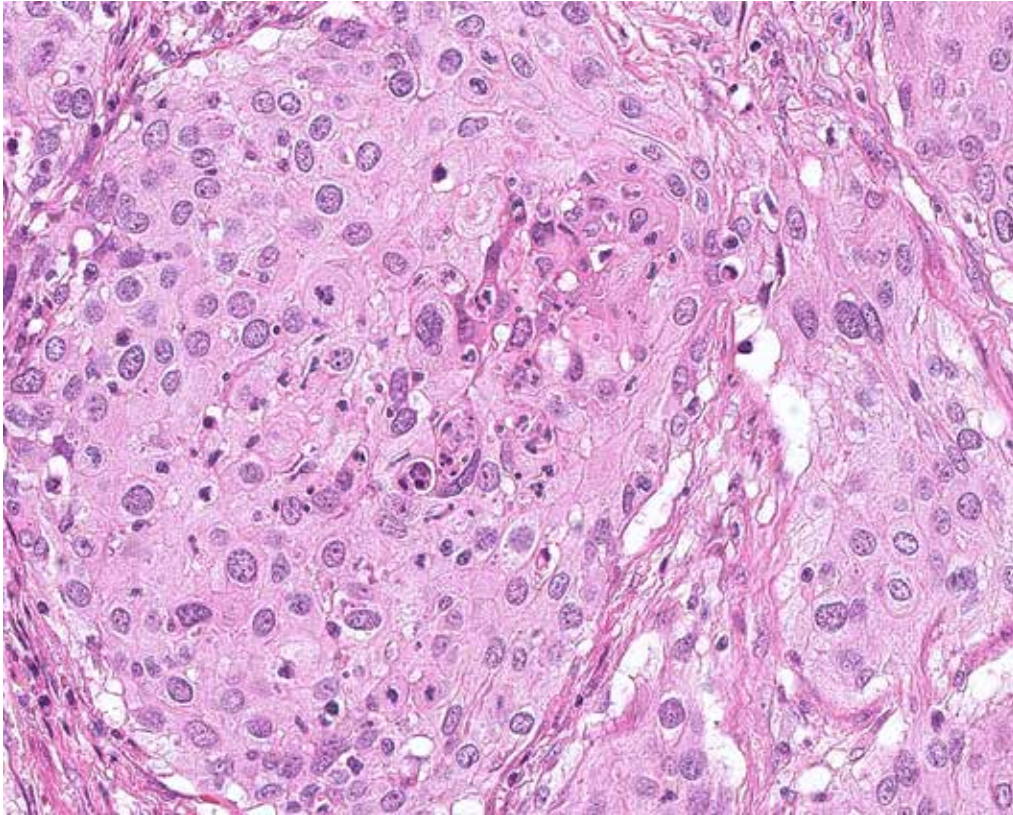
Challenging Case 10: VENTANA PD-L1 (SP263) Assay stained NSCLC case showing anthracosis (black arrow) and foreign body giant cell reaction (red arrow) not associated with case interpretation (top row, 20x). A different area of the case contains anthracotic pigment (black arrow) overlapping with punctate immune cell staining (green arrow) as well as tumor cell membrane staining (bottom, blue arrow). In this field, 80% of tumor cells exhibit membrane staining (bottom). (20x)



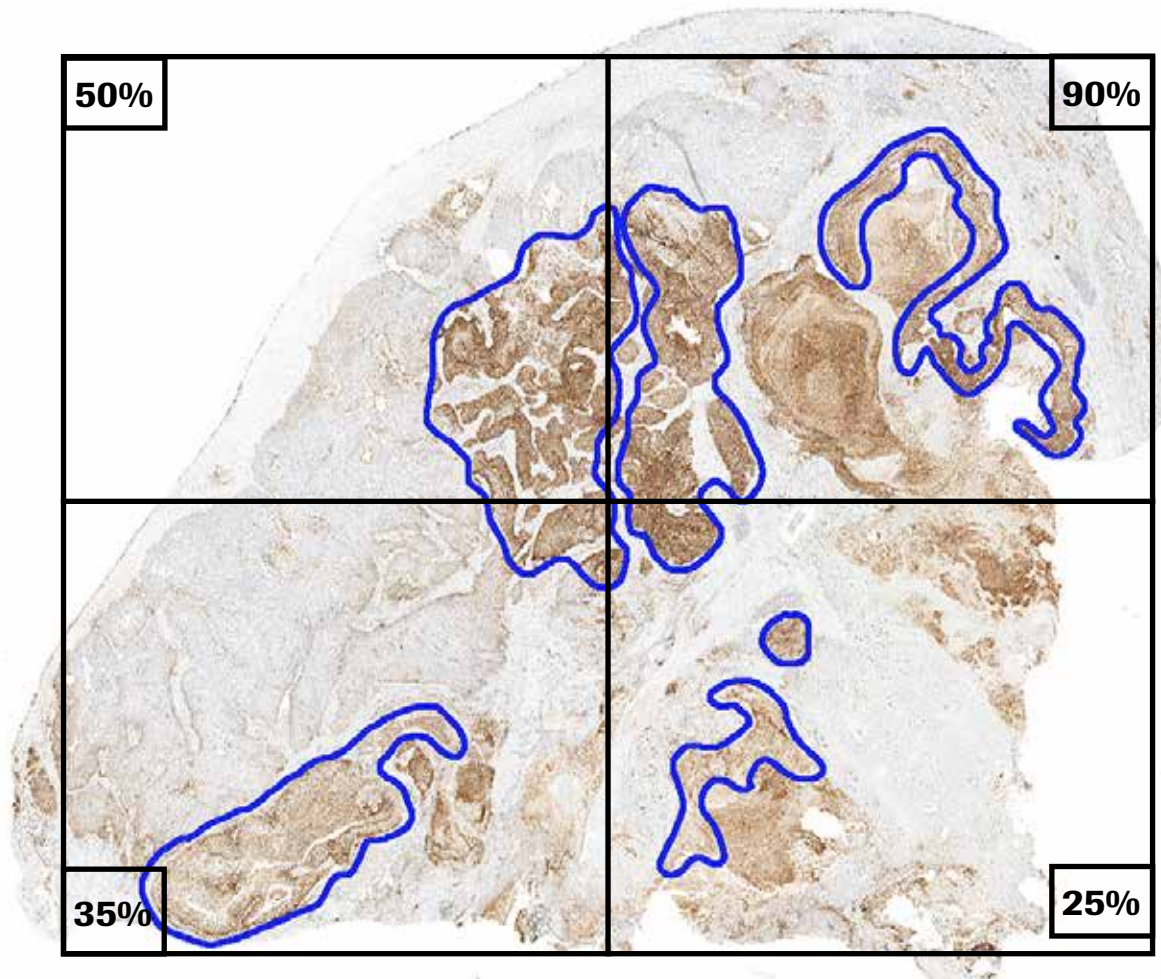
Challenging Case 11: Anthracosis will also be apparent on the NRC (top). Use the NRC to assist in eliminating pigment from score estimation. (20x)



Challenging Case 12: Use higher magnifications to help identify weak TC membrane staining. (20x)



Challenging Case 13: Stronger membrane staining is easily identified at lower magnifications. Use higher power magnifications to ensure that weak TC membrane staining is not overlooked, especially when adjacent to strong membrane staining. (20x)



Challenging Case 14: Tumor cells with membrane staining are distributed heterogeneously throughout this specimen (blue outline). Dividing the entire tumor into smaller sections with equal amounts of viable tumor helps to perform a more accurate estimation. The percentage of tumor cells with membrane staining in each section is estimated and an average of the sections calculated to determine the overall PD-L1 expression level. Any staining in the necrotic areas is disregarded. In this example, the percent of viable tumor cells with membrane expression from each quadrant averaged together results in an overall 50% PD-L1 expression level. A similar technique can be applied when estimating the overall PD-L1 expression level in tumor-associated immune cells with a heterogeneous distribution of staining. (0.6x) Although it may be difficult to appreciate, the total amount of tumor in each quadrant is approximately equal.

Impact of Pre-Analytical Conditions on VENTANA PD-L1 (SP263) Assay Staining

Fixative Recommendations to Achieve Optimal Staining Results with the VENTANA PD-L1 (SP263) Assay

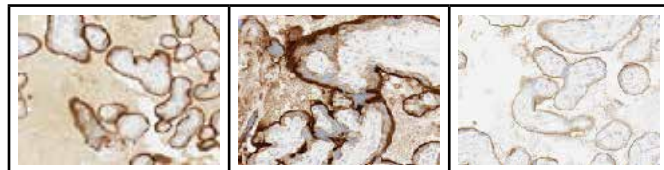
Ventana recommends fixation in 10% NBF for 6-72 hours. Acceptable fixatives and fixation times are outlined in blue.

VENTANA PD-L1 (SP263) Assay Staining of Placenta Tissue Across Fixatives and Fixation Times						
Time Point (Hrs)	Fixative					
	10% NBF	Zinc Formalin	PREFER fixative**	AFA**	Alcoholic Formalin**	95% Ethanol**
1*						
6						
12						
24						
48						
72						

NOTES

*One hour fixation time is not recommended for all fixative types

**Use of PREFER fixative and 95% Ethanol (weaker staining) or alcoholic fixatives (high background) is not recommended. See additional higher magnification images to the right.



Impact of Tissue Thickness on VENTANA PD-L1 (SP263) Assay Staining

Ventana recommends tissue thickness of 4-5 μm for use with the VENTANA PD-L1 (SP263) Assay.

Cut Slide Stability

Sections approximately 4-5 μm in thickness should be cut and mounted on positively charged slides. Slides should be stained as soon as possible after sectioning or dessicated and stored at room temperature for up to 45 days.

References

1. Ferlay J, Soerjomataram I, Ervik M, et al. GLOBOCAN 2012 v1.0. Cancer Incidence and Mortality Worldwide: IARC CancerBase No. 11. <http://globocan.iarc.fr>. Published 2013-12-12. Updated 2014-01-09. Accessed 2016-02-08.
2. Siegel R, Naishadham D, Jemal A. Cancer Statistics, 2013. *CA Cancer J Clin*. 2013;63(1):11-30.
3. Howlader N, Noone AM, Krapcho M, et al. (eds). SEER Cancer Statistics Review (CSR), 1975-2012. National Cancer Institute. http://seer.cancer.gov/csr/1975_2012/. Published 2015-04-23. Updated 2015-11-18. Accessed 2016-02-08.
4. Keir ME, Butte MJ, Freeman GJ, et al. PD-1 and its ligands in tolerance and immunity. *Annu Rev Immunol* 2008;26:677-704.
5. Blank C, Mackensen A. Contribution of the PD-L1/PD-1 pathway to T-cell exhaustion: an update on implications for chronic infections and tumor evasion. *Cancer Immunol Immunother*. 2007;56(5):739-745.
6. Butte MJ, Keir ME, Phamduy TB, et al. Programmed death-1 ligand 1 interacts specifically with the B7-1 costimulatory molecule to inhibit T-cell responses. *Immunity*. 2007;27(1):111-122.
7. Dong H, Zhu G, Tamada K, et al. B7-H1, a third member of the B7 family, co-stimulates T-cell proliferation and interleukin-10 secretion. *Nat Med*. 1999;5(12):1365-1369.
8. Massard C, Gordon MS, Sharma S, et al. Safety and efficacy of durvalumab (MEDI4736), an anti-programmed cell death ligand-1 immune checkpoint inhibitor, in patients with advanced urothelial bladder cancer. *J Clin Oncol*. 2016;34(26):3119-3126.
9. Patel SP, Kurzrock R. PD-L1 expression as a predictive biomarker in cancer immunotherapy. *Mol Cancer Ther*. 2015;14(4) 847-856.



Ventana Medical Systems, Inc.
1910 E. Innovation Park Drive
Tucson, Arizona 85755
USA
+1 520 887 2155
+1 800 227 2155 (USA)



dialog.roche.com

© 2021 Ventana Medical Systems, Inc.
All rights reserved.

VENTANA, BENCHMARK, OPTIVIEW and the VENTANA logo are trademarks
of Roche. All other trademarks are the property of their respective owners.

1020383US Rev 1
2021-05-07

IVD

