

FDA Executive Summary

Prepared for the
July 10-11, 2014 meeting of the
Obstetrics and Gynecology Devices Advisory Committee

Laparoscopic Power Morcellation during Uterine Surgery for Fibroids

Table of Contents

1	Introduction and Purpose of the Advisory Committee Meeting.....	4
2	Fibroids and Uterine Sarcoma	5
2.1	Background on Uterine Fibroids ¹⁻⁶	5
2.2	Uterine Sarcoma.....	6
2.3	Diagnostic Considerations for Uterine Fibroids and Sarcomas	7
3	Treatment Options for Uterine Fibroids	7
3.1	Surgical Options for Fibroids.....	7
3.2	Non-Surgical Treatment Options for Fibroids	11
3.2.1	Expectant Management ^{4,44, 184}	11
3.2.2	Pharmaceutical Therapy.....	11
3.2.3	Magnetic Resonance Guided Focused Ultrasound (MRgFUS) ¹¹²⁻¹²⁶	12
3.2.4	Uterine Artery Embolization ¹³⁴⁻¹⁵⁷	12
3.2.5	Radiofrequency Volumetric Thermal Ablation	13
3.2.6	Endometrial Ablation.....	14
4	Laparoscopic Power Morcellators	14
4.1	Pre-market Testing of LPMs.....	15
4.2	Benefits of LPMs	16
4.3	Complications and Risks of LPMs.....	17
4.3.1	Injuries to Local Organs/Tissue	17
4.3.2	Dissemination of Benign Tissue	17
4.3.3	Disruption of Malignant Tissue Pathologic Architecture	18
4.3.4	Dissemination of Malignant Tissue	18
4.4	Potential Risk Mitigation Measures for Dissemination of Malignant Tissue During Morcellation.....	27
4.4.1	Device Design.....	27
4.4.2	Laparoscopic Specimen Bags	27
4.4.3	Surgical Technique	30
4.4.4	Labeling/Training.....	33
5	Conclusion.....	34

6	Appendicies	35
	Appendix A: April 2014 FDA Safety Communication.....	35
	Appendix B: Overview of Uterine Sarcomas.....	36
	Appendix C: Diagnostic Considerations for Uterine Fibroids and Sarcomas.....	39
	Appendix D: Comparative Surgical Outcomes as A Function of Hysterectomy Technique ¹⁷	44
	Appendix E: Labeling for Uterine Laparoscopic Power Morcellators	46
7	LITERATURE REFERENCES.....	49

1 Introduction and Purpose of the Advisory Committee Meeting

Laparoscopic power morcellators (LPMs), including those for gynecologic surgeries, are used to fragment tissue to allow surgical specimens to be removed through small incisions during minimally invasive surgeries (MIS), including hysterectomies and myomectomies.

As the number of minimally invasive surgeries has increased in the last 20 years, additional information has become available regarding LPMs. Recent discussions within the patient and clinical communities as well as the peer-reviewed literature have raised awareness of the risk of spreading unsuspected cancerous tissue beyond the uterus when LPMs are used during surgeries intended to treat benign fibroids. This iatrogenic dissemination of malignant tissue may result in the “upstaging” of a tumor, thereby worsening a patient’s prognosis and likelihood for long-term survival.

Based on an analysis of currently available data, the FDA has estimated that approximately 1 in 350 women who undergo hysterectomy or myomectomy for presumed fibroids have an unsuspected and difficult to diagnose type of uterine cancer called uterine sarcoma. This rate, which is higher than previously quoted in some of the literature, led FDA to issue a Safety Communication on April 17, 2014 discouraging the use of LPMs in treating symptomatic uterine fibroids. The Communication is provided at: <http://www.fda.gov/MedicalDevices/Safety/AlertsandNotices/ucm393576.htm> and is also available in Appendix A of this document. In April, FDA also issued requests to manufacturers of LPM’s indicated for gynecologic procedures to review their product labeling to ensure that it contains accurate safety information.

FDA believes that, in keeping with its public health mission, it is appropriate to have an open and transparent dialogue among FDA, manufacturers, health care providers, researchers, patients, and the public to review and discuss available data regarding the benefits and risks associated with the use of LPMs during gynecologic surgeries and generate scientifically-based recommendations on how to best communicate and, if possible, mitigate those risks. As such, FDA’s Obstetrics and Gynecology Devices Advisory Committee is being convened to discuss: (1) the benefits, risks, and clinical role of LPMs in the treatment of uterine fibroids, (2) whether surgical techniques and/or use of accessories, such as specimen bags, can enhance the safe and effective use of these devices, and (3) whether specific labeling related to the risk of cancer spread should be required for LPMs.

FDA has cleared several electromechanical *hysteroscopic* morcellators (used within the cavity of the uterus) for intrauterine procedures including the removal of submucosal fibroids. However, these devices are not included in our discussion as FDA’s analysis was focused on laparoscopic morcellation. LPMs are also cleared for other uses within general surgery and urology. These other uses are outside the scope of this current discussion as well.

Note: Throughout this Executive Summary, results cited from studies which were reported as statistically significant will be noted in italics. Non-italicized results either had a p-value that was not significant or no p-value reported. Caution should be taken in interpreting statistically non-significant values as the study may not have been adequately powered for that endpoint. In addition, statistical significance should not be interpreted to represent clinically significant outcomes or differences.

2 Fibroids and Uterine Sarcoma

2.1 Background on Uterine Fibroids¹⁻⁶

Uterine fibroids – also known as uterine leiomyomas or myomas - are the most common type of pelvic tumors seen in women. They are benign monoclonal tumors composed of smooth-muscle cells associated with extracellular matrix including collagen, fibronectin, and proteoglycans. The fibroid is often surrounded by a pseudocapsule and may occasionally contain calcification. Their growth is regulated by steroids (estrogen and progesterone) as well as numerous growth factors produced by smooth muscle cells and fibroblasts. Uterine fibroids are generally classified by location as:

- *Intramural fibroids* - located within the myometrium of the uterus.
- *Subserosal fibroids*- located just underneath the outer serosal surface of the uterus.
- *Submucosal fibroids* – impinging on the uterine cavity, beneath the mucosa or uterine lining.
- *Pedunculated fibroids* - located on a pedicle stalk which contains their blood supply.

These classes may not be mutually exclusive, e.g., a submucosal fibroid can have intramural portion. Fibroids can vary in size, and may be present as a solitary mass, or as multiple lesions present at one time. Up to 80% of women will have uterine fibroids sometime during their lifetime. Factors that may affect the risk for developing uterine fibroids include:

- *Age*: Fibroids rarely occur before menarche and the prevalence increases as a woman advances through her reproductive years, peaking in the 5th decade. Following menopause, fibroids usually shrink.
- *Family History (FHx)*: Women with affected first-degree relatives are ≥ 2 times more likely to develop fibroids themselves.
- *Race*: African American women are more likely than Caucasians to develop fibroids, be diagnosed with fibroids at younger ages, have symptomatic fibroids, and have more or larger fibroids.
- *Reproductive History*: The risk for uterine fibroids is inversely associated with the women's parity (although this may not be true for African Americans). The risk is also higher in women with menarche at an earlier age (e.g., age 10 or before). Childbearing during the mid-productive ages appears to lower the risk.
- *Weight/Obesity*: Obese women are more likely to develop fibroids than non-obese women. For each 10kg increase in weight, a woman's risk of developing fibroids goes up by approximately 21%.
- *Smoking*: Smoking, possibly due to nicotine's effects on conversion of androgens to estrone, may *reduce* the risk of uterine fibroids in a dose-dependent manner – at least in Caucasian women. The risk may be reduced by as much as 50%.

Although many women with fibroids are asymptomatic, others may present with a variety of signs or symptoms. Although none are specific or diagnostic for uterine fibroids, they may include:

- *Irregular bleeding:* The most common presenting symptom in women with uterine fibroids (~30% of women with fibroids) is abnormal uterine bleeding – usually prolonged and heavy menses (menorrhagia). In some cases, chronic bleeding may result in iron deficiency and anemia.
- *Abdominal/pelvic pain or pressure:* The location of a fibroid may impact the location of perceived pressure or pain. For example, posteriorly positioned fibroids may result in low back pain and anteriorly positioned fibroids may present as bladder pressure.
- *Alteration in urinary function:* Pressure exerted on the bladder and associated structures may cause increased urinary frequency or difficulty voiding/urinary retention. In rare cases, compression of the ureter may cause hydronephrosis and a decline in renal function.
- *Rectal pressure or constipation:* Fibroids in the posterior wall of the uterus may exert pressure on the rectum/sigmoid causing constipation and/or tenesmus.
- *Painful sexual intercourse (dyspareunia):* Pain during intercourse may be more prominent with growth near the cervix or vaginal tract.

Fibroids may impact a woman's ability to become pregnant.⁶⁻¹⁰ They are found in up to 10% of women presenting with infertility, and in 1-2.5% of women with infertility they are the only abnormal finding. In general, clinically significant *submucosal* fibroids are believed to lower implantation and pregnancy rates as well as increase spontaneous abortion rates. Removing such fibroids improves fertility. Uterine fibroids may also be associated with higher rates of complications *during* pregnancy/delivery including preterm labor, breech presentation, placenta previa, and cesarean delivery.^{3,4,10,133}

2.2 Uterine Sarcoma

Uterine sarcomas represent <5% of uterine malignancies and the American Cancer Society estimates that 1,600 new cases of uterine sarcoma will be diagnosed in 2014.⁵⁸ More than 95% of uterine cancers are carcinomas – the more common being cervical carcinoma and endometrial carcinoma. Compared to endometrial carcinomas, uterine sarcomas tend to be more aggressive and have worse prognoses. In addition, the more common carcinomas tend to occur in locations that may be more accessible to screening tests, such as biopsying/sampling compared to uterine sarcomas. The following different histological types of uterine sarcomas have been classified: leiomyosarcoma (LMS); endometrial stromal sarcoma (ESS); undifferentiated uterine sarcoma; adenosarcoma; and carcinosarcoma. Each of these types of uterine sarcomas is briefly discussed in Appendix B of the Executive Summary. The age-adjusted incidence rates of leiomyosarcoma for women ≥ 35 per 100,000 US population based on nine SEER registries 1989-1999 was 0.917 for white non-Hispanic vs. 1.511 for African-American women.

The Surveillance, Epidemiology and End Results (SEER) program statistics review for 1975-2010 reported adjusted incidence and US death rates from Cancer of the Corpus and Uterus not otherwise specified (NOS) by age and race¹⁶⁴. Annual Percentage Change (APC) for incidence and mortality indicated significant increase in incidence among both white (non-Hispanic) and African-American women age <50 since the late 1980s, and a larger increased APC in incidence among African-American women age 50+ since approximately 1999. Mortality from cancer of the corpus and uterus, NOS had a significant APC increase among white women age <50 from 1988 – 2010, African-American women <50

from 1995 – 2010, and African-American women 50+ from 1997 – 2010¹⁴⁶. Mortality data from uterine cancer are not available by histology, so it is unknown what subtypes of uterine cancer are reflected in the above mortality data.

The panel will be asked to discuss any patient/fibroid characteristics or pre-operative exam findings that may be predictive of uterine sarcoma.

2.3 Diagnostic Considerations for Uterine Fibroids and Sarcomas

There are a number of diagnostic tools used by clinicians to evaluate women with fibroids including physical exam, serum biomarkers, biopsy/cytology, ultrasound, hysteroscopy, hysterosalpingography, magnetic resonance imaging and computed tomography imaging; however, none of these methods have been shown to reliably differentiate a fibroid from a leiomyosarcoma. More specific information on these modalities and diagnostic considerations for uterine fibroids and sarcomas are presented in Appendix C of the Executive Summary.

The panel will be asked to comment on the available evidence regarding pre-treatment diagnostics for determining the presence of a uterine sarcoma and/or differentiating from benign fibroids.

3 Treatment Options for Uterine Fibroids

3.1 Surgical Options for Fibroids

After a patient and her physician have decided that surgery is appropriate for her fibroids, the next step is to select the treatment from multiple options. One of the more common treatment options is surgical intervention. When considering surgical options, the fundamental decision is whether to remove the entire uterus (hysterectomy) or to excise only the fibroid(s) believed to be contributing to symptoms (myomectomy). The decision to undergo hysterectomy or myomectomy hinges on multiple factors including the desire for future childbearing, age, risk of recurrent fibroids, history of cervical or endometrial atypia, and family history of hereditary cancer. Both surgeries can be performed using a variety of surgical procedures. The details of these procedures vary by surgeon. An overview of hysterectomy and myomectomy procedures is provided below.

Hysterectomy

Hysterectomy is the most common in-patient gynecological surgery performed in the US. In 2010, there were approximately 498,000 hysterectomies. Approximately 73% of these were performed by traditional procedures (open laparotomy (54%) or total vaginal hysterectomy (19%)), 21% were minimally invasive laparoscopic procedures, and 6% were performed using computer assisted (robotic) surgical systems.¹² Whereas the fallopian tubes and ovaries are sometimes removed (i.e. salpingo-oophorectomy) during hysterectomy, this overview is limited to hysterectomy only. The following discussion summarizes key aspects of traditional and minimally invasive hysterectomy.

Hysterectomy - Traditional

Total Abdominal Hysterectomy (TAH) is the most common surgical procedure for removing the uterus. The entire uterus, including uterine cervix, is removed. TAH is performed via horizontal or vertical incision in the wall of the lower abdomen. In TAH, the uterine body must be divided in stepwise bilateral fashion from its attachments and blood supply within the pelvis before it can be cut free from the vagina. The major steps in TAH are dividing the utero-ovarian vasculature and round ligaments, opening the broad ligament and dissecting the bladder off the anterior lower uterine segment, skeletonizing and dividing the uterine arteries, dividing the ligaments attached to the lower uterus, and cutting the specimen free from the upper vagina. The entire specimen is removed in a single piece (“en bloc”) through the incision in the abdominal wall. The edge of the upper vagina (“cuff”) is sutured and secured to the ligamentous tissue pedicles to help maintain vaginal length and supports. The opening between the pelvis and vagina is closed. The abdominal wall incision is sutured closed in layers and the skin is re-approximated.

Subtotal (or supracervical) abdominal hysterectomy is performed in a similar stepwise manner to TAH up to the point where the uterine arteries are divided. After securing the uterine arteries, the body of the uterus is amputated from the cervix. Randomized controlled trials evaluating clinical outcomes following TAH vs. subtotal abdominal hysterectomy provide evidence that subtotal hysterectomy does not provide superior sexual function. The risk of surgical complications is also similar between these methods.¹³⁻¹⁵

Of all abdominal hysterectomies performed in the US, the majority are TAH. In 2003, approximately 371,000 TAH were performed vs approximately 35,000 subtotal abdominal hysterectomies.¹⁶

Total vaginal hysterectomy (TVH) is division of the uterus (including cervix) from its attachments in the pelvis and vagina and delivery of the uterus through the vagina without an abdominal incision. Visualization is limited compared to TAH. Initially, the cervix is grasped with a tenaculum and the overlying vaginal epithelium incised circumferentially. The lower pelvis is then entered via a colpotomy incision, after which the major surgical steps in TVH are essentially the same as for TAH, however they are performed in reverse order. The entire specimen is then delivered. If the uterus is too large to be delivered en bloc, the surgeon can cut up and deliver the specimen in several smaller pieces using scissors or scalpel. Patient selection is important for successful TVH. Whereas patients with advanced uterine prolapse may be excellent candidates, this type of hysterectomy may not be optimal for a patient with large fibroids and a narrow pelvis. History of pelvic adhesive disease is also a relative contraindication.

A 2010 Cochrane Collaboration systematic review of hysterectomy found multiple statistically significant advantages of TVH over TAH, including quicker return to normal activities, earlier hospital discharge and less pain.¹⁷ The American College of Obstetricians and Gynecologists has recommended TVH as the preferred approach to hysterectomy in appropriately selected patients.¹⁸

Hysterectomy - Minimally Invasive

Minimally-invasive hysterectomy can be performed either trans-abdominally or by a combination of abdominal and vaginal routes. Laparoscopic hysterectomy (LH) requires surgical access to the abdomen and pelvis via multiple small (approximately ≤ 1 cm) abdominal wall incisions, gas insufflation, and endoscopes for real-time visualization of tissue and instruments. LH relies on electrosurgical devices for ligating vessels, resecting tissue, achieving hemostasis and often morcellation of bulky specimens for removal through small incisions that are the hallmark of laparoscopic surgery.

A relatively new “tool” in LH is the computer-assisted (robotic) surgical system which provides 3-dimensional visualization of tissues and surgical instruments in the pelvis. The system offers ergonomic advantages to the surgeon such as more natural hand movement compared to traditional laparoscopic surgery. Tactile feedback for the surgeon is sacrificed, however. The components of the system include grasping instruments, needle drivers and monopolar and bipolar cautery instruments. The system does not include a power morcellator, however commercially-available LPMs may be used during robotic-assisted procedures. Use of the system as a tool during hysterectomy increased from 0.5% in 2007 to 9.5% in 2010. The benefit to a patient of these procedures may be limited to shorter hospital stay. The risk profile of computer-assisted (robotic) surgery for hysterectomy vs. LH is similar, and computer-assisted robotic procedures carry higher cost.¹⁹

There are multiple variations on LH. The most common types can be distinguished based on the extent of laparoscopic surgical dissection, in particular whether the uterine vessels are ligated under laparoscopic visualization or manually via the vagina.

In laparoscopic-assisted vaginal hysterectomy (LAVH), the ovarian and round ligaments are ligated using electro-surgical instruments under laparoscopic visualization. The bladder is dissected off of the uterus. The uterine arteries are skeletonized. The remainder of the procedure is conducted as in TVH.

Total laparoscopic hysterectomy (TLH) is the division of the uterus (and cervix) from their attachments and blood supply under laparoscopic visualization. The opening between the pelvis and vagina is closed with suture similar to TAH. The uterine specimen can be removed through the vagina intact (or, if necessary manually morcellated in smaller pieces to facilitate vaginal removal). If vaginal removal is not feasible (e.g., due to patient factors), the specimen may undergo laparoscopic morcellation and removal.²⁰

Laparoscopic supracervical hysterectomy (LASH) is similar to TLH up to ligation of the uterine arteries. After this step, the mobilized uterine corpus is amputated off the cervix using an electro-surgical instrument and then morcellated (unless a mini-laparotomy is selected) for removal.

Overall, vaginal hysterectomy in appropriately selected patients and performed by skilled surgeons is preferred over all of the alternatives. Vaginal hysterectomy confers multiple benefits including faster recovery and lower rate of complications compared to alternatives. Minimally invasive hysterectomy (i.e., laparoscopic and computer-assisted robotic procedures) offers clinical benefits compared to open laparotomy including shorter hospital stay, lower intraoperative blood loss, lower risk of wound or abdominal wall infections, and faster return to normal activities. Compared to abdominal hysterectomy, however, minimally-invasive hysterectomy may carry a higher risk of urinary tract injury and longer operating times.^{17,18}

Some gynecologic professional organizations recently stated that the risk of death due to hysterectomy may be substantially higher after abdominal hysterectomy compared with a laparoscopic approach¹⁶⁶ and, more specifically, that patients who undergo abdominal hysterectomy have three times the risk of mortality compared to those who have LH¹⁶⁵. The evidence cited for these statements is the same 2013 retrospective cohort study using data from the Healthcare Cost and Utilization Project Nationwide Inpatient Sample from 2002 to 2008¹⁶⁷. It is unclear whether the design of this study is sufficiently robust to support the statements from the professional organizations. It was also recently stated that, compared to laparotomy, a minimally invasive approach for hysterectomy is associated with well-established decreased risk of both major and minor complications, including transfusion of blood products, wound infection, hernia and venous thromboembolic events. FDA has reviewed the literature regarding the risk of thromboembolic disease as a function of hysterectomy route and has not identified evidence from randomized controlled trials that would support an increased risk of thromboembolic

disease for open versus laparoscopic hysterectomy. The Cochrane Database meta-analysis of three randomized controlled trials (N=1125) that evaluated the rate of thromboembolic events among women undergoing LH vs open hysterectomy found that there were *no* differences between laparoscopic and open hysterectomy for this outcome.¹⁷

Comparative surgical outcomes as a function of hysterectomy technique as well as the Cochrane manuscript are provided in Appendix D.

Uterine Sparing – Myomectomy for Selective Fibroid Removal

The choice of surgical route and technique for myomectomy depends to a large degree on fibroid location and size. Pre-operative imaging, e.g. saline-infusion sonography and MRI (See Appendix C), can inform surgeon planning regarding optimal route and likely location of incisions on the surface of the uterus. Because fibroids can be highly vascular, considerable blood loss may occur.²¹ For patients with normal hemoglobin levels, autologous blood banking can be considered. For patients with anemia secondary to bleeding fibroids, GnRH (See Section 3.2.2) may be considered to restore blood levels prior to surgery.²²

Open abdominal myomectomy is performed via abdominal wall incision, similar to TAH. Different techniques may be used to minimize blood loss during dissection of the myoma from its pseudocapsule and excision, including injecting around the fibroid with vasopressin and placing a tourniquet at the level of the uterine arteries.²³ The surface of the uterus is incised or “scored” through the pseudo capsule, usually with cautery. The fibroid is dissected free from its capsule using both sharp and blunt dissection and cautery when vessels are encountered. More than one fibroid can often be removed via a single incision on the uterine serosa. The myometrial defect is sutured closed in layers, with emphasis on hemostasis and restoration of uterine symmetry. The uterine surface is sutured similar to the pattern on a baseball. Copious irrigation is performed to remove blood clots that can increase the risk of adhesion formation. The abdomen is closed.

Minimally-invasive laparoscopic myomectomy is excision of fibroids and repairing the uterine defect via multiple small abdominal wall incisions under endoscopic visualization. Computer-assisted (robotic) surgical system can also be used for minimally invasive myomectomy. Options for removing the resected fibroid(s) include extending an abdominal wall incision and power morcellation.

Compared to open myomectomy, laparoscopic myomectomy is associated with less operative blood loss, post-op pain, faster recovery and fewer adhesions.²⁴ (Reducing the risk of adhesions is especially important because myomectomy is often performed in women with suspected fibroid-related infertility.) The risk of major complications and recurrence is similar across both procedures. Relative disadvantages of laparoscopic versus open myomectomy include longer operating time and the need for fibroid morcellation.²⁵

For fibroids that are confined to the endometrial cavity and inner myometrium, a transvaginal procedure without an abdominal wall incision is appropriate. Hysteroscopic myomectomy utilizes transvaginal endoscopic visualization of the uterine cavity using pressurized distension fluid. Submucosal fibroids are resected using electrosurgical wire loops that cut and coagulate or morcellated using electromechanical morcellators. Blood and tissue must be continuously removed via outflow channels in the operative hysteroscope or filtered in closed-loop systems via tissue traps and filters in order to maintain visualization. Hysteroscopic myomectomy is overall less morbid compared to abdominal or laparoscopic myomectomy, but is not risk-free. Distension, fluid inflow and outflow must be consciously monitored to ensure that excess vascular intravasation is not occurring.

3.2 Non-Surgical Treatment Options for Fibroids

In addition to traditional and MIS procedures described above, several other treatment options are available for the management of symptomatic uterine fibroids. These will be briefly summarized here.

3.2.1 Expectant Management^{4,44, 184}

Expectant management (e.g., “watchful waiting”) is sometimes considered in women close to menopause since fibroids often recede after that time. However, the variability in the natural history of fibroids is considerable. In one study following 262 fibroids in 72 women over one year with MRI, the median growth in volume was 9% but shrinkage as high as 89% was seen and an increase in volume as high as 138% was also reported⁴⁴. David recently reported on 72 fibroids in 55 premenopausal women followed by TVUS¹⁸⁴. During a 6-month interval over 50% of the fibroids grew by more than 30% on average. Fifteen percent of fibroids regressed in size. Patient age and original fibroid size may be predictors of growth – smaller fibroids may grow more than larger ones. In addition, African-American women over age of 35 have a higher rate of growth compared to Caucasians. Even for a given patient, individual fibroids may have different rates of growth.

3.2.2 Pharmaceutical Therapy

*Gonadotropin-releasing hormone (GnRH) Analogues*¹⁰²⁻¹⁰⁶

GnRH analogues suppress the pituitary-ovarian axis and block production of estrogen and progesterone. They are FDA-approved for the preoperative hematologic improvement of patients with anemia caused by uterine fibroids. A depot dose given 3 months prior to surgery has been shown to improve pre-operative pain/pressure, vaginal bleeding, and iron deficiency anemia and to reduce fibroid volume (~35-65%). They reduce intra-operative blood loss when compared to placebo but provide no additional benefit as relates to surgery time, hospital stay, post-operative complications or fibroid recurrence. The benefits only persist for 3-6 months. Side effects include hot flashes, mood swings, vaginal dryness, amenorrhea, and osteoporosis. Osteoporosis may be significant and not necessarily improve with stopping the drug. Because of the side effects, FDA recommends a maximum duration of treatment of no longer than 6 months (e.g., 2 consecutive depot injections).

*Hormonal Therapy to Treat Menstrual Bleeding*¹⁰⁷⁻¹¹⁰

Combination oral contraceptive pills (OCP), and progesterone-only products, although not specifically approved by FDA for the treatment of uterine fibroids, have been reported to help control heavy bleeding and symptoms associated with fibroids. However, they do not provide definitive treatment for fibroids. In 2009, the levonorgestrel-releasing Mirena IUD (Bayer Pharmaceuticals) was FDA-approved to treat heavy menstrual bleeding for women who choose to use intrauterine contraception as their first method of contraception. In women with uterine fibroids Mirena decreases menstrual blood loss (MBL) and increased serum hemoglobin, hematocrit, and ferritin levels, although fibroid size does not change. Up to 10% of women may, however, eventually undergo hysterectomy for continued menorrhagia.

Tranexamic acid (TA)

Tranexamic acid was granted approval by FDA in 2009 for the treatment of menorrhagia. Eder published a post-hoc pooled analysis of two pivotal RCT Phase III trials of TA for menstrual bleeding which included 96 women with fibroids receiving TA and 50 controls with fibroids receiving placebo¹¹¹. Mean MBL (as measured by alkaline hematin method) was significantly reduced in the TA patients at the first visit (e.g., after first menstrual cycle) compared to control subjects – going from 202 mL to 112 mL in the TA arm, and from 177 mL to 174 mL in the placebo group. Improvements were generally maintained throughout study follow-up (generally 3 menstrual cycles). Common adverse reactions include headache, abdominal pain, joint/muscle pain, anemia, and fatigue. In addition, concurrent use with hormonal contraceptives may increase the risk of blood clots, stroke, or myocardial infarction.

Other Pharmaceutical Agents

Iron supplementation may be beneficial in women with anemia due to chronic bleeding from fibroids and NSAIDs/acetaminophen are often used to help decrease general pain associated with fibroids. Although a number of other pharmaceuticals have been evaluated for the treatment of uterine fibroids (e.g., ulipristal, mifepristone, aromatase inhibitors) they are not currently FDA-approved for such indications.

3.2.3 Magnetic Resonance Guided Focused Ultrasound (MRgFUS)¹¹²⁻¹²⁶

In 2004, FDA approved the ExAblate 2000 System (InSightec Ltd) for the ablation of uterine fibroid tissue in pre- or peri-menopausal women with symptomatic fibroids and uterine size < 24 weeks. The system integrates a high intensity focused ultrasound system with MR imaging to deliver US energy and thermally ablate fibroids. MRgFUS is non-invasive and does not expose the patient to ionizing radiation.

Published reports on MRgFUS (largely single arm, single-center experiences, with variable follow-up success) have generally shown significant improvements in the validated Symptom Severity Scores (SSS) and Uterine Fibroid Quality of Life (UF-QoL) measures for a substantial proportion of patients. Mean and median changes in SSS scores (scale of 1-100 with 100 = more severe symptoms) of 20-30 points at 6-24 months have been reported. Modest reductions (20-50%) in dominant fibroid volume are also seen. Although a substantial proportion of patients have symptom improvements, many eventually require or undergo additional invasive interventions for persistent/recurrent symptoms (hysterectomy, myomectomy, uterine artery embolization). Rates of reintervention may be as high as 30-35% after 2 years.

The more common adverse events associated with MRgFUS therapy include peri-procedural abdominal pain (up to 40%), peri-procedural nausea/vomiting, temporary back or leg pain resembling sciatica (up to 20%), abnormal vaginal discharge, and first/second degree skin burns.

3.2.4 Uterine Artery Embolization¹³⁴⁻¹⁵⁷

Uterine artery embolization (UAE) is a uterine-sparing interventional vascular procedure in which particulate emboli are introduced into the (bilateral) vascular bed supplying a fibroid(s) – inducing ischemic changes. FDA-cleared embolic agents for fibroids (and other vascular tumors) include:

- Embosphere Microspheres (Biosphere Medical): acrylic polymer and porcine-derived gelatin.
- Embozene® Microspheres (CeloNova): polymethacrylate, coated with Polyzene®-F.
- Contour, Contour SE Embolization Particles (Boston Scientific): polyvinyl alcohol particles

- Cook Polyvinyl Alcohol Foam Embolization Particles (Cook).
- Bearing NsPVA Embolization Particles (Merit Medical Systems): polyvinyl alcohol particles.

Numerous studies and reviews on UAE have been published over the past 2 decades, including multiple prospective, controlled trials comparing UAE to surgical hysterectomy and/or myomectomy. In general, these studies reported several advantages for UAE over hysterectomy or myomectomy with respect to procedural and peri-procedural outcomes, including having shorter procedure time, less operative blood loss, less post-procedure pain, shorter hospital stay, shorter recovery and return to activities. However, these results must be interpreted with caution as a significant proportion of the data for control groups involved outcomes following *open* abdominal surgical procedures, rather than *laparoscopic* procedures.

Short- and intermediate-term clinical outcomes (e.g, through 12-24 months) from controlled studies with hysterectomy, hysterectomy + myomectomy, myomectomy or uterine artery occlusion as control groups have generally shown significant improvements in many symptoms and signs including bleeding/menorrhagia, pelvic pain, pelvic pressure, and quality of life measures (SSS, UF-QoL, SF-36) - with results often on par with the surgical group. In general, studies have also shown reductions in dominant fibroid volumes on the order of 40-60% between 6 and 24 months.

Studies with longer-term follow-up (e.g., 3-9 years, usually single-arm cohorts with retrospective data collection and variable follow-up) have suggested continued symptom relief/improvements and QoL improvements in substantial percentages of available patients when compared to baseline. As with MRgFUS, however, rates of reintervention (hysterectomy, myomectomy, repeat UAE) due to persistent or recurrent symptoms for patients undergoing UAE, may be as 30-35% at 2-5 years.

Postembolization syndrome – consisting of constitutional symptoms such as pain, nausea, fever – has been reported as a frequent complication after UAE (up to 25% of patients) but generally resolves in 7-10 days. Prolonged symptoms may indicate infection. Abnormal vaginal discharge is also a common event and fibroid expulsion (FE) may occur in up to 15% of patients. FE typically occurs in the first 6 months and may present with cramping, vaginal discharge, bleeding and/or tissue passage. It is more common with submucosal fibroids. Some cases may require an operative procedure including hysterectomy. Although uncommon, severe infections/sepsis may occur and urgent hysterectomy may be required. Amenorrhea, possibly caused by non-target embolization of the ovarian artery may also occur and is more common in women over 40-45.

3.2.5 Radiofrequency Volumetric Thermal Ablation

In 2013, FDA cleared the Acessa system (HALT Medical) for ablation of targeted fibroids by monopolar radiofrequency (RF) energy under US guidance. The study used to support FDA clearance demonstrated that at 12 months, 84% of evaluable subjects experienced a reduction in bleeding and approximately 40% of women had at least a 50% reduction. Mean SSS scores improved significantly from baseline to 3 months (approximately 35 points) and remained at similar levels through the remainder of the study and through follow-up to 36 months^{159,160}. Mean reduction in fibroid volume was 25% at 12 months. The surgical reintervention rate was 0.8% at 12 months and 11% at 36 months. The most common adverse event was urinary tract infection (4.4%). Less frequent events were abdominal pain and dysmenorrhea.

3.2.6 Endometrial Ablation

Endometrial ablation refers to a set of procedures that, through a variety of mechanisms, aim to destroy the endometrial lining of the uterus to treat abnormal uterine bleeding. “First Generation” techniques were performed hysteroscopically beginning in the early-mid 1980s and include:

- Transcervical loop resection using a metal loop and RF energy.
- Roller-ball therapy where the loop is replaced with a small metal ball
- Laser ablation using lasers such as the Nd-YAG laser.

“Second and Third Generation” global endometrial ablation techniques refer to FDA-approved intra-uterine devices which employ heat, microwave, cryotherapy, or radiofrequency. The majority of studies used to gain FDA approval for these latter generation devices excluded women with submucosal fibroids or submucosal fibroids that distort the uterine cavity, and as such *the devices are not specifically approved by FDA for the treatment of fibroids*. However, a handful of publications have since reported on outcomes on small populations of women with submucosal fibroids treated with the hydrothermal ablation system (HTA, Boston Scientific), noting significant improvements in bleeding/menorrhagia for a substantial proportion of patients¹⁶¹⁻¹⁶³.

4 Laparoscopic Power Morcellators

Morcellation refers to the division/fragmentation and removal of tissue. In the context of laparoscopic procedures, it provides a method for removing tissue without the need for an incision site that is of the same or greater size. In a prospective observational study of 112 consecutive women undergoing total laparoscopic hysterectomy Condous sought to identify factors associated with the need to perform uterine morcellation.¹⁸⁹ In 50% of the subjects the uterine specimen could not be delivered vaginally and morcellation was performed. Nulliparity and increasing uterine weight were both predictors for the need for morcellation (OR = 7.31 and OR/100-gram increase = 6.03 respectively).

Over time, laparoscopic surgeons have used a variety of “manual” methods to fragment tissue and facilitate their extraction through the smaller incisions including fingers, forceps, clamps, and scalpels. In the early 1990s, a manual device with a serrated blade that enabled the coring of cylindrical pieces of tissue was introduced. The device required manual repetitive twisting motions and had a morcellation rate of approximately 2 grams/minute.

In 1993, Steiner²⁶ reported on an instrument intended for “laparoscopic removal of fibromas, ovaries, or other tissues” described as a “cylinder with a coning knife” which “is rotated by an electrical micro-engine attached to the trocar.” Following that report, the development, manufacturing, and use of LPMs expanded through the 1990s and 2000s. Their development and use contributed to the rise in minimally invasive gynecologic surgery. LPMs generally rely on spinning blades (100-1200 rpm) to fragment tissue. Early LPMs used the “coring principle” to core out cylindrical pieces of tissue for removal with morcellation rates of < 15 g/min. Second generation devices are based on the “peeling principle” where the device incorporates an overhanging edge at the distal end allowing the blade to provide more continuous tissue removal. These devices have morcellation rates of ≥ 30 grams/minute²⁷. In addition to electromechanical morcellators, FDA has also cleared a laparoscopic morcellator which uses radiofrequency energy to fragment tissue.

The panel will be asked to discuss whether the mode of morcellation, i.e., electromechanical versus radiofrequency, or other design factors, e.g., speed of rotation, increase tissue fragmentation and dissemination into the peritoneal cavity.

Table 1. below identifies LPMs which have received FDA clearance for use in gynecologic surgeries and have been marketed within the past year:

Table 1. LPM Device Manufacturers

Manufacturer/Distributor	Model(s)
Ethicon	1. Gynecare Morcellators 2. Gynecare Morcellex 3. Morcellex Sigma
Karl Storz	1. Sawahle Morcellator 2. Rotocut SIII
Richard Wolf (Manufactured by NouvagAG)	1. Morce Power Plus
LiNA Medical	1. LiNA Xcise
Trokamed GmbH	1. Trokamed Morcellator
Gyrus (Subsidiary of Olympus Medical)	1. PlasmaSORD

Product labeling for marketed LPMs varies across manufacturers in terms of statements regarding use on malignant tissue and on the use with a specimen bag. In addition, most current labeling does not include any specific information on the risks associated with morcellating an unsuspected malignancy or the potential for disseminating benign tissue. Appendix E provides a summary of the relevant labeling components for each of the manufacturers noted in Table 1 above.

The panel will be asked to provide recommendations on LPM labeling (including instructions/directions for use) to specifically address use in women with fibroids and in women with known or suspected gynecologic malignancy.

4.1 Pre-market Testing of LPMs

FDA has cleared 510(k)s for LPMs indicated for a variety of uses, including general surgery, urology, and gynecology. Pre-market testing provided to FDA includes non-clinical testing and, in some cases, clinical testing. The level of testing has varied during an approximately 20 year period.

To support clearance, LPMs need to be studied for general requirements of basic safety as outlined in consensus standards, e.g., AAMI/ANSI ES60601-1 including an evaluation of electrical safety and may include electromagnetic compatibility testing (e.g., AAMI/ANSI EN60601-1-2). For devices that use radiofrequency, additional testing for high frequency surgical equipment in accordance with a consensus standard, e.g., IEC 60601-2-2, is typically needed. In cases in which the device is battery powered, additional testing on the battery life is necessary. In addition to material safety and sterility, sponsors may need to address durability of the motor, including the number of revolutions per minute over the expected duration of use and heat generation. Data on the rate at which the device cuts tissue in a justified model

may be needed. For LPMs with seals to minimize the leak of CO₂ gas from the device, seal strength (i.e., resistance to damage/displacement following tissue removal) and leak flow rate data may be necessary.

Testing of a new device depends on the differences in indications and/or technological characteristics compared to the predicate device, usually a currently marketed LPM.

The first 510(k) clearance with an indication for gynecologic laparoscopic procedures (specifically myomas) was the Karl Storz Steiner Electromechanical Morcellator, K946147. The manufacturer provided information from the literature on use of their device to morcellate fibroids and ovaries²⁶ where surgeons used the device in 11 subjects to successfully remove five fibroids and six ovaries without complication. It was possible to conduct histological assessments on the retrieved specimens. The Gynecare Laparoscopic Morcellator, K993801, was the first 510(k) cleared power morcellator that included a specific indication for hysterectomy. Published clinical data supported this indication as well. The device was used in 12 consecutive women scheduled to undergo supracervical hysterectomy¹²⁸. The authors reported that all cases were completed as planned with the morcellator. The mean rate of morcellation was 14 g tissue/minute and the mean blood loss was 104 ± 46 ml. No postoperative complications were reported. For subsequent gynecologic LPMs, only non-clinical testing was necessary.

The risk of tumor spread was not identified during the pre-market review of these devices and therefore no risk reducing measures were required for pre-market clearance.

4.2 Benefits of LPMs

As noted above, LPMs are surgical tools to facilitate the removal of surgical specimens, including fibroids and the uterus, during minimally invasive abdominal surgical procedures. As the devices are intended to allow a procedure to be completed laparoscopically, their benefits are tied to the benefits of laparoscopic surgery in cases where the surgical specimen is not removed through the vagina. Accordingly, FDA reviewed the medical literature for review articles comparing surgical approaches for hysterectomy for benign indications and identified two reviews. The first, a Cochrane review, examined the comparative benefits of laparoscopic hysterectomy (LH) versus vaginal and abdominal hysterectomy, TVH and TAH, respectively¹⁷. The second review, a meta-analysis also comparing LH and abdominal hysterectomy, was published in 2011³⁰.

In the Cochrane review, 27 trials comprised of 3643 patients comparing the risks and benefits of abdominal hysterectomy, vaginal hysterectomy, and LH were reviewed. The reviewers concluded that vaginal hysterectomy should be performed in preference to abdominal because of more rapid recovery and fewer febrile episodes post-operatively and that where vaginal hysterectomy is not possible, LH has some advantages over abdominal hysterectomy including fewer wound/abdominal wall infections (*OR* 0.31, 95% CI 0.12 to 0.77; 530 women, 6 trials), fewer unspecified infections or episodes of fever (*OR* 0.67, 95% CI 0.51 to 0.88; 2138 women, 15 trials), smaller drops in hemoglobin (Mean Difference (MD) 0.55 g/L, 95% CI 0.28 to 0.82 gm/L; 288 women, 3 trials), less post-operative pain, earlier hospital discharge (MD 2.0 days, 95% CI 1.9 to 2.2 days; 1007 women, 10 trials) and a quicker return to normal activities (MD 13.6 days, 95% CI 11.8 to 15.4 days; 520 women, 6 trials).

Disadvantages of LH were longer operating times (5 trials) and more urinary tract injuries (*OR* 2.41, 95% CI 1.21 to 4.82; 2090 women, 12 trials) when compared to abdominal hysterectomy. No significant advantages of LH over vaginal hysterectomy were found in the review. The findings in the 2011 meta-analysis were consistent with the Cochrane review and yielded no substantially new conclusions.

In summary, the Cochrane authors report clear superiority of vaginal over abdominal hysterectomy. When LH is compared to abdominal hysterectomy there are significant benefits (less operative blood loss, fewer febrile episodes, fewer wound/abdominal wall infections, and more rapid recovery) counterbalanced by increased operative times and urinary tract injuries.

Compared to open myomectomy, laparoscopic myomectomy is associated with less operative blood loss, post-op pain, faster recovery and fewer adhesions.²⁴

4.3 Complications and Risks of LPMs

A review of the published literature includes the following complications associated with the use of LPMs: injuries to local organ/tissue; tissue architecture disruption and tissue dissemination (benign and malignant).

4.3.1 Injuries to Local Organs/Tissue

Milad³³ performed a review of the FDA's adverse event database ("MAUDE") between 1992 and 2012 for adverse events associated with LPMs and noted reports of short-term complications/injuries to the small/large bowel (31), vasculature (27), kidney (3), ureter (3), bladder (1), and diaphragm (1). For the majority of events (66%), the complications were noted intraoperatively; however, some were not identified for as many as 10 days postoperatively. Gynecological operations (hysterectomy, myomectomy) accounted for many of the reports. Among the contributing factors identified were lack of surgeon experience/training, lack of visualization, and failure to maintain adequate pneumoperitoneum.

4.3.2 Dissemination of Benign Tissue

Multiple reports in the literature note iatrogenic dissemination of fragments of benign tissue following morcellation with subsequent "parasitic" growth including fibroids, endometriosis, and adenomyosis as well as abscess formation and peritonitis³⁵. "Parasitic myomas" were traditionally thought to be a variant of a pedunculated subserosal myoma which became detached from the uterus, adhered to surrounding tissues, and received an alternative blood supply. Although described over 100 years ago, their presence was thought to be relatively rare. In the mid-2000s, another theory suggested that parasitic myomas may be caused by the seeding of portions of fibroids during morcellation. Based largely on retrospective case series, estimates for the incidence have ranged from 0.12% - 1.2%. In a 2011 review of 13 published reports which included 31 women with "parasitic fibroids", Cucinella³⁴ noted that the most frequent locations for lesions were the pelvic and parietal peritoneum, and along the GI tract. Multiple lesions were present in 45% of patients and the most common symptoms were abdominal/pelvic pain, sense of mass in the abdomen, and deep dyspareunia. In 73% of cases, the time from surgery to diagnosis was more than 2 years, and in 87% of cases, a power morcellator had been used prior.

Disseminated peritoneal leiomyomatosis (DPL) is a condition marked by multiple nodules of benign smooth muscle on the abdomino-pelvic peritoneal surfaces. Although these lesions may originate from subperitoneal mesenchymal stem cells which undergo smooth muscle metaplasia under normal hormonal stimulation, a link between dissemination of uterine tissue during morcellation and development of DPL has been proposed¹³².

The panel will be asked to discuss the risk of benign tissue dissemination and how it should be addressed in product labeling.

4.3.3 Disruption of Malignant Tissue Pathologic Architecture

An additional concern regarding power morcellation during MIS is the potential impact on the ability to interpret the pathologic specimen accurately. Not only may an unsuspected uterine malignancy be missed on examination of the morcellated specimen, but even if one is noted, it may be difficult to accurately grade and/or stage¹⁶⁸. Tumor size, margin status (in cases of myomectomy), vascular involvement, etc. may be difficult to assess. The result may be a delay in diagnosis or difficulties in making decisions on adjuvant treatments. As discussed in more detail in Appendix B, a uterine sarcoma's tumor stage is a significant predictor of outcome as well as a factor in determining treatment options.

4.3.4 Dissemination of Malignant Tissue

The dissemination of malignant cells within the peritoneal cavity through the inadvertent morcellation of a uterine malignancy and the potential subsequent upstaging of the disease is the most concerning complication associated with LPMs and is the main subject of this Advisory Committee meeting. The remaining parts of Section 4.3.4 describe FDA's review of data related to the dissemination of malignant tissue by morcellation during hysterectomy or myomectomy for fibroids, and the clinical sequelae.

4.3.4.1 Unsuspected Uterine Sarcoma in Women Undergoing Hysterectomy/Myomectomy for Fibroids

FDA undertook a systematic assessment of the peer-reviewed literature to estimate the prevalence of unsuspected sarcoma - and leiomyosarcoma (LMS) specifically - among women undergoing a hysterectomy or myomectomy for presumed fibroids. PubMed, Web of Science and EMBASE were searched to identify relevant literature published in English between 1980 and 2014 using the terms uterine cancer AND hysterectomy or myomectomy AND incidental cancer or uterine prolapse, pelvic pain, uterine bleeding and uterine fibroids. Identified abstracts were reviewed and copies of all publications that appeared to contain relevant information were obtained. The reference lists of identified publications were also reviewed for additional articles. Cohort or cross-sectional studies of hysterectomy or myomectomy for presumed benign fibroids that included both the number of cases of sarcoma, and the total patient population reviewed, regardless of sample size, were included. A total of 8 studies and 1 abstract met the criteria and were included in the analysis to estimate the pooled prevalence of (1) uterine sarcomas and (2) uterine LMS among women undergoing a hysterectomy or myomectomy for fibroids.

Estimates were created for uterine sarcoma and LMS outcomes. Three estimates were generated for each outcome: (1) a simple pooling of numerators and denominators; (2) a random-effects model based on the DerSimonian-Laird method using StatsDirect software; and (3) a random-effects model using a generalized linear mixed model in SAS 9.3 (PROC GLIMMIX). Random-effects models were used due to heterogeneity among the individual studies. Proportions and 95% confidence intervals (calculated using the exact binomial method) were converted to rates per 1,000 persons.

Studies contained in the analysis are included in Table 2 below. Five of the nine studies were conducted in the U.S. Hysterectomy was the sole surgical procedure in 6 of the studies, hysterectomy or myomectomy were included in 1 study and myomectomy alone was included in 2 studies. Patient populations ranged from 104 to 1429 (mean=1017.8; median=1115). The number of patients with unsuspected uterine sarcoma in each study ranged from 0 to 7, as it did for LMS (mean=2.1; median=1.0).

**Table 2. Studies reporting unsuspected uterine sarcomas and LMS, 1980-March, 2014+
(Rates are per 1,000 patients)**

Author	Year Published	Study Years	Procedure(s)	Total Patients	Number of Uterine Sarcomas	Rate of Uterine Sarcoma (95%CI)	Number LMS	Rate of LMS (95% CI)
Leibsohn ³⁵	1990	1983-1988	Hysterectomy	1429	7	4.90 (1.97-10.07)	7	4.90 (1.97-10.07)
Reiter ³⁶	1992	1986-1989	Hysterectomy	104	0	0.00 (0.00-34.85)	0	0.00 (0.00-34.85)
Parker ³⁷	1994	1988-1992	Hysterectomy or Myomectomy	1332	3	2.25 (0.47-6.57)	1	0.75 (0.02-4.18)
Takamizawa ³⁸	1999	1983-1997	Hysterectomy	923	2	2.17 (0.26-7.81)	1	1.08 (0.03-6.02)
Sinha ³⁹	2008	1998-2005	Myomectomy	505	2	3.96 (0.48-14.23)	2	3.96 (0.48-14.23)
Kamikabeya ⁴⁰	2010	1987-2008	Hysterectomy	1364	2	1.47 (0.18-5.29)	1	0.73 (0.02-4.08)
Rowland ⁴¹	2011	2006-2011	Hysterectomy	1115	5	4.48 (1.46-10.43)	3	2.69 (0.56-7.84)
Leung ⁴²	2012	1999-2005	Hysterectomy	1297	3	2.31 (0.48-6.75)	3	2.31 (0.48-6.75)
Seidman ⁴³	2012	2005-2010	Myomectomy	1091	2	1.83 (0.22-6.61)	1	0.92 (0.02-5.10)

The estimated prevalences of unsuspected uterine sarcoma and LMS during hysterectomy or myomectomy for presumed benign conditions are included in Table 3 below.

**Table 3: Estimated prevalence of unsuspected uterine sarcoma and leiomyosarcoma
(Rate per 1,000 persons)**

Cancer	Simple Pooled	Random-Effects [DerSimonian-Laird] (95% CI)	Random-Effects [SAS PROC GLIMMIX] (95% CI)
Uterine Sarcoma	2.84	3.16 (2.12-4.42)	2.84 (1.81-4.46)
Uterine Leiomyosarcoma	2.07	2.29 (1.41-3.38)	2.01 (1.06-3.81)

There were small differences in the estimates depending on the method used to estimate. The most robust estimate, using the random-effects SAS PROC GLIMMIX model in the analysis, was 2.84 (1.81-4.46) per 1,000 persons and 2.01 (1.06-3.81) per 1,000 persons for the prevalence of unsuspected uterine sarcoma and LMS, respectively. This translates to an unsuspected uterine sarcoma in 1 in 352 women and an unsuspected LMS 1 in 498 women undergoing hysterectomy or myomectomy for presumed benign fibroids. Forest plots depicting the individual study rates and 95% confidence intervals as well as the pooled estimates for uterine sarcomas and uterine LMS are found in Figures 1 and 2 respectively.

Figure 1. Forest plot of estimated rate of unsuspected uterine sarcoma (and 95% CI) per 1,000 persons among patients undergoing hysterectomy or myomectomy for presumed leiomyoma

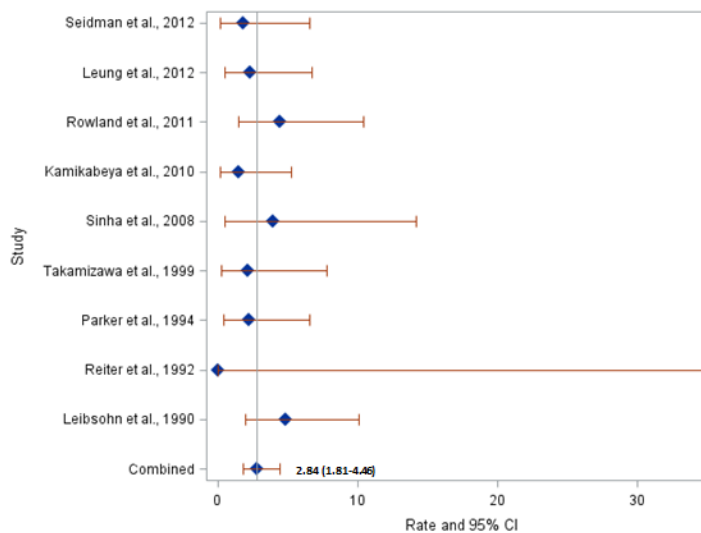
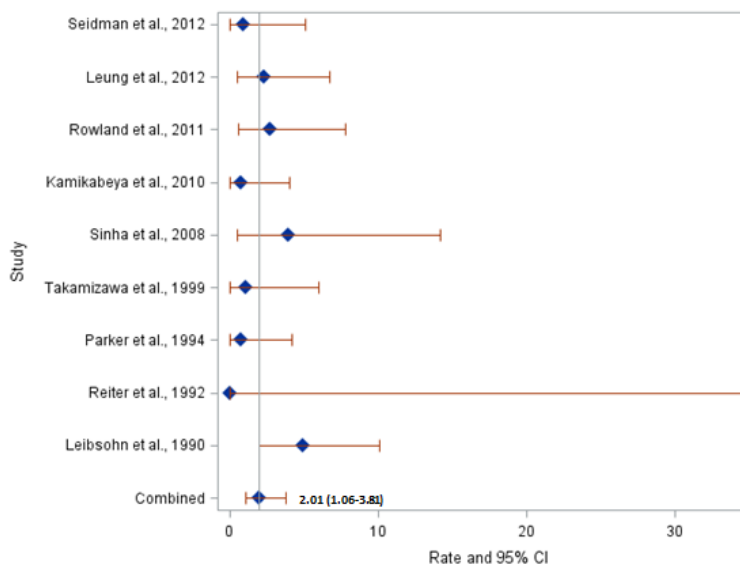


Figure 2. Forest plot of estimated rate of unsuspected uterine leiomyosarcoma (and 95% CI) per 1,000 persons among patients undergoing hysterectomy or myomectomy for presumed leiomyoma



4.3.4.2 Dissemination, “Upstaging” of Malignancy Following Morcellation

Dissemination and upstaging of a uterine sarcoma is crucial because of the significantly lower survival rates as cancer stage increases (See Appendix B on Sarcomas). To assess the probability of seeding an unsuspected sarcoma by morcellation and the outcomes related to morcellation of an unsuspected sarcoma (see below), FDA searched PubMed using the terms (uterus OR uterine) AND morcellat* (includes all terms that begin with morcellat). Our original search yielded 196 papers of which 152

provided full text and were published after 1980. Of these 152 papers, title review yielded 44 papers with potential applicability to the research question. After reviewing these papers in detail, 7 papers were ultimately included (39 papers excluded due to non-applicable cancers and/or case reports only). As in our prevalence analysis, only cross-sectional or retrospective cohort studies were included.

Using records from 1091 cases of uterine morcellation at one institution over 6 years, Seidman⁴³ found unexpected diagnoses of leiomyoma variants or atypical and malignant smooth muscle tumors in 1.2% of cases that had used power morcellation for presumed fibroids. When examining follow-up laparoscopies performed in 14 cases, disseminated disease occurred in 64.3% (9/14) of all tumors and four of seven (57%) cases of LMS.

Oduyebo⁴⁴ identified all cases at one institution of patients who had myomectomy or hysterectomy performed for presumed fibroids, where morcellation (76% power, 24% manual/hand) was performed, and a final diagnosis of LMS (15/21) or smooth muscle tumors of uncertain malignant potential (STUMP, 6/21) was determined. Sixteen of the 21 women they identified had re-exploration surgeries at a median of 33 days following diagnosis. Of the 7 women with presumed FIGO Stage I LMS at initial surgery, two (28.6%) were found to have disseminated intraperitoneal disease (Stage III) at early re-exploration. Of the 4 patients with presumed Stage I STUMP who underwent early re-exploration, one (25%) was found to have disseminated omental disease (Stage III) at follow-up surgery. A total of 8 women with a diagnosis of LMS underwent early re-exploration, and 3 (37.5%) were upstaged – the two noted prior, and an additional patient who was presumed to have Stage III initially, and Stage IV disease at follow-up. One of the 4 STUMP patients (25%) was upstaged (Stage I to III as noted above)

Einstein performed a retrospective descriptive review of 17 patients at one institution who had either uterine morcellation or supracervical hysterectomy and were subsequently diagnosed with any uterine malignancy (endometrial or sarcoma) on final pathology⁴⁵. Thirteen of the 17 underwent early re-operation/re-staging with a mean interval between the first operation and the restaging surgery of 63 days. This included 5 women with endometrial cancer, 4 with LMS, 3 with endometrial stromal sarcoma (ESS), and 1 carcinosarcoma). With respect to the 8 sarcoma patients who underwent re-staging, 7 had presumed Stage I disease at initial operation while the other had Stage III. Two of the 7 sarcoma patients with initial Stage I disease (28.6%) were upstaged to Stage III disease. Both had received morcellation. The patient with initial Stage III disease was upstaged to Stage IV during imaging studies and did not require a re-staging operation. This patient had not received morcellation. With regards to the 5 women with a final diagnosis of endometrial cancer who underwent early reoperation, none were upstaged, including one patient who had undergone morcellation. When considering only the 5 patients who had undergone morcellation regardless of tumor type (3 LMS, 2 endometrial), four underwent restaging operations (including all 3 LMS) and two were upstaged from Stage I to Stage III (both LMS). Of the 9 cases where morcellation was not performed, none were up-staged.

4.3.4.3 Impact of Morcellation of Uterine Sarcomas on Patient Outcomes (Recurrence, Survival)

As part of the literature review, FDA identified multiple studies that examined patient outcomes related to morcellation of an unsuspected sarcoma. The studies (Table 4 below) primarily reported on LMS. LMS was of interest because it is a rare uterine sarcoma and has poorer five year survival compared to other uterine sarcomas. Some studies captured LMS as well as other forms of uterine sarcoma (endometrial stromal sarcoma and carcinosarcoma) and other uterine lesions that harbor atypical or malignant features. It is important to note that the studies by Seidman⁴³, Oduyebo⁴⁴, and George⁴⁹ were conducted by many of the same researchers using patients from the same institutions during the same time period.

Table 4. Outcomes after morcellation of an unsuspected tumor, 1980-March, 2014

Author	Year Published	Study Years	Study Design	Total Number Patients	Procedure	Cancer/Neoplasms	Outcome(s)
Morice ⁴⁶	2003	1977-1997	Retrospective cohort study	123	Morcellation versus no morcellation	Leiomyosarcoma, Endometrial stromal sarcoma Carcinosarcoma	Recurrence Disease-Free Survival Overall Survival
Park ⁴⁷	2011	1989-2010	Retrospective cohort study	56	Morcellation versus total abdominal hysterectomy	Leiomyosarcoma	Recurrence Disease-Free Survival Overall Survival
Park ⁴⁸	2011	1989-2010	Retrospective cohort study	50	Morcellation versus total abdominal hysterectomy	Endometrial stromal sarcoma	Recurrence Disease-Free Survival Overall Survival
Seidman ⁴³	2012	2005-2010	Descriptive chart review	14	Morcellation only	Leiomyosarcoma, Endometrial stromal sarcoma STUMP± Cellular leiomyoma Atypical leiomyoma	Mortality
Oduyebo ⁴⁴	2014	2005-2012	Descriptive chart review	21	Morcellation only	Leiomyosarcoma STUMP±	Recurrence Mortality
George ⁴⁹	2014	2007-2012	Retrospective cohort study	58	Morcellation versus total abdominal hysterectomy	Leiomyosarcoma	Recurrence Disease-Free Survival Overall Survival

*One patient also had ovarian cancer
± Smooth muscle Tumor of Uncertain Malignant Potential

Sarcoma Recurrence

Five studies (1 descriptive chart review, 4 cohort studies with comparison groups) examined sarcoma recurrence. In the descriptive chart review, Oduyebo⁴⁴ reported local (pelvic/abdomen) recurrence in 8/13 (61.5%) of patients whose uterine LMS had been inadvertently morcellated. In general, the 4 cohort studies found increased rates of occurrence in morcellated patients compared to those not morcellated (Table 5). All 3 of the cohort studies that reported information on any recurrence of sarcoma indicated increased odds of any recurrence in morcellated patients, although statistical significance was reached in only 1 study. The findings related to local recurrence are even more robust. Three of the four studies found a statistically significant increase in odds of local sarcoma recurrence in morcellated patients, with odds ratios ranging from 5.06 to 9.43. Morice⁴⁶ found a trend towards an increased risk of local sarcoma recurrence at 3 months, but the finding was not statistically significant.

Table 5. Risk of any and local recurrence of sarcoma

Study	Total Number of Patients	Local Recurrence (%)		Odds Ratio [‡] Local Recurrence (95% CI)	Any Recurrence (%)		Odds Ratio [‡] Any Recurrence (95% CI)
		Morcellation	No Morcellation		Morcellation	No Morcellation	
George ⁴⁹	58	12/19 (63.2)	6/39 (15.4)	9.43 (2.63-33.74) [‡]	14/19 (73.7)	20/39 (51.3)	2.66 (0.80-8.82) [‡]
Park LMS ⁴⁷	56	11/25 (44.0)	4/31 (12.9)	5.30 (1.43-19.73)	13/25(52.0)	7/31 (22.6)	3.71 (1.18-11.74)
Park ESS ⁴⁸	50	7/23 (30.4)	2/27 (7.4)	5.47 (1.04-29.70) [‡]	8/23 (34.8)	3/27 (11.1)	4.27 (0.98-18.66) [‡]
Morice ⁴⁶	123	3/34 (8.8)*	3/79 (3.6)	2.45 (0.47-12.82) [‡]	Not given	Not given	--
		3/30 (10)±	8/77 (10.4)	0.96 (0.24-3.88) [‡]	Not given	Not given	--

*Recurrence at 3 months
±Recurrence at 6 months
‡ Calculated based on data provided in the article

Disease-Free and Overall Survival

Six studies included information on disease-free and/or overall survival (two descriptive chart reviews and four cohort studies). Disease-free survival (DFS) was defined as the time from initial surgery to first

reported recurrence or date censored. Oduyebo⁴⁴ reported that during their follow up period (median 27 months), 2/4 (50%) of upstaged patients who had been morcellated died (both with LMS) compared to 1/8 (12.5%) of patients not upstaged. Seidman⁴³ reported 3/4 (75%) cases of LMS with peritoneal dissemination died, with an average post-diagnosis survival of 24.3 months. None of the non-LMS cases died during the follow up period. Findings on DFS and overall survival (OS) in the cohort studies that compared morcellation to no morcellation are included in Table 6. Three of the four studies reported statistically significantly poorer DFS in the morcellation group. With respect to OS, 1 study found statistically significantly lower overall survival in the morcellation group. Two studies reported increased odds of lower overall survival in morcellated patients, but the finding was not statistically significant, and 1 study found no difference between morcellated and non-morcellated patients.

Table 6. Disease-free (sarcoma-free) and overall survival

Study	Total Number of Patients	Follow Up Time mean/median (in months)		Disease-free Survival	Overall Survival
		Morcellation	No Morcellation		
George ⁴⁹	58	Not given	Not given	HR = 3.18 (1.5-6.8)	HR = 1.85 (0.7-4.7)
Park LMS ⁴⁷	56	39/27	63/31	OR = 2.59 (1.03-6.50)	OR = 3.07 (1.05-8.93)
Park ESS ⁴⁸	50	64/73	64/62	OR = 4.03 (1.06-15.30)	OR = 1.19 (0.15-9.2)*
Monice ⁴⁶	123	Not given	Not given	No difference between groups KM HR not given	No difference between groups. KM HR not given
HR=Hazard Ratio OR=Odds Ratio KM HR=Kaplan-Meier Hazard Ratio *Calculated based on number of deaths in morcellation group versus no morcellation group. OR was not reported in the article.					

In addition to these longer-term outcomes, compared to management of patients with Stage I uterine LMS diagnosed following TAH/BSO, patients whose LMS was morcellated are likely to undergo immediate surgical re-exploration and receive more aggressive (and more morbid) treatment possibly including intraperitoneal chemotherapy⁴⁴.

In summary, based on FDA’s analysis and review of the literature:

1. *The risk of having an unsuspected sarcoma in the population of women undergoing hysterectomy or myomectomy for presumed fibroids may be as high as approximately 1 in 350 for all types of uterine sarcomas, and 1 in 500 for LMS specifically.*
2. *Peritoneal dissemination and/or cancer upstaging (to FIGO Stage III or IV) following morcellation of an unsuspected sarcoma may occur in approximately 25-65% of cases.*
3. *Patients with unsuspected uterine sarcoma who undergo morcellation may be at significantly higher risk for local (pelvic/abdominal) and overall cancer recurrence compared to those who do not undergo morcellation.*
4. *Patients with unsuspected sarcoma who undergo morcellation may have poorer disease-free survival and overall survival compared to patients who do not receive morcellation.*

There are limitations to FDA’s analysis. First, although an attempt was made to survey the literature regarding the risk of morcellating an occult uterine sarcoma, the available literature was primarily focused on LMS. Second, because it is based on a review of the published literature, primarily of patients seen at

large clinical centers, the analysis is limited by potential publication, selection, and referral bias. To control for selection bias, the analysis of the prevalence of unsuspected sarcoma was limited to only those studies that included patients undergoing hysterectomy or myomectomy for presumed benign leiomyomas and did not include a more general patient population undergoing other gynecologic procedures. To control for differences across studies, random-effects modeling was employed for prevalence estimates. Third, there are some cases in which scalpel morcellation was used and other cases where it was not specified. Finally, the analysis is based on a relatively small number of studies, many of which included a small number of patients and statistical significance was not reached for some outcomes comparing morcellated to non-morcellated patients. In addition, the studies were not randomized so it is possible there were differences between morcellated and non-morcellated patients. It should also be noted that one study (George⁴⁹) excluded patients whose morcellation involved the use of an extraction bag (a potential mitigation strategy to limit/prevent dissemination of tissue, as discussed below in Section 4.4), whereas other studies did not specifically comment on their use. Despite these limitations, there is consistency among the findings – which point to poorer prognosis when an unsuspected sarcoma is morcellated – and the large effect-sizes found in many studies supports these findings and their relevance.

The Committee will be asked to discuss the strengths and weaknesses of the data available to assess the risk of the presence of an unsuspected uterine sarcoma in women undergoing gynecologic surgery for fibroids and the outcomes related to its morcellation. The Committee will also be asked to comment on the magnitude of the risk.

4.3.4.4 Hysterectomy and Morcellation for Benign Indications Other Than Fibroids.

FDA's analyses above focused on unsuspected malignancy in women undergoing hysterectomy or myomectomy for presumed benign fibroids. Other benign gynecological indications where hysterectomy may be performed using a laparoscopic morcellator include symptomatic uterine prolapse, abnormal bleeding, endometriosis, and adenomyosis. Several publications address the risk of malignancy in women undergoing hysterectomy for a variety of benign indications (including, but not limited to, fibroids), or for primary indications other than fibroids. Unfortunately, in many of these reports, a substantial proportion of patients had co-existing fibroid disease (even if it wasn't the primary reason for seeking surgical treatment) - making it difficult to accurately assess which events occurred in patients free of fibroids. In addition, many of the procedures reported in these publications were not performed laparoscopically and the use of morcellation was not specified.

Ouldamer performed a retrospective analysis of 2179 women undergoing hysterectomies for benign conditions at one facility¹⁹⁴. The primary indications for surgery were uterine prolapse (39%), fibroids (33%), endometriosis or adenomyosis (11%), dysfunctional uterine bleeding, infection, polyps, and cervical stenosis. Vaginal hysterectomy was performed in 63% of cases and 13% of cases involved "bivalving of the uterus in combination with myomectomy or morcellation." In the larger population of 2179 patients (including women with fibroids), 9 cancers were found, including one ESS in a 43-year old woman and one "mixed Mullerian" sarcoma in a 73-year old woman. The patient eventually diagnosed with ESS had fibroids on pre-operative imaging, had undergone vaginal hysterectomy with vaginal morcellation, and had a final diagnosis of Stage IA disease after re-staging surgery (e.g., no up-staging). She was alive without evidence of disease at 25 months. The woman diagnosed with mixed Mullerian sarcoma had a normal pre-operative ultrasound. She had abdominal morcellation as part of her initial surgery, but did not undergo re-staging. She died of disease 6 months after the initial surgery. The specific indication for hysterectomy was not noted in the publication. Within the subgroup of 853 patients being treated for prolapse (results provided separately by the author), 4 malignancies were found (0.46%). However, all were endometrial carcinomas.

Hagemann reported a retrospective case series of 101 consecutive morcellated hysterectomy specimens over a 4-year period at one institution¹⁹⁶. The indications for surgery included one or more of the following: meno/metorrhagia (56%), prolapse (32%), urinary symptoms (19%), abdominal or pelvic pain (17%). Of note, the author did not specifically call out the presence of fibroid disease as a specific indication for the surgery. However, at least 40% of patients had fibroids on pre-operative imaging and 66% had fibroids as part of the final diagnosis. No sarcomas were noted at final diagnoses.

Theban performed a retrospective chart review for 1,584 women (mean age 46) undergoing laparoscopic-assisted supracervical hysterectomy (LASH) over a 5-year period²⁰¹. Primary indications for surgery were largely fibroids (72%), but also included “bleeding disorders” (13%) and chronic pain (12%). Malignancy was diagnosed post-operatively in 4 women, including 2 cases of LMS. However, no sarcomas were detected in women without co-existing fibroids. One LMS was in a 43-year old woman where morcellation was not performed and the patient had “no evidence for recurrence” at 52 months. The other woman (age 49) did undergo power morcellation. A re-staging operation resulted in a diagnosis of Stage II disease. The patient received chemotherapy and had no evidence for recurrence at 36 months.

Saleh performed a retrospective study of 137 women (mean age 49) undergoing hysterectomy at one institution over a 2-year period for benign indications which included heavy menstrual loss (39%), fibroids (25%), abdominal pain (14%), postmenopausal bleeding (11%), and uterine prolapse (3%)¹⁹⁸. Approximately 90% of the surgeries were performed abdominally. No data on morcellation was provided. On final pathology, endometrial, cervical and/or ovarian malignancy was noted in 5% of cases; however, no uterine sarcomas were diagnosed. Fibroids were noted in 37% of cases after hysterectomy.

Ramm published a multi-center retrospective case series on 708 women who had hysterectomy for prolapse and/or incontinence¹⁹⁵. Over 80% of the cases were performed vaginally or abdominally. Four women were diagnosed with endometrial carcinoma, and one 55-year old woman (with “large” fibroids noted pre-operatively) was diagnosed with LMS on final pathology. All five women had undergone vaginal hysterectomy without mention of morcellation. No additional follow-up was provided.

Several additional reports have been published where the primary indication for surgery was specifically uterine prolapse. Hill recently published a series of 62 women undergoing robot-assisted laparoscopic surgery (hysterectomy plus sacrocolpopexy) with intra-abdominal morcellation¹⁹³. Two asymptomatic postmenopausal women (3.2%) were found to have an occult endometrial adenocarcinoma; however, no sarcomas were detected. Wan published a retrospective cohort study on 640 women (mean age of 64.2 and 86% menopausal) at one institution over a 9 year period¹⁹¹. Less than 5% of the procedures were performed laparoscopically. Uterine malignancies were found in 3 patients (0.47%), including one LMS (0.16%) in a 55 year old woman. Approximately 32% of the women had concomitant fibroids, including the woman diagnosed with LMS (8cm intramural fibroid noted pre-operatively). Morcellation was not specifically noted, and no additional patient follow-up was provided. Frick performed a retrospective analysis of pathology findings in 644 women (mean age of 59.7) who underwent surgery for prolapse¹⁹². The majority of surgeries (94%) were vaginal or abdominal hysterectomies and the percentage of patients receiving morcellation was not reported. Although two endometrial carcinomas were diagnosed, no sarcomas were found. Forty-eight percent (48%) of the overall patient population had concomitant fibroids. In a review of 372 women undergoing hysterectomy for uterine prolapse over a 10-year period, Yin found 2 endometrial adenocarcinomas¹⁹⁹. No additional details were provided. As with other studies, many women (44%) were found to have co-existing fibroid disease. Mahajan retrospectively reviewed data for 253 women (mean age of 46 and 60% postmenopausal) with uterine prolapse who underwent hysterectomy over a 2-year period at one institution in India¹⁹⁷. Incidental fibroids were noted in 30% of cases; however, no malignancies were found. Muezzinoglu evaluated incidental pathologic findings in 68 hysterectomy specimens for women with uterine prolapse over an 8-year period (mean age 60 and 92%

postmenopausal)²⁰⁰. One endometrial adenocarcinoma was found, but no sarcomas. Incidental fibroids were noted in 29% of cases.

4.3.4.5 LPM Medical Device Reports (MDRs) related to dissemination of cancer

The Manufacturer and User Facility Device Experience (MAUDE) database houses device-related adverse event reports - Medical Device Reports or MDRs- submitted to the FDA by a variety of sources. Manufacturers and importers must submit reports when they become aware of information that reasonably suggests that one of their devices *may* have caused or contributed to a death or serious injury or has malfunctioned and the malfunction of the device or a similar device that they market would be likely to cause or contribute to a death or serious injury if it were to recur. Device user facilities (e.g., hospitals, outpatient treatment facilities, nursing homes) must submit reports when they become aware of information that reasonably suggests that a device may have caused or contributed to a death or serious injury of a patient at their facility. Death reports must be sent to the FDA and the manufacturer, if known. Serious injury reports must be sent to the manufacturer or to the FDA, if the manufacturer is not known.

Through May 15, 2014, FDA has received 17 MDRs related to LPMs and intraperitoneal dissemination and/or upstaging of a uterine malignancy. Thirteen (13) of the 17 reports were received as voluntary reports. FDA received the first MDR related to this safety issue in the latter part of December 2013. However, several reports received after this time noted events which took place years earlier – with the earliest event being reported as having occurred in 2006.

For the 14 reports providing a patient age, the mean and median age was 49.7 and 51.5 respectively (range, 39-66). Approximately 43% of the reports noted events in women less than the age of 50.

LMS was the most commonly reported tumor (12). Others included ESS (2), STUMP (1), sarcoma-not specified (1), and “cancer” not specified (1). Limited other information was presented in the reports. Although all reports noted disseminated and/or metastatic disease:

- 5 reported the subsequently-determined sarcoma stage (Stage IV in four, and Stage IIIb in one).
- 3 noted the time interval from index procedure to the diagnosis of disseminated malignancy (3 weeks, 6 weeks, and 7 years).
- 5 noted subsequent therapy which the patient underwent and included chemotherapy in 4, debulking surgeries in 3, and radiation therapy in 2.
- 3 noted that the patient had subsequently died. The time from the index procedure to death was 6 months (LMS), 11 months (unknown sarcoma), and 19 months (LMS).

Although MDRs are a valuable source of information, this passive surveillance system has limitations, including the potential submission of incomplete, inaccurate, untimely, unverified, or biased data. Due to potential under-reporting of events and lack of information about frequency of device use, MDR data alone cannot be used to establish rates of events, evaluate a change in event rates over time or compare event rates between devices. The number of reports cannot be interpreted or used in isolation to reach conclusions about the existence, severity, or frequency of problems associated with devices. Confirming whether a device actually caused a specific event can be difficult based solely on information provided in a given report. Establishing a cause-and-effect relationship is especially difficult if circumstances surrounding the event have not been verified or if the device in question has not been directly evaluated.

4.4 Potential Risk Mitigation Measures for Dissemination of Malignant Tissue During Morcellation

As part of this evaluation of the risks and benefits associated with a medical device, one should consider the probability of occurrence and severity of harm and make efforts to reduce the risks appropriately. Potential risk mitigation strategies with regards to the dissemination of malignant tissue with LPMs may involve the following.

4.4.1 Device Design

FDA is not aware of any published literature that systematically analyzes the quantity and size of tissue fragments generated during hysterectomy or myomectomy with current LPMs. In the absence of this information, all currently marketed devices are considered to pose the risk of upstaging an unsuspected uterine malignancy. FDA is not aware of any current LPM design characteristics specific to the LPMs themselves which would eliminate the risk of tissue dissemination.

The panel will be asked to identify key design/performance features with respect to mitigating the risk of tissue dissemination. The panel will also be asked for recommendations regarding pre-clinical testing for LPMs to evaluate particulate generation.

4.4.2 Laparoscopic Specimen Bags

One *potential* protective measure suggested to address the risk of intraperitoneal tissue dissemination during morcellation is performing the tissue morcellation within a specimen retrieval bag - a disposable medical device used for the collection and/or extraction of tissue specimens during MIS procedures. Although most bags contain polyurethane as the inner coating, the thickness of the material, its sewing/seams, the introduction and deployment mechanisms, etc. vary from product to product⁶⁰.

The performance data needed for FDA 510(k) clearance of a laparoscopic specimen bag depends on the bag's design and may include information regarding pore size, biocompatibility, sterility, hydrostatic leak testing, burst pressure, seal strength, tensile, and puncture testing. Generally, the pass/fail criteria are based on comparisons to other legally marketed bags.

Limited data have been published regarding the performance, safety, and effectiveness of specimen bags during laparoscopic morcellation of surgical tissue. What studies are reported are small, and tend to come largely from the urological literature.

Specimen Bag Permeability

To mitigate the risk of malignant tissue dissemination during removal, a laparoscopic specimen bag must be impermeable to malignant cells. Even without power morcellation, tumor cells may be found within the bag after use. For example, Ankem reported a study in which washings from bags were obtained after 28 consecutive laparoscopic radical nephrectomy procedures for renal cell carcinoma⁵⁷. All specimens were removed *without* morcellation. In one case (a high grade, high stage tumor) the cytologic washings from within the bag were positive for malignant cells. Similarly, Meng reported on cytology washings from within specimen bags that were used in 22 consecutive laparoscopic nephrectomies performed with *manual* morcellation and noted that "malignant cells are liberated" into the bag.⁵⁶

Urban's 1993 study of specimen bags is often quoted as evidence that at least one product is impermeable to cancer cells⁵⁰. The investigators collected 24 LapSac bags (Cook) after they had been used once for renal power morcellation during a laparoscopy course. Four of the 24 demonstrated leakage and had visible pinholes (although the authors stated that they could not determine whether the pinholes were introduced before or during morcellation). Of the remaining 20 bags, 18 were separated into 3 groups for further in vitro study. One group of 6 bags was filled with suspension of 1×10^5 /mL mouse bladder tumor cells and suspended in a beaker of water for 3 hours and agitated periodically. Samples from the beakers were taken at various times for analysis. One of the 6 bags "had a single cell visible on the grid at the 1 and 3 hour reading, indicating that the concentration of cells in the dialysate was 1×10^4 cells." The bag showed no visible leakage or pinholes. The authors stated that "contamination of the dialysate likely occurred at the outset" although they gave no justification and no sample was taken at time zero for comparison. One investigator was the LapSac co-inventor and was receiving royalties.

Rassweiler published results of in vitro tests with a variety of available specimen bags (LapSac (Cook), LapBag (Bard), Extraction Bag (Karl Storz), Endobag (Dexide), Endopouch (Ethicon), Endo-Catch (US Surgical), and Espiner Bag (Ethicon))⁵¹. Bags were filled with saline, infected urine or tumor-cell suspension and digital manipulation was performed to simulate morcellation. The authors noted that all bags except the Espiner Bag proved to be impermeable to tumor cells before and after mild manipulation.

Of note, the studies by Urban and Rassweiler did not incorporate scenarios that would necessarily replicate that of direct power morcellation.

Specimen Bag Integrity

In addition to being impermeable to cancer cells, a specimen bag needs to be resistant to tears, ruptures and punctures if used to mitigate the risk of dissemination of tumor – in particular when subjected to power morcellation. Bag perforation/rupture may result from a variety of conditions at the time of laparoscopic surgery, including morcellator blades contacting the bag, frictional heat generated by the morcellator, sharp instruments/needles used during the laparoscopic procedure (including those used to introduce the bag and place the specimen in the bag), mechanical pressure exerted on the bag during morcellation, and pulling the bag through the narrow laparoscopic trocar.

Eichel assessed burst and puncture pressures in several different retrieval bags including the LapSac (Cook), Endopouch (Ethicon Endosurgery), Endo-Catch (US Surgical), Endo-Catch II (US Surgical), Endo-Catch Gold (US Surgical), and a 1-quart Ziploc bag (SC Johnson)⁵³. The LapSac is made of Nylon coated with polyurethane and the others are made from polyurethane. Bursting tension was a measure of the force necessary to pull the bag filled with a 25 mm ball through a 20 mm diameter hole. Mean bursting tensions varied substantially between products (118 pounds to under 46 pounds). Puncture pressure was evaluated using a 16.5 mm Kelly clamp and a pair of ring forceps. The mean resistance to puncture with clamp or forceps also varied between bags (43.5 pounds to under 15 pounds). The authors noted that the LapSac provided the highest burst tension and puncture resistance. One investigator was the co-inventor of the LapSac and was receiving royalties from Cook at the time.

Rassweiler⁵¹ measured tear forces needed to cause bag rupture (using water pressure) in a variety of products (as noted above). Resistance to tear forces varied greatly among the bags, ranging from 75 N/mm^2 to less than 30 N/mm^2 .

While the studies by Eichel and Rassweiler provide some important information on the mechanical strength of the devices, and how they can vary, they did not directly address the compatibility of bags

with LPMs. One study by Cai⁵² did evaluate bag performance while performing in vitro morcellation of porcine kidneys in a “pelvic trainer” under 3 different scenarios.

- Group 1 (n=10): electrical morcellation performed within fluid filled LapSac under direct visualization with the aid of a nephroscope placed *inside* the bag.
- Group 2 (n=10): electrical morcellation performed within fluid filled LapSac, monitored by laparoscopic visualization *outside* the bag.
- Group 3 (n=10): manual morcellation using ring forceps with the mouth of the LapSac being brought to the body surface through a port site (and monitoring via laparoscopic camera).

The LapSacs were assessed after each trial. One pinhole perforation was noted in Group 1, nine perforations in Group 2 (5 large, 4 pinhole), and none in Group 3. The investigators reported that the mean time for manual morcellation (Group 3) was 15.1 minutes, compared to 86.9 minutes in Group 1 and 47.1 minutes in Group 2. The mean fragment size was 1.36 grams in Group 3 and <0.02 grams in the others. The authors suggest that the larger tissue fragment size generated by manual morcellation may be advantageous as it could aid in diagnosis and staging of the specimen. It should be noted that the morcellator used in this study was the Coherent electrical prostate morcellator (EPM) which is not indicated for gynecologic use and is intended for use in a fluid medium.

Parekh also performed in-vitro evaluations of tissue morcellation within bags⁵⁴. Using the Karl Storz Steiner Morcellator, the investigators morcellated pig kidneys within a dry (n=2) or fluid-filled (n=2) LapSac and noted no perforations with the fluid filled bags, but 8 perforations in one of the two dry bags, leading to gross tissue spillage.

Cohen recently published a manuscript of a pilot study using 4-5 gram beef tongue specimens to simulate contained morcellation of uterine tissue in an enclosed laparoscopic box trainer which was a plastic storage bin modified with a PVC liner on top to simulate the abdominal wall¹⁸². The tongues were dyed with indigo carmine and placed in a specimen bag (3M Steri-Drape by 3M or TRS200 by Anchor). The bag was then placed in the trainer and the opening brought out through a defect in the anterior wall, simulating a laparoscopic access site. For the trials simulating a multi-port approach, a trocar was then inserted into the opening of the bag and the bag was insufflated. Once the bag was insufflated, a balloon-tipped trocar was placed into the bag under direct vision. The laparoscope was replaced at the lateral port as well, and a 15mm morcellator (RotoCut G1, Karl Storz) was inserted into the bag. Morcellation was performed under laparoscopic guidance and at the end, the bag was removed via the access site on the anterior aspect of the box trainer. In the single-site approach, the above technique was modified by placing a GelPoint access device (Applied Medical) at the defect in trainer. The bag was then exteriorized around the base of the device and the access port was re-sealed. The bag was insufflated as above and morcellator was inserted through the access device. The laparoscope introduced via a separate site and morcellation performed under laparoscopic guidance. Four trials were performed with each bag type using a multi-port approach. Four trials were also performed with the 3M bag and a single-site technique. All physicians were experienced MIS surgeons. Bags were evaluated for integrity and signs of tissue or dye spillage. The box trainers were also inspected and rinsed with saline for cytologic evaluation. The investigators noted no gross spillage of tissue chips and all bags were visually intact aside from a single puncture site with the multi-port approach. Blue dye spill occurred in one of the trials. In this case, spillage was noted from a seam of the Anchor bag prior to morcellating, but after insufflation. Cytologic examination revealed muscle cells from the trial with visible dye spill. Washings were otherwise negative for the other in-bag morcellation samples. The authors concluded that the use of larger bags and continuous laparoscopic monitoring may provide additional safety measures, and that containment systems may effectively decrease or potentially eradicate tissue spillage as compared to the traditional open morcellation technique.

It should be noted that not all bag perforations are immediately visible to the naked eye. Cleaning, drying and assessing for leakage with a product such as indigo carmine may reveal small defects.⁵⁵

In addition to the mechanical issues noted above, the use of such bags during laparoscopic surgeries may present the potential to obscure the physician's view of the anatomy and surgical instruments.

In terms of laparoscopic specimen bags, FDA has received over 1,000 MDRs between January 2004 and March 2014 for use during a variety of laparoscopic surgeries including, but not limited to, gynecologic procedures. Due to the inherent limitations associated with a passive reporting system (as noted above), a brief qualitative, rather than quantitative, assessment of the MDRs was performed for inclusion in the Executive Summary. The most common organs being removed in a bag were the gall bladder and appendix. Others included kidneys, adrenal gland, spleen, lung lobes, ovaries, uterus, bowel, and prostate. By far, the most common type of event reported to FDA was the disruption/breakage of the bag – often during withdrawal of the bag and its contents through the trocar or incision. Release of the tissue and/or pieces of the bag into the peritoneal or abdominal cavity was noted in some reports and may have resulted in prolonged procedure time to retrieve the tissue or bag fragments. In these cases, additional steps may have been required to complete the procedure, including expanding the length of the port incision. Other events included difficulties opening, deploying, or closing the bag, bag disconnections from the supporting handle, and the bag getting stuck in the trocar. Only 3 MDRs specifically mentioned morcellation. In all 3, there was morcellation of a spleen within a bag, and it resulted in the morcellator damaging the bag followed by injury to local vascular structures (aorta, vena cava) and/or bowel. Four other bag MDRs specially mentioned malignancy in the event description. In all reports, the bag malfunctioned (e.g., broke or didn't open/close properly) during retrieval of the specimen (presumed or known to contain malignancy). In two of the 4 reports, this resulted in release of the contents into the abdominal cavity. No further patient outcome data was available. However, it should be noted that none of these 4 reports noted whether morcellation was performed.

The panel will be asked to discuss available information on use of laparoscopic specimen bags to effectively contain benign and/or cancerous tissue during laparoscopic surgery, and morcellation, and whether this information supports use of specimen bags as a mitigation for the risk of disseminating and/or upstaging an unsuspected malignancy. The panel will also be asked for input regarding pre-clinical testing for evaluating specimen bags and demonstrating compatibility with LPMs and to discuss specimen bag labeling.

4.4.3 Surgical Technique

The literature includes some recent discussion regarding surgical techniques which have been suggested to potentially assist in mitigating the risk of tissue dissemination during laparoscopic surgery, but still maintain some/all the benefits of MIS.

En-Bloc Resection

Performing a hysterectomy or myomectomy laparoscopically but extracting the specimen intact (en bloc, without morcellation) would seemingly reduce the risk of dissemination of tissue within the intraperitoneal cavity while also preserving specimen architecture, which in turn may allow for more accurate histopathological evaluation and/or staging. Options to remove a specimen intact may include the employment of:

- Minilaparotomy

- A surgically enlarged ancillary port
- Transvaginal extraction (TVE).

TVE through a posterior colpotomy, with or without the use of a specimen bag, has been described as a safe and effective way to remove an intact surgical specimen during MIS^{175,177}. Elasticity of the vaginal walls may allow for large specimens to be extracted while avoiding the need to enlarge an abdominal port (which may increase complications such as port-site hernias) and/or morcellate. If morcellation is required, it could be performed within the vaginal vault – reducing the risk of tumor spillage into the peritoneal cavity (See Morcellation Modifications below). The use of specimen bags has been described with this type of procedure. The bag can be inserted into the peritoneal space laparoscopically or vaginally. Introduction of a specimen bag via the vagina may allow a bigger bag to be introduced. It may also allow the bag to be introduced unfolded and in an orientation which facilitates organ insertion. Some however have noted that the vagina is non-sterile, and that such placement may cause loss of pneumoperitoneum¹⁹⁰. Concerns about TVE in general have included potential for postoperative dyspareunia, vaginal dehiscence, pelvic infection, and future fertility.¹⁷⁵

Morcellation Modifications

Several recent publications have suggested methods to perform uterine or fibroid morcellation which may reduce the risks of intraperitoneal tissue dissemination.

In 2011, Serur published a technique for the removal of larger uteri during laparoscopic hysterectomies in which the specimen is too large to be extracted vaginally¹⁷³. An Endo Catch II bag (Covidien) is inserted through the 10mm port site and opened intra-abdominally. The uterus is placed into the bag and the port incision is extended to 2-3cm so that the edge of the bag can be brought up through the incision. The uterus is circumferentially cored with a scalpel (manual morcellation) extracorporeally. The author concludes that “because the specimen is elevated above the abdominal incision before it is cut up, there is no risk for intraabdominal injury from morcellator blades or for spillage” and that “theoretically, any spillage during extraction of the bag would occur outside the body, preventing contamination of the pelvic cavity.”

Einarsson recently published a surgical technique for “in bag morcellation (IBM)” for laparoscopic gynecologic surgeries¹⁸³. For smaller specimens, the author uses a 15mm trocar placed through the umbilicus to introduce an EndoCatch bag (Covidien). The specimen is placed inside the bag under direct visualization and the bag is closed, and brought out through the umbilicus until approximately 2 cm of the bag is outside of the abdomen. The bag is opened, and a 12-mm trocar inserted into the bag and connected to insufflation tubing to inflate the bag. A 5-mm laparoscope is placed through the left lower quadrant trocar, and the left upper lateral trocar is placed through the bag under direct visualization. Once this latter trocar is inside the bag, insufflation tubing and the laparoscope are moved to this site, the trocar is removed from the umbilicus, and a morcellator is placed in the inflated bag under endoscopic guidance. Morcellation takes place under direct visualization, after which the bag is retrieved through the umbilical port. For larger specimens (>8cm), the author uses an Anchor TRS-200 bag (Anchor Surgical) inserted through a 15-mm trocar. The edges of the bag are pulled over the specimen and outside the abdomen. The umbilical trocar is reinserted inside the bag and the bag is insufflated. The upper end of the bag is then pierced with a 5-mm extra long (15 cm) balloon-tip trocar under direct visualization. The insufflation tubing is moved to the left upper peripheral port, and the umbilical trocar is removed. The morcellator is then placed at the umbilicus and morcellation performed – keeping the blade in view at all times. After morcellation, the bag is retrieved through the umbilical port. The authors used these

techniques in 15 procedures from February 28 to April 2, 2014 (8 EndoCatch, 7 Anchor), including 2 TLH, 9 laparoscopic supracervical hysterectomies, and 4 laparoscopic myomectomies. Mean procedure time was 134 minutes, average blood loss was 125 mL, and mean specimen weight was 262 g. The time to place the specimen in the bag generally ranged from 3-20 minutes. There were no intraoperative complications, bag ruptures, conversions to laparotomy, or readmissions.

When performing laparoscopic myomectomy with an LPM, Landy¹⁶⁹ recommends activating the morcellator blade inside a trocar with an oblique end – suggesting that this may prevent the loss of fragments into the pelvis. The author also recommends irrigating the peritoneal cavity with Ringer lactate at the end of the procedure to remove any fragments that may have been lost.

Several other investigators recommend vaginal morcellation (albeit manual morcellation in several instances) as an alternative to intraperitoneal morcellation or the techniques suggested above for tissue extraction following laparoscopic surgery. This includes reports of removal of cancerous tissue.

Montella recently reported on a pilot study of 12 patients with endometrial cancer (sarcomas excluded) and uteri larger than 12 weeks gestational age who were treated via laparoscopy and vaginal tissue morcellation/extraction¹⁷⁹. After performing laparoscopic hysterectomy, a “sterile plastic wrapping” bag was inserted through a 12 mm port and the uterus covered from the fundus to the cervix. The specimen was then pushed down under direct visualization through a colpotomy, and pulled into the vaginal canal-automatically covering the vulvar region and vaginal walls. The uterus could then be opened/divided with longitudinal morcellation, and extracted by the vaginal route. No conversions to open laparotomy were required, and no bag disruptions were noted. All patients were free from local or distal recurrence at a median follow-up of 18 months.

Favero reported on a pilot study of 8 women scheduled for total laparoscopic hysterectomy for endometrial cancer in which uterus removal was a concern due to size/proportionality and in which vaginal morcellation was performed¹⁷⁶. The investigator used a 5-port laparoscopic procedure and inserted the surgical specimen into a LapSac bag (Cook). The bag was closed, rotated and pushed into the vaginal canal. The edges of the bag were pulled up to the vaginal introitus and the bag opened. Inside the opened pouch, two retractors were placed to retract the anterior and posterior vaginal walls and the cervix was grasped. If needed, the surgeon could morcellate the uterus inside the bag. The authors describe manual morcellation (uterus bisection with a scalpel). In the series of 8 patients there were no intraoperative complications or conversion to laparotomy (although one patient later presented with a vesicovaginal fistula). The mean additional operative time related to vaginal morcellation was approximately 13 minutes. The author states that because the procedure is assisted by laparoscopy, the risk for intra-abdominal injuries during morcellation can be reduced as can the chances of inadvertent bag rupture or incision. The authors also note that any “tissue spillage during the uterus extraction would occur only outside the body, preventing contamination of the abdominal cavity.”

TVE has also been used for large uteri. Ucella recently reported on a series of 71 women with uteri ≥ 1 kg in which laparoscopic hysterectomy with vaginal morcellation was performed for fibroid disease¹⁸⁰. The authors use a 4-port standard technique. Once devascularization of the uterus is achieved, circular colpotomy with a monopolar knife is performed. Morcellation is then accomplished transvaginally using tenacula, clamps, and scissors. In cases of a narrow vagina, a 10-mm laparoscopic morcellator is inserted in an ancillary trocar. Of the 71 women in the series, 4.2% required conversion to an open procedure, and the use of a power morcellator was only required in 5.6% of cases. Two postoperative complications were noted (vaginal bleeding, vaginal cuff hematoma).

Bogani recently submitted a manuscript describing a retrospective propensity-matched analysis of prospectively collected data, comparing outcomes of power morcellation (with transabdominal extraction) versus TVE for fibroids following laparoscopic myomectomy¹⁸¹. In patients undergoing fibroid morcellation, a 5-mm lateral ancillary port was converted to 12-mm for the insertion of a power morcellator (ROTOCUT G1, Karl Storz). In patients undergoing TVE, the specimen retrieval device was introduced through the vagina and pushed on the posterior vaginal wall in order to identify the posterior vaginal fornix. Under laparoscopic view, 1-2cm transverse colpotomy was performed. Grasping the bag orifice with ring forceps through the colpotomy, the specimen was then pulled into the vagina. The bag orifice was opened inside the vaginal canal and the specimen was delivered through the vagina. If needed, fibroids were morcellated within the bag. The colpotomy was then closed trans-vaginally. Fifty propensity-matched patient pairs (100 patients) were evaluated. No significant differences were observed in baseline patient characteristics between groups after propensity score matching including dominant fibroid diameter and total fibroid weight. Although overall operative times were similar between groups, the time for specimen retrieval was lower with TVE (5 vs. 7 min). No intraoperative complications occurred. At 30-day follow-up no trocar site hernia, pelvic infections, vaginal dehiscence nor iatrogenic parasitic myoma occurred.

Although several benefits to vaginal morcellation have been proposed, some limitations may include inadvertently incorporating or damaging nearby organs, such as the bowel or bladder if improperly grasping the specimen, and tearing or laceration of the specimen while attempting to remove the specimen through the colpotomy incision. This may be more problematic in nulliparous and morbidly obese patients¹⁷⁷.

In addition to the data above, the urological literature provides several recommendations and caveats with respect to laparoscopic morcellation of renal tissue¹⁷⁰⁻¹⁷². In addition to the technique described by Serur above, these include:

- Triple draping of the bag to prevent contamination (especially when dealing with a renal malignancy): a towel drape, sticky drape and nephrostomy drape are commonly used.
- The need for the morcellating surgeon and assistants to re-gown and re-glove at the end of the morcellation procedure and before proceeding with the rest of the operation.
- Bathing the extraction site in povidone-iodine to reduce the likelihood of wound seeding
- Use of only atraumatic instruments for bag/specimen manipulation, and only under direct vision
- Caution against use of morcellation in patients with ascites to avoid port site recurrence

The panel will be asked to discuss whether there are surgical techniques for performing uterine power morcellation that adequately mitigate the risk of intraperitoneal dissemination of tissue.

4.4.4 Labeling/Training

Other risk mitigation strategies may include proper labeling and training. A table summarizing some of the key safety information included in the labeling for LPMs with a gynecologic indication are included in Appendix E. While labeling mitigations can be appropriate, a review of the current labeling highlights a number of inconsistencies/inadequacies regarding the risks associated with LPM's including:

- Currently marketed LPMs that include a gynecologic indication do not include any specific information on the risks associated with morcellating an unsuspected uterine malignancy
- Currently marketed LPMs with a gynecologic indication do not include information on the risk of "parasitic" myoma or dissemination of benign tissue.

- Labeling across manufacturers of LPMs is inconsistent with respect to the use of the device in malignant tissue or tissue suspected of being malignant.
- Labeling across manufacturers of LPMs is inconsistent with respect to the use of the device with a specimen bag.
- Labeling across manufacturers of LPMs is inconsistent with respect to the risk of injury to non-target tissue and the need for direct visualization, maintaining a pneumoperitoneum and exercising care during the insertion and removal of the device.
- There is only one currently marketed LPM with a gynecologic indication which includes a statement to determine prior to each procedure whether an endoscopic approach is preferable to a conventional approach.

The panel will be asked to provide recommendations on LPM labeling (including instructions/directions for use) to specifically address use in women with fibroids and in women with known or suspected gynecologic malignancy.

5 Conclusion

In summary, the use of laparoscopic power morcellators for gynecologic indications presents benefits and risks. As LPMs facilitate the performance and accomplishment of minimally invasive surgeries, potential benefits include less post-operative pain, shorter recovery time, shorter hospital stay, and fewer wound site infections. Risks of LPMs include injury to local tissues and organs, dissemination of benign tissue, and dissemination of malignant tissue. The dissemination of unsuspected malignant uterine tissue within the intraperitoneal cavity during laparoscopic surgery for presumed fibroids represents a serious concern and is the focus of this Advisory Committee meeting. Several *potential* strategies have been suggested or may be considered to reduce the risk of this event including modifications to device design, the use of laparoscopic specimen bags as containment systems, variations in surgical technique, and changes to labeling and directions for use. The Advisory Committee will be asked to deliberate on these issues, and provide scientifically-based recommendations to FDA regarding the risks and clinical utility of LPMs for women undergoing laparoscopic hysterectomy/myomectomy, potential risk mitigation steps for the dissemination of unsuspected malignant tissue during laparoscopic power morcellation, and the benefit-risk profile of power morcellation if/when those mitigation strategies are incorporated.

6 Appendices

Appendix A: April 2014 FDA Safety Communication



Appendix B: Overview of Uterine Sarcomas

Leiomyosarcoma (LMS)^{59,61-66, 70, 72-74, 76,77, 164}

Leiomyosarcomas (LMS) account for 1-2% of uterine malignancies. Most occur in women over 40 years of age, with the median age at diagnosis being close to 50. The age-adjusted incidence rates of leiomyosarcoma for women ≥ 35 per 100,000 US population based on nine SEER registries 1989-1999 was 0.917 for white non-Hispanic vs. 1.511 for African-American women. The more common presenting signs/symptoms include abnormal vaginal bleeding, pelvic pain, and/or pelvic mass. Unfortunately, these symptoms often mimic or overlap those seen with benign leiomyomas, and LMS is commonly diagnosed pathologically after hysterectomy/myomectomy.

At the time of diagnosis, most women have disease limited to the uterus. When spreading, LMS tends to do so hematogenously rather than by local growth. Regional lymph node (LN) positivity and distant metastases (e.g., lungs) are uncommon ($\leq 10\%$) at the time of diagnosis.

Hysterectomy with bilateral salpingo-oophorectomy (BSO) is the standard treatment for confined LMS. However, ovarian preservation is sometimes considered for pre-menopausal women with localized disease and no macroscopic evidence of ovarian involvement. Due to infrequent LN involvement, LN dissection is not typically performed unless macroscopic or extrauterine disease is noted during surgery. The use of adjuvant therapy is not well defined for LMS. Adjuvant radiotherapy may control local recurrence but has not been shown to improve survival. As LMS is more likely to spread hematogenously, radiation therapy is usually not given to women with Stage I or II disease after complete resection. For higher stage cancers, there may be a role for radiation in order to control local disease. For advanced or recurrent disease, adjuvant chemotherapy with agents such as doxorubicin, docetaxel plus gemcitabine, or hormonal therapy may be used.

Prognosis for LMS is poor, even when diagnosed at an early stage. Factors which impact prognosis include tumor size, mitotic index on pathology (index > 10 mitoses/HPF have worse prognosis), age at diagnosis, and the presence of residual tumor after surgery. Complications associated with treating LMS not cured by hysterectomy can include need for subsequent (sometimes multiple) tumor debulking surgery and attendant surgical complications, and toxicities associated with chemotherapy. High rates of relapse (up to 70%) are seen, even if the tumor is caught at an early stage and completely resected. Five year survival (5-YS) is approximately 50% for patients with Stage I disease and 25% for Stage II. Patients diagnosed with Stage IV disease do not typically live beyond 2 years. (Note: some publications quote 5-YS of 60% for Stage I and 15% for Stage IV. That data was based on women diagnosed with sarcomas from 1988 to 2001 and newer staging paradigms have been introduced)

Endometrial stromal sarcomas^{62-66, 68, 70, 72-74}

Endometrial stromal sarcomas (ESS) are low-grade, indolent tumors which account for 0.2% of uterine malignancies and are typically diagnosed in women aged 40-55. Potential risk factors include polycystic ovary syndrome, unopposed estrogen exposure, and long-term tamoxifen use. Abnormal uterine bleeding may be seen in up to 90% of women. Pelvic pain and dysmenorrhea are also common. However, up to 25% of women may be asymptomatic. As ESS may involve the endometrium, endometrial sampling may be more likely to be positive during work-up when compared to other types of uterine sarcomas.

As ESS are sensitive to hormones, hysterectomy plus BSO is considered the standard treatment. Some advocate ovarian sparing for premenopausal women with Stage I disease. However, these patients may

have significantly increased recurrence rates. LN dissection is not usually recommended unless extra-uterine disease or gross LN involvement is seen. Stage I/II patients usually do not receive adjuvant therapy. In advanced disease (Stage III/IV) or recurrent disease, adjuvant endocrine therapy (progestational agents, aromatase inhibitors) can be considered.

ESS are indolent tumors which generally have a more favorable prognosis compared to other uterine sarcomas. Prognosis is largely dependent on the stage at diagnosis but may also be impacted by age, resection margin status, and menopausal status. Disease recurrence is seen in 25-50% with early stage disease and is usually in the pelvis/abdomen, but may also occur in the chest. Recurrence can be late – sometimes decades after the initial diagnosis. For Stage I disease, 5-YR is typically >85-90% and for Stage II, approximately 60%.

Undifferentiated uterine sarcomas^{62,63,66,70}

Undifferentiated uterine sarcomas, formerly called “high-grade endometrial stromal sarcomas” are rare but very aggressive tumors which usually are first diagnosed in postmenopausal women. Although hysterectomy and BSO with or without adjuvant XRT or chemotherapy is the standard for treatment if diagnosed early, half of women present with Stage IV disease, and most patients die within 2 years of diagnosis. Prognosis is impacted by several factors including tumor extent, vascular invasion, nuclear uniformity, and lymph node involvement. Local recurrences and distal metastases are common and may occur as early as 6 months after primary treatment. The 5-YR for patients with Stage I disease overall is 57%, although vascular invasion portends a poorer survival (e.g., 5-YR of 17%).

Adenosarcoma^{62,66,70,74}

Adenosarcomas of the uterus are typically found in postmenopausal women and present with abnormal uterine bleeding. The disease tends to present at an early stage, confined to the uterus. LN spread and distant metastases are uncommon. Treatment is usually hysterectomy plus BSO. Vaginal or pelvic recurrences are seen in 25-30% within 5 years and factors which are associated with an increased risk of recurrence include extra-uterine spread at diagnosis, deep myometrial invasion, and sarcomatous overgrowth. Patients with Stage I disease may have a 5-YR of 75%.

Carcinosarcomas^{62,63,70-74}

Carcinosarcomas (CS) are often referred to as “Malignant mixed Mullerian Tumors (MMMT)” and are typically diagnosed in post-menopausal women (median age in mid-60s). Risk factors include advanced age, obesity, exposure to exogenous estrogens, and a history of pelvic irradiation. Abnormal vaginal bleeding, uterine enlargement, and abdominal pain are common presenting symptoms and serum CA-125 levels may be elevated.

CS are highly aggressive tumors, and at presentation, 33%-45% have extra-uterine spread (Stage III/IV) - commonly to the adnexa, LNs, and peritoneal surfaces. Up to 29% of women presumed to have early disease will have positive peritoneal washings. Hematogenous spread may occur to lungs, liver, and bone. This type of tumor also has a high rate of recurrence (50-60%) for both local and distant sites.

Due to the higher percentages of extra-uterine and LN disease seen, even with early stage disease, hysterectomy plus BSO, regional lymphadenectomy, and omentectomy are the first-line therapy for CS. Post-operative radiation therapy decreases the rate of pelvic recurrences but does not improve survival. Adjuvant combination chemotherapy can improve survival in early stages and sequential multimodality

therapy (adjuvant combination chemotherapy followed by pelvic radiation) can potentially provide survival benefits – in particular for Stage III/IV disease.

Prognosis is largely dependent on surgical stage and depth of myometrial invasion. Poorer prognoses are seen with non-Whites and patients over >40. The 5-YS may approach 50% in Stage I, and be as low as 10% for Stage IV.

Sarcoma Staging

(1) Leiomyosarcomas	
Stage	Definition
I	Tumor limited to uterus
IA	<5 cm
IB	>5 cm
II	Tumor extends to the pelvis
IIA	Adnexal involvement
IIB	Tumor extends to extrauterine pelvic tissue
III	Tumor invades abdominal tissues (not just protruding into the abdomen).
IIIA	One site
IIIB	> one site
IIIC	Metastasis to pelvic and/or para-aortic lymph nodes
IV	Tumor invades bladder and/or rectum
IVB	Distant metastasis
(2) Endometrial stromal sarcomas (ESS) and adenosarcomas*	
Stage	Definition
I	Tumor limited to uterus
IA	Tumor limited to endometrium/endocervix with no myometrial invasion
IB	Less than or equal to half myometrial invasion
IC	More than half myometrial invasion
II	Tumor extends to the pelvis
IIA	Adnexal involvement
IIB	Tumor extends to extrauterine pelvic tissue
III	Tumor invades abdominal tissues (not just protruding into the abdomen).
IIIA	One site
IIIB	> one site
IIIC	Metastasis to pelvic and/or para-aortic lymph nodes
IV	Tumor invades bladder and/or rectum
IVB	Distant metastasis
(3) Carcinosarcomas	
Carcinosarcomas should be staged as carcinomas of the endometrium.	

The panel will be asked to discuss any patient/fibroid characteristics or pre-operative exam findings that may be predictive of malignancy.

Appendix C: Diagnostic Considerations for Uterine Fibroids and Sarcomas

Please note: This Appendix contains information related to diagnostic considerations for both uterine fibroids and uterine sarcomas, and when relevant, differentiating between the two.

Physical Exam

Clinically significant fibroids can often be detected on bimanual pelvic exam – usually manifesting as an enlarged, irregularly shaped uterus. Typically, the relative size of a fibroid or set of fibroids is expressed in terms of the uterine size in gestational weeks. A uterus greater than 12 weeks in size may be palpated on abdominal exam.³ Physical exam cannot differentiate a benign from malignant process.

Changes in Lesion Size

It has been suggested that changes in uterine or uterine mass size during pre-operative administration of GnRH agonists may assist in differentiating a benign from malignant process as a uterine fibroid is expected to shrink in response to the drug, whereas sarcomas would not. However, the data surrounding this notion are lacking and numerous case reports exist where, in response to GnRH agonist administration, there were initial reductions in the size of the uterus and mass in patients ultimately diagnosed with a sarcoma.¹⁸⁶⁻¹⁸⁸

Likewise, it has been suggested that *rapidly* growing uterine lesions (especially larger lesions) may indicate the presence of a uterine malignancy. Although a growing mass in a postmenopausal woman may be reason to suspect a potential malignancy, benign fibroids can also have variable rates of growth over time. As discussed in Section 3.2.1 (Expectant Management), the natural history of fibroids with respect to growth/regression is unpredictable and can be quite variable – even over a short period of time. In addition, in a review of 1332 charts for women undergoing surgery for fibroids Parker¹⁸⁵ reported an incidence of sarcoma of 0.27% in women who had “rapidly growing fibroid” as part of the indication for surgery. This was not statistically different from the overall incidence reported (0.23%).

Serum Biomarkers

According to the 1998 NIH Biomarkers Definitions Working Group, a biomarker is “a characteristic that is objectively measured and evaluated as an indicator of normal biological processes, pathogenic processes, or pharmacologic responses to a therapeutic intervention” and can be “measured accurately and reproducibly.”⁷⁸ Several potential serum biomarkers have been evaluated for the diagnosis of fibroids¹⁶ and/or differentiation from malignancies, including but not limited to:

- *Prolactin*: In a small case-control study of 32 patients and 30 controls, Babab⁷⁹ reported that patients with uterine fibroids had elevated levels of serum prolactin compared to controls and that levels post-operatively declined. Eighty-four percent (84%) of women with fibroids met the definition of an elevated prolactin level. Patients with malignant uterine lesions were not included in the study.
- *Lactate Dehydrogenase (LDH)*: Koukourakis⁸¹ evaluated total serum LDH activity and tissue isoenzyme LDH₅ in patients with gynecological malignancies and benign diseases and reported higher LDH levels in patients with fibroids compared to healthy controls (310 IU/L vs 256 IU/L); however, levels were intermediate between healthy controls and patients with various gynecological malignancies such as endometrial adenocarcinoma (349), ovarian cystadeno-carcinoma (383), and breast cancer (328). Goto⁸² assessed serum total LDH and

isozymes in patients with leiomyosarcoma (LMS) or degenerated leiomyoma. Total LDH had a sensitivity and negative predictive value (NPV) of 100% for determining LMS, but a specificity of 88% and a positive predictive value (PPV) of 38%. An elevated LDH₄ was the only isozyme with a sensitivity and specificity above 90% (90% and 92% respectively).

The fact that there are multiple metabolic issues besides malignancy which may impact serum LDH levels reduces its utility as a stand-alone biomarker. As such, there has been interest in the value of combining LDH with other diagnostic tests, including magnetic resonance imaging (MRI), to differentiate benign and malignant lesions (see *MRI* below).

- *Cancer Antigen-125 (CA-125)*: Junag⁸³ studied 42 consecutive patients with LMS and 84 with fibroids (control) and found that although preoperative serum CA-125 were significantly higher in the LMS group, there was significant overlap between leiomyomas and early LMS.

Kim⁸⁴ also noted higher CA-125 levels in sarcoma patients compared to fibroid controls (184.8 U/ml vs 89.2 U/mL). A cut-off of > 27.5 U/mL resulted in a sensitivity of 52.3%, specificity of 50.5%, PPV of 15.1% and NPV of 86.5% for LMS.

Yilmaz⁸⁵ retrospectively evaluated 2,382 women who underwent surgery for fibroids and 26 women diagnosed with uterine sarcoma during the same time and concluded that the preoperative CA-125 levels were not predictive of sarcoma and that there was no association between staging and CA-125 in uterine sarcomas

CA-125 can also be elevated in benign conditions including endometriosis, pelvic inflammatory disease, and liver disease

- *Neutrophil to Lymphocyte Ration (NLR)* : Kim⁸⁴ reviewed data on 55 patients who were diagnosed with uterine sarcomas and 165 matched controls with fibroids or adenomyosis. Mean NLR for sarcoma patients was significantly higher than that for women with fibroids (4.59 vs 2.05). An NLR with a cut-off of ≥ 2.12 was found to have a sensitivity of 74.5%, specificity of 70.3%, PPV of 29.5% and NPV of 94.3%.
- *Growth Differentiation Factor-15 (GDF-15)*: GDF-15 has been identified as a potential biomarker for gynecological malignancies. Trovik⁸⁶ evaluated pre-operative levels from 19 patients with uterine sarcoma, 50 with uterine fibroids, and 40 healthy controls. Although median levels were elevated in sarcoma patients compared to fibroid patients or healthy women (943 vs 647 vs 363ng/L), there was significant overlap between the groups. The authors also reported that GDF-15 levels tended to be higher in women with metastatic disease, large tumors (≥ 10 cm), and leiomyosarcomas.

In summary, to date, no serum biomarker has proven effective at reliably differentiating fibroids from uterine malignancies.

Biopsies and Cytology

For women with abnormal uterine bleeding, a diagnostic work-up includes endometrial sampling. Even if a uterine fibroid or sarcoma is present and contributing to the patient's symptoms, endometrial sampling biopsies may not provide the correct diagnosis unless the lesion has reached the surface of the endometrial cavity.⁶⁹ Leibsohn³⁵ undertook a retrospective review of 1432 patients who had been

referred for a hysterectomy because of symptomatic fibroids or a mass thought to be a fibroid. Of 10 patients whose final diagnosis was LMS, eight had a preoperative endometrial biopsy or curettage performed and the diagnosis of LMS was made in only three (37.5%) of those patients. Bansal⁸⁷ reported on a cohort who had been diagnosed with a uterine cancer at the time of hysterectomy and who had had preoperative endometrial sampling. Among the women diagnosed with sarcomas (n=72), endometrial sampling predicted the correct histologic diagnosis in 59% of patients with CS, 67% of patients with LMS, and 53% for other sarcomas. Epithelial malignancies were correctly predicted in 81% of cases.

Directed mass biopsies may provide useful information, but are not routinely done. Kawamura⁸⁸ reported on 453 patients who underwent transcervical needle biopsies of suspected myomas. Of these, 141 underwent surgery, providing a pathological diagnosis, which included 6 sarcomas. The authors applied a histopathological criteria to the biopsy specimens using 3 parameters (mitotic index, cytologic atypia, and coagulative tumor cell necrosis) each of which were evaluated on a 3-point scale (0, 1, or 2 points). Using a cut-off of 2, the sensitivity, specificity, PPV and NPV values were 100%, 98.6%, 58%, and 100.0% respectively for the determination of malignancy.

Although cervical cytology is essential in the evaluation of abnormal uterine bleeding, its utility in diagnosing endometrial and myometrial abnormalities is very limited.³⁵

Ultrasound (US)^{89,90}

Ultrasound, in particular transvaginal ultrasound (TVUS), is often a first-line imaging modality to evaluate suspected uterine fibroids and can detect fibroids down to 5mm. Fibroids frequently appear as symmetrical, well-defined, hypoechoic, and heterogeneous masses. Areas of calcification or hemorrhage may appear hyperechoic, and cystic degeneration may appear anechoic. Circumferential (peripheral) vascularity is often seen on Doppler color flow (unless necrotic) as are high flow rates. Some limitations of US include the user's inability to accurately determine the number and/or position of the fibroids and differentiate fibroids from malignant tumors. In addition, its use is highly operator-dependent.

Several studies have evaluated the performance of TVUS for the detection of *submucosal* fibroids compared to sonohysterography (see below) and/or direct hysteroscopy (see below) – using histological diagnosis from hysteroscopy or hysterectomy as confirmation of the presence/absence of a fibroid.⁹⁰⁻⁹² Sensitivity of TVUS ranged from 86-95%, specificity from 74-99%, PPV 33-96%, and NPV 97-98%.

Levens evaluated TVUS performance (against MRI) in a population where the majority of fibroids (87%) were *intramural and subserosal*.¹²⁷ Premenopausal women with symptomatic fibroids scheduled for hysterectomy underwent both US and MRI imaging within 2 weeks prior to surgery. A total of 151 surgically confirmed fibroids were evaluated, using the pathological specimens for final diagnosis. Although TVUS PPV was 97%, overall sensitivity was 40%. US missed 71% of the intramural fibroids, 59% of subserosal fibroids, and 29% of submucosal fibroids. In addition, as fibroid size increased, the discrepancy between ultrasound-measured volume and pathologically assessed volume increased.

With respect to the utility of US in differentiating fibroids from sarcomas, it has been noted that on Doppler imaging, blood flow tends to be peripheral with fibroids, and more central in LMS³⁵ and that “peak systolic velocity (PSV)” is significantly higher values in sarcoma cases (mean 71.0 cm/s versus 22.7 cm/s).⁹³

Saline infusion sonohysterography (SIS) incorporates the infusion of saline into the uterus during US imaging - providing contrast and better definition of submucosal lesions (fibroids, polyps) compared to TVUS alone. Diagnostic parameters for SIS in detecting submucosal fibroids are better than compared to

TVUS alone and on par with hysteroscopy^{90,92}. In addition, SIS may better estimate the degree to which a fibroid protrudes into the uterine cavity – which may inform the preferred route of removal. SIS however, like TVUS alone, does not provide any reliable way of differentiating benign from malignant lesions.

Elastography is an ultrasound modality in which the strain profile of tissue during compression (“stiffness”) is assessed. Available evidence on the use of elastography as a tool for evaluating uterine masses is limited, and largely only published in case reports. Veldman⁹⁴ noted that fibroids appear stiffer than endometrial polyps or adenomyosis, but malignancies show variable stiffness. Nitta⁹⁵ noted that sarcomas may show a mosaic pattern whereas fibroids may be more homogeneous.

Hysteroscopy and Hysterosalpingogram

Hysteroscopy allows direct visualization of the uterine cavity and endometrium and for biopsy of abnormal lesions. It generally has very high sensitivity and NPV for submucosal fibroids.^{90,91} Hysterosalpingogram, a contrast study, is often performed to assess patency of the fallopian tubes but its utility in assessing intrauterine lesions is limited by a high false-positive rate and a limited specificity⁴⁴.

Magnetic Resonance Imaging (MRI)

In general, fibroids that have not degenerated appear as low signal intensity (SI) compared to the myometrium, homogenous, and circumscribed areas on T2 MRI images. Fibroids which have undergone degeneration may show higher SI than those which have not. On T1 images, a typical fibroid is of the same SI as the surrounding myometrium. After administration of intravenous gadolinium, fibroids typically show a later enhancement than normal myometrium.

MRI is regarded as the most sensitive imaging modality for the evaluation of uterine fibroids. When compared to US, MRI is generally better at allowing users to identify the number and location of fibroids. Dueholm⁹⁶ evaluated 108 consecutive women scheduled for hysterectomy for benign indications. Patients underwent MRI and TVUS prior to the surgery and the surgical specimen was used to determine final diagnosis. Their report included a total of 257 fibroids (locations unspecified) from 63 women and noted that MRI missed one fibroid in every 2-3 patients, whereas US missed more than one fibroid per patient. In patients with 5 or more fibroids, the mean number of fibroids missed rose, but more so for US. The authors also noted that US performance in detecting individual fibroids, when compared to MRI, dropped with larger uterine volumes – especially if above 375mL.

As noted above, Levens¹²⁷ evaluated women with symptomatic fibroids scheduled for hysterectomy who underwent both TVUS and MRI imaging prior to surgery. For the detection of individual fibroids, sensitivity of MRI was 80% and PPV was 91% (compared to 40% and 97% for US). MRI tended to miss a fair proportion of small (<0.52cm) fibroids (14/30). With respect to assessment of fibroid diameter, the mean diameter equivalent discrepancy between that predicted by the imaging tool and that by pathological measurement was 0.51cm for MRI and 0.76cm for ultrasound.

In addition to defining the location, number and size of fibroids, pre-operative and/or post-operative MRI findings may provide information regarding likelihood of response to certain non-surgical therapies including magnetic resonance-guided focused ultrasound (MRgFUS)^{113,114,118,123} and uterine artery embolization (UAE).^{153,156-158}

Although many fibroids are of low SI on T2 weighted images, as fibroids enlarge, they may outgrow their blood supply and undergo necrosis and degeneration. This may alter the SIs and lead to significant

overlap with sarcomas which typically show intermediate to high SI on T2 images. Hence, unless certain findings are present (e.g., capsular invasion, lymphadenopathy), it is often difficult to distinguish malignant from benign masses by MRI alone. This has led to active research to further evaluate different MRI techniques which may allow users to more accurately differentiate these types of lesions.

In 2002, Goto⁸² reported on a prospective study which included 10 patients with LMS and 130 with degenerated leiomyoma (DLM) and evaluated the utility of MRI alone, dynamic MRI with gadolinium, and dynamic MRI in combination with total serum LDH in differentiating the two types of lesions. The upper limit of normal for total LDH was considered 412 IU/l and a positive dynamic MRI was one with rapid enhancement in the early phase (20-90 seconds) following Gd-DTPA administration. Table 8 below notes the sensitivity, specificity, PPV, and NPV for the determination of LMS with each modality.

Table 8. Diagnostic Parameters Using MRI + Serum LDH³⁹

	MRI Alone	Dynamic MRI (Gd-DTPA)	Dynamic MRI + Serum LDH
Sensitivity	100%	100%	100%
Specificity	96.9	87.5%	99.2%
PPV	71.4%	71.4%	90.9%
NPV	100%	100%	100%

More recent studies have assessed the utility of MRI in differentiating benign from malignant uterine tumors by using diffuse-weighted imaging (DWI) – which is based on the diffusion motion of water. DWI can allow for the measurement of the “apparent diffusion coefficient (ADC)” which is affected by the nuclear-to-cytoplasm ratio. Although ADC values often overlap between uterine sarcomas and fibroids, Thomassin-Naggara⁹⁷ combined results of T2-weighted images with b_{1,000} values and ADC features in an effort to improve the ability to differentiate the types of lesions. (The b factor summarizes the influence of the gradients on the diffusion weighted images. The higher the b-value, the stronger the diffusion weighting). In a retrospective review of 51 tumors (26 leiomyomas, 19 malignant sarcomas, and 6 “uncertain malignant potential”), the model used correctly differentiated benign from uncertain or malignant tumors in 47 of the 51 cases (92.4%). In a more recent publication Satol⁹⁸ evaluated 10 LMS from 5 different patients using DWI and ADC parameters. Their findings suggested that lesions with intermediate or high SI on DWI were suggestive of LMS, and in these patients a cut-off of an ADC < 1.1 identified all 10 malignancies. The authors quoted a sensitivity 100%, specificity 94%, PPV 66.7%, and NPV 100% with these parameters.

5.7 Computed Tomography (CT) Scanning

Research is actively being pursued in the area of Positron Emission Tomography (PET) CT scanning – with particular focus on trying to differentiate benign from malignant uterine tumors. ¹⁸F-FDG PET scanning – which is impacted by glucose metabolism – is unable to reliably differentiate the two types of lesions⁹⁹. However, in evaluation of the tracer ¹⁸F-FLT (which accumulates in cells with increased proliferation), Yamane¹⁰⁰ reported a sensitivity and NPV of 100% and specificity and PPV of 90% and 84% respectively for the diagnosis of malignancy. This study was small (only 5 malignancies and 10 fibroids) and the authors cautioned that a LMS with extensive necrosis might cause a false negative result.

The panel will be asked to comment on the available evidence regarding pre-treatment diagnostics for determining the presence of a uterine sarcoma and/or differentiating from benign fibroids.

Appendix D: Comparative Surgical Outcomes as A Function of Hysterectomy Technique¹⁷

VH = Vaginal Hysterectomy

AH = Abdominal Hysterectomy

LH = Any Laparoscopic Hysterectomy

TLH = Total Laparoscopic Hysterectomy

LAVH = Laparoscopic Assisted Vaginal Hysterectomy

LH(a) = “uterine vessels ligated laparoscopically but part of operation performed vaginally”

Statistically significant outcomes in italics

	VH vs AH	LH vs. AH	LH vs. VH	TLH vs. VH	TLH vs. LAVH
Return to Normal Activities (Mean diff, Days)	-9.5 <i>(-12.6, -6.4)</i> 3 trials, N=176	-13.6 <i>(-15.4, -11.8)</i> 6 trials, N=520	No diff 2 trials, N=140	(Not reported)	(Not reported)
Intraoperative Visceral Injury	No diff (urinary) No events (bowel, vascular) 3 trials, N=239	<i>OR 2.41 (urinary)</i> <i>(1.21 to 4.82)</i> 12 trials, N=2090	No diff (urinary) 7 trials, N=1205	<i>OR 3.69 (urinary)</i> <i>(1.11 to 12.24)</i> 2 trials, N=440	No diff urin/vasc No events (bowel) 2 trials, N=186
Major Long-term Complications	No events (urinary) 1 trial, N=80	No diff fistula 2 trials, N=245 No diff urinary 2 trials, N=246	No diff fistula 1 trial, N=56 No diff urinary 1 trial, N=80	(Not reported)	No diff dyspareunia, orgasm 1 trial, N=101
Satisfaction/QOL	<i>VH superior for SF36 function, physical and pain (Silva Filho 2006)</i> No diff in pat satisfaction (Benassi 2002)	<i>LH superior at 6 wks on SF12, body image and sexual frequency (Garry 2004)</i> <i>LH superior at 12 wks on RAND36 vitality (Kluivers 2007)</i> No diff pt satisfaction	<i>LH superior at 6 wks for SF12 physical component (Morelli 2007)</i>	(Not reported)	(Not reported)
Operative Time (Mean diff, min)	Mixed results so not pooled 3 trials, N=259	<i>Overall +11.8 (8.6 to 14.9)</i> 11 trials, N=1047 (outcomes varied by type of LH)	+39.3 (38.7 to 39.9) 6 trials, N=741	(Not reported)	+23.3 (10 to 41) 1 trial, N=101




Intra-op complications (except visceral injury)	No diff mean blood loss 2 trials, N=140	Overall no diff in substantial bleeding 5 trials, N= 1266 <i>LH(a) OR 0.50 (0.26 to 0.95)</i> 8 trials, N=641	<i>OR 2.76 (1.02 to 7.42)</i> 2 trials, N=904 No diff in conversion to laparotomy 8 trials, N=1290	(Not reported)	No diff in conversion to laparotomy 2 trials, N=189
Short-term outcomes, complications	<i>Hospital stay MD -1.1 day (-1.2 to -0.9)</i> 4 trials, N=295 <i>Febrile episodes/infection OR 0.42 (0.21 to 0.83)</i> 4 trials, N=295	<i>Hospital stay MD -2.0 days (-2.2 to -1.9)</i> 10 trials, N=1007 <i>Wound infection OR 0.31 (0.12 to 0.77)</i> 6 trials, N=530 <i>Fever/unspec infection OR 0.67 (0.51 to 0.88)</i> 15 trials, N=2138 <i>Mean blood loss MD -45.3mL (-73 mL to 18mL)</i> 7 trials, N=693 No diff thrombo-embolic events 3 trials, N=1125	Hospital stay no difference 5 trials, N=685 <i>Transfusion OR 2.07 (1.12 to 3.81)</i> 7 trials, N=1249		Hospital stay no difference 1 trial, N=101 <i>Fever/unsp infection OR 3.77 (1.05 to 13.51)</i> 2 trials, N=186



Cochrane Review Reference:





Appendix E: Labeling for Uterine Laparoscopic Power Morcellators

The table below highlights relevant portions of product labeling for each of the LPM devices cleared with gynecologic indications.

Manufacturer /Distributor	Device	Summary of Relevant Safety Information in Labeling and PDF of product labeling
Ethicon, Inc.	Gynecare Morcellex Tissue Morcellator	<p>Contraindication: For use in vascularized tissue and as a dissecting tool.</p> <p>Warning: To prevent accidental injuries to the abdominal wall or similar structure, the tissue to be morcellated should be completely exposed before applying the device. In addition, it is recommended that a second pair of grasping forceps or a fixation instrument to be used to prevent large pieces of tissue from uncontrollably moving. Unintended movement of the device can cause significant injury.</p> <p>CAUTION: A tissue extraction bag is recommended for the morcellation of malignant tissue or tissue suspected of being malignant and for tissue that the physician considers to be potentially harmful when disseminated in a body cavity.</p> <p>Exercise care when inserting or removing the instrument. Insertion and removal of the instrument should be performed under direct visualization at all times.</p> <p> Ethicon Label.pdf</p>
Karl Storz	Sawahle Rotocut G1	<p>Contraindicated for use on vascularized tissue as a dissecting tool.</p> <p>Direct use for electromechanical morcellation, resection, or tissue ablation is contraindicated in the case of malignant tumors and vascularized tissue. The Electromechanical Morcellator must not be used as a medium for dissection.</p> <p>Warning: Risk of injury! Sharp-edged cutting tube. Can cause injury to tissue even in unactivated state. For this reason, insert or remove the cutting tube only under optical control.</p> <p>Note: The use of a tissue extraction bag is advised for the morcellation of tumors or tissue suspected of being malignant and for tissue that the surgeon may consider to be harmful if disseminated in a body cavity.</p> <p>  Sawahle IFU.pdf ROTOCUT G1 ICL.pdf</p>

Richard Wolf	Morce Power Plus	<p>Contraindicated for treatment of malignant tumors, treatment of vascularized tissue and preparation of tissue.</p> <p>Cautions: To prevent accidental injuries to the abdominal wall or similar structure the tissue to be morcellated should be completely exposed before applying the device. In addition, it is recommended that a second pair of grasping forceps or a fixation instrument be used to prevent large pieces of tissue from uncontrollably moving. Slippage of the cutting tube can cause significant injury.</p> <p>Exercise care when inserting or removing the instrument. Use the blade guard to prevent lateral injury to tissue from the sharp edged cutting tube. Insertion and removal should be performed under direct visual control at all times.</p> <p>The use of a tissue extraction bag is recommended for the morcellation of tissue suspected of being malignant and for tissue the surgeon may consider to be potentially harmful when disseminated in the body cavity.</p> <p> GA-ADM USA_1.0 (03-0425).pdf</p>
LiNA	LiNA Xcise	<p>Contraindications:</p> <p>Contraindications for use on vascularized tissue (ovaries, fallopian tubes, myomas and other structures): must be devascularized before morcellation</p> <p>The LiNA Xcise should NOT be used in patients who have been diagnosed with a malignant condition.</p> <p>Warnings: Do NOT activate the LiNA Xcise if it is not possible to visualize the cutting tip.</p> <p>Precautions: Use of LiNA Xcise requires adequate training and experience in performing laparoscopic myomectomy and hysterectomy.</p> <p>Be careful when inserting or removing the device. Make sure that the cutting blade is retracted by putting the trocar in the “Safe Guard” position during insertion and removal and whenever the cutting blade is not in active use. Insertion and removal of the LiNA Xcise should always be performed under direct visual control. Keep the rotating blade visible during the entire morcellation procedure.</p> <p> Appendix LiNA Xcise F002016...</p>

Trokamed	Trokamed Morcellator	<p>Contraindication: The morcellator may not be used in treatment of malignant tumors or for vascularized tissue. It may also not be used to prepare tissue.</p>  <p>Link Description</p>
Gyrus	PlamsaSord	<p>Contraindicated when, in the best judgment of the physician, bipolar electrosurgical procedures would be contrary to the best interests of the patient.</p> <p>Warnings: Inappropriate use of electrosurgery instruments can cause damage to tissue, both electrically and thermally. This instrument should not be used in close proximity to tissue structures (including the bladder, bowel or abdominal wall) susceptible to damage unless it is the intention to resect the tissue.</p> <p>Only open the PKS PlasmaSORD grasper jaws in good visibility and when in close proximity to the target tissue.</p> <p>Keep the instrument tip in sight during use. Inadvertent activation or movement of the instrument outside the field of vision may result in patient injury. To prevent accidental injuries to the abdominal wall, bladder, bowel, or other structures or nerve stimulation, the tissue to be morcellated should be completely exposed and fixed to prevent large pieces of tissue from moving before applying the device. Depress the foot pedal to activate the device only when the distal tip is in the field of view.</p> <p>If visualization of the treatment site or device is lost during the procedure, STOP IMMEDIATELY. Do not proceed until visibility is restored.</p> <p>Do not use this device with tissue removal bags.</p>  <p>PlasmaSORD_IF...</p>

7 LITERATURE REFERENCES

1. Okolo S. Incidence, aetiology and epidemiology of uterine fibroids. *Best Practice & Research Clinical Obstetrics and Gynaecology* 2008; 22(4):571-588
2. Ciavattini A, Di Giuseppe J, Stortoni P, Montik N et al. Uterine fibroids: pathogenesis and interactions with endometrium and endomyometrial junction. *Obstet and Gyn Intl* 2013; dx.doi.org/10.1155/2013/173184
3. Gupta S, Jose J, Manyonda I. Clinical presentation of fibroids. *Best Practice & Research Clinical Obstetrics and Gynecology* 2008; 22:615-626
4. Parker W. Etiology, symptomology, and diagnosis of uterine myomas. *Fertility and Sterility* 2007; 87(4): 725-736
5. Gupta S, Manyonda I. Acute complications of fibroids. *Best Practice & Research Clinical Obstetrics and Gynaecology* 2009; 23:609-617
6. Khan A, Shehmar M, Gupta J. Uterine fibroids: current perspectives. *Intl Journal of Women's Health* 2014; 6:95-114
7. Brady P, Stanic S, Styer A. Uterine fibroids and subfertility: An update on the role of myomectomy. *Curr Opin Obstet Gynecol* 2013; 25:255-259
8. Yan L, Ding L, Li C, Wang Y, Tang R, Chen Z. Effect of fibroids not distorting the endometrial cavity on the outcome of in vitro fertilization treatment: a retrospective cohort study. *Fertility and Sterility* 2014; 101(3):716-721
9. Metwally M, Farquhar C, Li T. Is another meta-analysis on the effects of intramural fibroids on reproductive outcomes needed? *Reproductive Biomedicine Online* 2011; 23:2-14.
10. Guo X, Segars J. The impact and management of fibroids for fertility. *Obstet Gynecol Clinics of North America* 2012; 39:521-533
11. Centers for Disease Control and Prevention) <http://www.cdc.gov/nchs/faststats/insurg.htm>
12. Rosero EB, Kho KA, Joshi GP et al. Comparison of robotic and laparoscopic hysterectomy for benign gynecologic disease. *Obstet Gynecol* 2013; 122(4): 778-786.
13. Thakar R, Ayers S, Clarkson P et al. Outcomes after total versus subtotal abdominal hysterectomy. *NEJM* 2002; 347: 1318-1325.
14. Learman LA, Summitt RL Jr., Varner RE et al. A randomized comparison of total or supracervical hysterectomy; surgical complications and clinical outcomes. *Obstet Gynecol* 2003; 102: 453-462.
15. Gimbal H, Zobbe V, Andersen BM et al. Randomized controlled trial of total compared with subtotal hysterectomy with one-year follow up results. *BJOG* 2004; 110: 1088-1098.
16. Wu JM, Wechter ME, Geller EJ et al. Hysterectomy rates in the United States 2003. *Obstet & Gynecol* 2007; 110(5): 1091-1095.
17. Nieboer TE, Johnson N, Lethaby A et al. Surgical approach to hysterectomy for benign gynaecological disease. *Cochrane Database Syst Rev* 2009; 3: CD003677.

18. **ACOG Committee Opinion: Choosing the Route of Hysterectomy for Benign Disease. *Obstet & Gynecol* 2009; 114(5): 1156-1158.**
19. **Wright JD, Ananth CV, Lewin SN et al. Robotically-assisted versus laparoscopic hysterectomy among women with benign gynecologic disease. *JAMA* 2013; 309(7): 689-698.**
20. **Einarsson JI and Suzuki Y. Total laparoscopic hysterectomy: 10 steps toward a successful procedure. *Rev Obstet Gynecol* 2009; 2(1): 57-64.**
21. **Son M, Evanko JC, Mongero LB et al. Utility of cell salvage in women undergoing abdominal myomectomy. *Am J Obstet Gynecol* 2014; Feb 21 (e-pub ahead of print)**
22. **Munro MG. Uterine leiomyomas, current concepts: pathogenesis, impact on reproductive health, and medical, procedural and surgical management. *Obstet Gynecol Clin N Am* 2011; 38: 703-731.**
23. **Kongnyuy EJ, Wisonge CS. Interventions to reduce hemorrhage during myomectomy for fibroids. *Cochrane Database Syst Rev* 2011; Nov 9; (11): CD005355.**
24. **Hurst BS, Matthews ML, Marshburn PB. Laparoscopic myomectomy for symptomatic uterine myomas. *Fertil Steril* 2005; 83(1): 1-23.**
25. **Jin C, Hu Y, Chen XC et al. Laparoscopic versus open myomectomy; a meta-analysis of randomized controlled trials. *Eur J Obstet Gynecol Repro Biol* 2009; 145(1): 14-21.**
26. **Steiner R, Wight E, Tadir Y, Haller U. Electrical cutting device for laparoscopic removal of tissue from the abdominal cavity. *Obstet Gyn* 1993; 81(3):471-464**
27. **Driessen S, Arkenbout E, Thurkow A, Jansen F. Electromechanical morcellators in minimally invasive gynecologic surgery: an update. *J Minim Invasive Gynecol*. 2014 Jan 21. pii: S1553-4650(14)00026-0. doi: 10.1016/j.jmig.2013.12.121. [Epub ahead of print]**
28. **Zullo F, Falbo A, Iuliano A, Oppedisano R, et al. Randomized controlled study comparing the gynecare morcellex and rotocut g1 tissue morcellators. *Jour Min Invas Gyn* 2010;17:192-199.**
29. **Carter J, McCarus S. Laparoscopic Myomectomy. Time and Cost Analysis of Power vs Manual Morcellation. *Journal of Reproductive Medicine* 1997; 42(7):383-388**
30. **Yi YX, Zhang W, Zhou Q, Guo WR, Su Y. Laparoscopic-assisted vaginal hysterectomy vs abdominal hysterectomy for benign disease: a meta-analysis of randomized controlled trials. *Eur J Obstet Gynecol Reprod Biol*. 2011 Nov;159(1):1-18.**
31. **ACOG Committee Opinion No. 444: choosing the route of hysterectomy for benign disease. *Obstet Gynecol*. 2009 Nov;114(5):1156-8.**
32. **AAGL Advancing Minimally Invasive Gynecology Worldwide. AAGL position statement: route of hysterectomy to treat benign uterine disease. *J Minim Invasive Gynecol*. 2011 Jan-Feb;18(1):1-3.**
33. **Milad M, Milad E. Laparoscopic morcellator-related complications. *Journ of Minim Invasive Gyn* 2014; doi: 10.1016/j.jmig.2013.12.003. [Epub ahead of print]**

34. Cucinella G, Granese R, Calagna G, Somigliana E, Perino A. Parasitic myomas after laparoscopic surgery: an emerging complication in the use of morcellator? Description of four cases. *Fertility and Sterility* 2011; 96(2):e90-e96
35. Leibsohn S, d'Ablaing G, Mishell DR, Schlaerth JB. Leiomyosarcoma in a series of hysterectomies performed for presumed uterine leiomyomas. *Am J Obstet Gynecol.* 1990;162(4):968-974.
36. Reiter RC, Wagner PL, Gambone JC. Routine hysterectomy for larger asymptomatic uterine leiomyomata – a reappraisal. *Obstet Gynecol.* 1992;79(4):481-4.
37. Parker WH, Fu YS, Berek JS. Uterine sarcoma in patients operated on for presumed leiomyoma and rapidly growing leiomyoma. *Obstet Gynecol.* 1994;83(3):414-8.
38. Takamizawa S, Minakami H, Usui R, Noguchi S, Ohwada M, Suzuki M, et al. Risk of complications and uterine malignancies in women undergoing hysterectomy for presumed benign leiomyomas. *GynecolObstetInvest.* 1999;48(3):193-6.
39. Sinha R, Hegde A, Mahajan C, et al. Laparoscopic myomectomy: do size, number, and location of the myomas form limiting factors for laparoscopic myomectomy? *J Minim Invasive Gynecol.* 2008;15(3):292-300.
40. Kamikabeya TS, Etchebehere RM, Nomelini RS, Murta EF. Gynecological malignant neoplasias diagnosed after hysterectomy performed for leiomyoma in a university hospital. *European journal of gynaecological oncology.* 2010;31(6):651-3.
41. Rowland M, Lesnock J, Edwards R, Richard S, Zorn K, Sukumvanich P, et al. Occult uterine cancer in patients undergoing laparoscopic hysterectomy with morcellation. *Gynecol Oncol.* 2012;127(1):S29-S.
42. Leung F, Terzibackian JJ. Re “The impact of tumor morcellation during surgery on the prognosis of patients with apparently early uterine leiomyosarcoma”. *Gynecol Oncol.* 2012;124(1):172-173
43. Seidman MA, Oduyebo T, Muto MG, et al. Peritoneal dissemination complicating morcellation of uterine mesenchymal neoplasms. *PLoS One.* 2012;7(11):e50058.
44. Oduyebo T, Rauh-Hain A, Meserve E, Seidman M, Hinchcliff E, George S, Quade B, Nucci M, Del Carmen M, Muto M. The value of re-exploration in patients with inadvertently morcellated uterine sarcoma. *Gynecol Oncol.* 2014 Feb;132(2):360-5. doi: 10.1016/j.ygyno.2013.11.024. Epub 2013 Dec 1
45. Einstein, M, Barakat R, Chi D, Sonoda Y, Alektiar K, Hensley M, Abu-Rustum N. Management of uterine malignancy found incidentally after supracervical hysterectomy or uterine morcellation for presumed benign disease. *Int J Gyn Cancer* 2008; 18:1065-1070.
46. Morice P, Rodriguez A, Rey A, Pautier P, Atallah D, Genestie C, Pomel C, Lhommé C, Haie-Meder C, Duvillard P, Castaigne D. Prognostic value of initial surgical procedure for patients with uterine sarcoma: Analysis of 123 patients. *Euro Journal of Gynaecological Oncology* 2003 24:3-4 (237-240)
47. Park J, Park S, Kim D, Kim J, Kim Y, Kim Y, Nam J. The impact of tumor morcellation during surgery on the prognosis of patients with apparently early uterine leiomyosarcoma. *Gyn Onc* 2011; 255-259

48. Park JY, Kim D, Km J, Kim Y, Kim J, Nam J. The impact of tumor morcellation during surgery on the outcomes of patients with apparently early low grade endometrial stromal sarcoma. *Ann Surg Oncol*. 2011;18(12):3453-3461.
49. George S, Barysaukas C, Serrano C. Retrospective cohort study evaluating the impact of intraperitoneal morcellation on outcomes of localized uterine leiomyosarcoma. In Press, *Cancer* 2014.
50. Urban D, Kerbl K, McDougall E, Stone E, Fadden P, Clayman R. Organ entrapment and renal morcellation; permeability studies. *Jour of Urol* 1993; 150:1792-1794.
51. Rassweiler J, Stock C, Frede T, Seemann O, Alken P. Organ retrieval systems for endoscopic nephrectomy: a comparative study. *Journal of Endourol* 1998; 12(4): 325-333
52. Cai Y, Jacobson A, Marcovich R, Lowe D, El-Hakim A, Shah D, Smith A, Lee B. Electrical prostate morcellator: an alternative to manual morcellation for laparoscopic nephrectomy specimens? An in vitro study. *Urology* 2003; 61:1113-1117.
53. Eichel L, Adbelshehid C, Lee D, Uribe C, McDougall E, Clayman R. in vitro comparison of burst tension and puncture pressure in commonly used organ retrieval bags. *J Amer Coll Surgeons*, 2004; 199(1): 166-169
54. Parekh A, Moran M, Newkirk R, Desai P, Calvano C. Tissue removal utilizing steiner morcellator within a LapSac: effects of a fluid-filled environment. *J Endourol* 2000; 14(2): 185-189
55. Landman J, Collver W, Olweny E, Adnreoni C, McDougall E, Clayman R. Laparoscopic renal ablation: an in vitro comparison of currently available electrical tissue morcellators. *Urology* 2000; 56:677-681.
56. Meng M, Miller T, Cha I, Stoller M. Cytology of morcellated renal specimens: significance in diagnosis and dissemination. *Journ of Urology* 2003; 169:45-48
57. Ankem M, Deican S, Pareek G, Waterman B, Moon T, Selvaggi S, Nakada S. Examination of laparoscopic retrieval bag washings for malignant cells after hand-assisted laparoscopic radical nephrectomy and intact specimen removal. *Urology* 2006; 68: 50-52.
58. American Cancer Society. What are the key statistics about uterine sarcoma? <http://www.cancer.org/cancer/uterinesarcoma/detailedguide/uterine-sarcoma-key-statistics>. Accessed May 12, 2014.
59. Brooks SE, Zhan M, Cote T and Baquet CR. Surveillance, Epidemiology, and End Results analysis of 2677 cases of uterine sarcoma 1989-1999. *Gynecologic Oncology* 2004; 93: 204-208
60. Natalin R, Lima F, Pinheiro T et al. The final stage of the laparoscopic procedure: exploring final steps. *IBJU* 2012; 38(1):4-16
61. Seddon B, Davda R. Uterine sarcomas: recent progress and future challenges. *Eur J Rad* 2011; 78:30-40
62. D'Angelo E, Prat J. Uterine sarcomas: a review. *Gyn Onc* 2010; 116:131-139
63. Sutton G. Uterine sarcomas 2013. *Gyn Onc* 2013; 130: 3-5

64. El-Khalifaoui K, du Bois A, Heitz F, Kurzeder C, Sehoul J, Harter P. Current and future options in the management and treatment of uterine sarcoma. *Ther Advances in Med Onc* 2014; 6(1):21-28.
65. Novetsky A, Powell M. Management of sarcomas of the uterus. www.co-oncology.com 2013; 25(5):546-552
66. Trope C, Abeler V, Kristensen G. Diagnosis and treatment of sarcoma of the uterus. A review. *Acta Oncol* 2012; 51:694-705.
67. Arend R, Doneza J, Wright J. Uterine carcinosarcoma. *Curr Opin Oncol* 2011; 23:531-536
68. Rauh-Hain J, Carmen M. Endometrial stromal sarcoma. A systematic review. *Obstet & Gyn* 2013; 676-683.
69. Van der Bosch T, Coosemans A, Morina M, Timmerman D, Amant F. Screening for uterine tumors. *Best Pract & Research Clin Obstet Gyn* 2012; 26:257-266.
70. Gadducci A. Prognostic factors in uterine sarcoma. *Best Pract & Res Clin Obstet & Gyn* 2011; 25:783-795
71. Sohaib S, Verma H, Attygalle A, Ind T. Imaging of uterine malignancies. *Semin in Ultrasound CT MRI* 2010; 31:377-387
72. Wu T, Yen T, Lai C. Clinical presentation and diagnosis of uterine sarcoma including imaging. *Best Pract & Res Clin Obstet & Gyn* 2011; 25: 681-689
73. Nam J. Surgical treatment of uterine sarcoma. *Best Pract & Res Clin Obstet & Gyn* 2011; 25:751-760.
74. Shah S, Jagannathan J, Krajewski K, O'Regan K, George S, Ramaiya N. Uterine sarcomas: then and now. *AJR* 2012; 199:213-223.
75. Tirumani S, Ojili V, Shanbhogue A, Fasih N, Ryan J, Reinhold C. Current concepts in imaging of uterine sarcoma. *Abdom Imaging* 2013; 38:397-411
76. Reed N. A review of treatment of uterine leiomyosarcomas. *Curr Oncol Rep* 2013; 15:581-587.
77. Harry V, Narayansingh G, Parkin D. Uterine leiomyosarcomas: a review of the diagnostic and therapeutic pitfalls. *The Obstetrician and Gyn* 2007; 9:88-94
78. Strimbu K, Tavel J. What are Biomarkers? *Curr Opin HIV AIDS* 2010; 5(6):463-466
79. Babab R. Serum protein and prolactin as diagnostic markers. *Saudi Med Journal* 2009; 30:1411-1415.
80. Basta P, Mach P, Pitynski K, Bednaarek W, Klimek M, Zietek J. Differences in the blood serum levels of soluble HLA-G concentrations between the menstrual cycle phases and menopause in patients with ovarian endometriosis and uterine leiomyoma. *Neuroendocrin Letter* 2009; 30:91-98.
81. Koukourakis MI, Kontomanolis E, Giatromanolaki A, Sivridis E, Liberis V. Serum and tissue LDH levels in patients with breast/gynaecological cancer and benign diseases. *Gynecol Obstet Invest.* 2009;67(3):162-8.

82. Gota A, Takeuchi S, Sugimura K, Maruo T. Usefulness of Gd-DTPA contrast-enhanced dynamic MRI and serum determination of LDH and its isoenzymes in the differential diagnosis of leiomyosarcoma from degenerated leiomyoma of the uterus. *Int J Gyn Cancer* 2002; 12(4): 354-361
83. Juang CM1, Yen MS, Horng HC, Twu NF, Yu HC, Hsu WL. Potential role of preoperative serum CA125 for the differential diagnosis between uterine leiomyoma and uterine leiomyosarcoma. *Eur J Gynaecol Oncol.* 2006;27(4):370-4.
84. Kim H, Han K, Chung H. Neutrophil to lymphocyte ration for preoperative diagnosis of uterine sarcomas: a case-matched comparison. *Eur J Surg Oncol* 2010; 36:691-698.
85. Yilmaz N, Sahin I, Kilic S, Ozgu E, Gungor T, Bilge U. Assessment of the predictivity of preoperative serum CA 125 in the differential diagnosis of uterine leiomyoma and uterine sarcoma in the Turkish female population. *Eur J Gynaecol Oncol* 2009;30:412-4.
86. Trovik J, Salvesen H, Cuppens T, Amant F, Staff A. Growth differentiation factor-15 as biomarker in uterine sarcomas. *Intl J Gyn Cancer* 2014; 24:252-259.
87. Bansal N, Herzog T, Burke W, Cohen C, Wright J. The utility of preoperative endometrial sampling for the detection of uterine sarcomas. *Gyn Onc* 2008; 110:43-48
88. Kawamura N, Ichimura T, Ito F, Shibata S, Takahashi A. Transcervical needle biopsy for the differential diagnosis between uterine sarcoma and leiomyoma. *Cancer* 2002; 94(6):1713-1720.
89. Shwayder J, Sakhel K. Imaging of uterine myomas and adenomyosis. *Journ of Minimally Invasive Gyn* 2014 Article In Press
90. Bingol B, Gunenc Z, Gedikbasi A, Guner A, Tasdemir S, Tiras B. Comparison of diagnostic accuracy of saline infusion Sonohysterography, transvaginal sonography and hysteroscopy. *Jour Obstet & Gyn* 2011; 31(1): 54-58
91. Vitner D, Filmer S, Goldstein I, Khatib N, Weiner Z. A comparison between ultrasonography and hysteroscopy in the diagnosis of uterine pathology. *Eur J Obstet & Gyn and Rep Biol* 2013; 171:143-145
92. Erdem M, Bilgin U, Bozkurt N, Erdem A. Comparison of transvaginal ultrasonography and saline infusion Sonohysterography in evaluating endometrial cavity in pre- and postmenopausal women with abnormal uterine bleeding. *Menopause* 2007; 14(5): 846-852.
93. Hata K, Maruyama R, Hirai M. Uterine sarcoma: can it be differentiated from uterine leiomyoma with Doppler ultrasonography? A preliminary report. *Ultrasound Obstet & Gyn* 1997; 9:101-104
94. Veldman J, Van Holsbeke C, Werbrouck E, Bourne T, Timmerman D. Differentiation of uterine pathology by transvaginal elastography: preliminary results. *Ultrasound in Obstetrics & Gynecology* 2010; 36(S1):14-15
95. Nitta E, Kanenishi K, Itabashi N, Tanaka H, Hata T. Real-time tissue elastography of uterine sarcoma. *Arch Gyn Obstet* 2014; 289:463-465
96. Dueholm M, Lundorf E, Hansen E, Ledertoug S, Olesen F. Accuracy of magnetic resonance imaging and transvaginal ultrasonography in the diagnosis, mapping, and measurement of uterine myomas. *Amer J Obstet & Gyn* 2002; 186(3):409-415.

97. Thomassin-Naggara I, Dechoux S, Bonneau C, Morel A, Rouzier R, Carette M, Darai E, Bazot M. How to differentiate benign from malignant myometrial tumors using MR imaging. *Eur Radiol* 2013; 23:2306-2314.
98. Sato K, Yuasa N, Fuiata M, Fukushima Y. Clinical application of diffusion-weighted imaging for preoperative differentiation between uterine leiomyoma and leiomyosarcoma. *Amer J Obstet & Gyn* 2014; 210:368e1-8
99. Kitajima K, Murakami K, Kaji Y, Sugimura K. Spectrum of FDG PET/CT findings of uterine tumors. *AJR* 2010; 737-743.
100. Yamane T, Takaoka A, Kita M, Imai Y, Senda M. 18F-FLT PET performs better than 18F-FDG PET in differentiating malignant uterine corpus tumor from benign leiomyoma. *Ann Nucl Med* 2012; 26:478-484.
101. AAGL Practice Report: Practice guidelines for the diagnosis and management of submucous leiomyomas. *Journ Minim Invasiv Gyn* 2012; 19:152-171
102. Sabry M, Al-Hendy A. Medical Treatment of Uterine Leiomyoma. *Reprod Sci* 2012; 19(4):339-353
103. Hollen F, Griesinger G, Bohlmann M. Therapeutic drugs in the treatment of symptomatic uterine fibroids. *Expert Opin Pharmacother* 2013; 14(15):2079-2085
104. Chen I, Motan T, Kiddoo D. GnRH in laparoscopic myomectomy: Systematic review and meta-analysis of randomized controlled trials. *Jour of Min Invasive Gyn* 2011; 18:303-309
105. Zhang Y, Sun L, Guo Y, Cheng J, Wang Y, Fan S, Duan H. The impact of preoperative GnRH treatment on women with uterine fibroids: A meta-analysis. *Obstet and Gyn Survey* 2014; 69(2):100-108.
106. Sinai T, Belli A, Manyonda I. GnRH agonists: Do they have a place in modern management of fibroid disease? *Jour Obstet and Gyn of India* 2012; 62(5):506-510
107. Marret H, Fritel X, Ouldamer L, Bendifallah et al. Therapeutic management of uterine fibroid tumors: updated French guidelines. *Eur J Obstet & Gyn* 2012; 165:156-164
108. Zapata L, Whiteman M, Tepper N, Jamieson D, Marchbanks P, Curtis K. Intrauterine device use among women with uterine fibroids: a systematic review. *Contraception* 2010; 82:41-55
109. Sayed G, Zakherah M, El-Nashar S, Shaaban M. A randomized clinical trial of levonorgestrel-releasing intrauterine system and a low-dose combined oral contraceptive for fibroid-related menorrhagia. *Intl J of Gyn and Obstet* 2001; 112:126-130.
110. Kriplani A, Awasthi D, Kulshrestha V, Agarwal N. Efficacy of the levonorgestrel-releasing intrauterine system in uterine leiomyoma. *Intl Jour Gyn and Obstet* 2012; 116:35-38
111. Eder S, Baker J, Gertsen J, Mabey R, Adomako T. Efficacy and safety of oral tranexamic acid in women with heavy menstrual bleeding and fibroids.
112. Summary of Safety and Effectiveness, P040003. http://www.accessdata.fda.gov/cdrh_docs/pdf4/P040003b.pdf. Accessed April 29, 2014
113. Dobrotwir A, Pun E. Clinical 24 month experience of the first MRgFUS unit for treatment of uterine fibroids in Australia. *Journal of Medical Imaging and Radiation Oncology* 2012; 56:409-416

114. Lenard Z, McDannold N, Fennessy F. Uterine leiomyomas: MR imaging-guided focused ultrasound surgery – imaging predictors of success. *Radiology* 2008; 249:187-194.
115. Yoon S, Cha S, Ji Y, Kim H, Lee M, Cho J. Magnetic resonance imaging-guided focused ultrasound surgery for symptomatic uterine fibroids: estimation of treatment efficacy using thermal dose calculations. *Euro J Obstet & Gyn and Reprod Biol* 2013; 169: 304-308
116. Fennessy F, Tempany C, McDonnold N, So M, Hesley G, Gostout B, Kim H, Holland G et al. Uterine leiomyomas: MR Imaging-guided focused ultrasound surgery – results of different treatment protocols. *Radiology* 2007; 243: 885-893.
117. Stewart E, Rabinovici J, Tempany C, Inbar Y, Regan L, Gostout B, Hesley G, Kim H, Hengst S, Gedroye W. Clinical outcomes of focused ultrasound surgery for the treatment of uterine fibroids. *Fertility and Sterility* 2006; 85(1): 22-29
118. Park M, Kim Y, Rhim H, Lim H. Safety and therapeutic efficacy of complete or near-complete ablation of symptomatic uterine fibroid tumors by MRgFUS therapy. *J Vasc Intervent Radiol* 2014; 25:231-239
119. Morita Y, Ito N, Hikida H, Takeuchi S, Nakamura K, Ohashi H. Non-invasive magnetic resonance imaging-guided focused ultrasound treatment for uterine fibroids – early experience. *Euro J of Obstet & Gyn* 2008; 139:199-203
120. Rabinovici J, Inbar Y, Revel A, Zalel Y, Gomori J, Itzhak Y, Schiff E, Yagel S. Clinical improvement and shrinkage of uterine fibroids after thermal ablation by magnetic resonance-guided focused ultrasound surgery. *Ultrasound Obstet Gynecol* 2007; 30: 771–777
121. Kim H, Bail J, Pham L, Jacobs M. MR-guided high-intensity focused ultrasound treatment for symptomatic uterine leiomyomata: long-term outcomes. *Acad Radiol* 2011; 18:970-976.
122. Funaki K, Fukunishi H, Funaki T, Sawada K, Kaji Y, Maruo T. Magnetic resonance-guided focused ultrasound surgery for uterine fibroids: relationship between the therapeutic effect and signal intensity of preexisting T2-weighted MR images. *Amer Journal of Obstet & Gyn* 2007; 184.e1-184.e6
123. Machtinger R, Inbar Y, Cohen-Eylon S, Admon D, Alagem-Mizrachi A, Rabinovici J. MR-guided focus ultrasound for symptomatic uterine fibroids: predictors of treatment success. *Human Reprod* 2012; 27(12):3425-3431.
124. Froeling V, Meckelburg K, Scheurig-Muenkler C, Schreiter N, Kamp J, Maurer M, Beck A, Hamm B, Kroencke. Midterm results after uterine artery embolization versus MR-guided high-intensity focused ultrasound treatment for symptomatic uterine fibroids. *Cardiovasc Intervent Radiol* 2013; 36:1508-1513.
125. LeBlang S, Hocter K, Steinberg F. Leiomyoma shrinkage after MRI-guided focused ultrasound treatment: report of 80 patients. *AJR* 2010; 194:274-280.
126. Funaki K, Fukunishi H, Sawada K. Clinical outcomes of magnetic resonance-guided ultrasound surgery for uterine myomas: 24-month follow-up. *Ultrasound Obstet Gyn* 2009; 34:584-589.

127. Levens E, Wesley R, Premkumar A, Blocker W, Nieman L. Magnetic resonance imaging and transvaginal ultrasound for determining fibroid burden: implications for research and clinical care. *Amer J Obstet and Gyn* 2009; 200:538 e1-537
128. Kresch AJ, Lyons TL, Westland AB, Winer WK, Savage GM. Laparoscopic Supracervical Hysterectomy with a New Disposable Morcellator. *J Am Assoc Gynecol Laparosc* 1998; 5(2):203-206.
129. Toor S, Jaber A, Macdonald D, McInnes M, Schweitzer M, Rasuli P. Complication rates and effectiveness of uterine artery embolization in the treatment of symptomatic leiomyomas: A systematic review and meta-analysis. *AJR* 2012; 199:1153-1163
130. Martin J, Bhanot K, Athreya S. Complications and reinterventions in uterine artery embolization for symptomatic uterine fibroids: A literature review and meta-analysis. *Cardiovasc Intervent Radiol* 2013; 36:395-402.
131. Gupta J, Singa A, Lumsden M, Hickey M. Cochrane Collaboration: Uterine artery embolization for symptomatic uterine fibroids. 2012
132. Takeda A, Mori M, Sakai K, Mitsui T, Nakamura H. Parasitic peritoneal leiomyomatosis diagnosed 6 years after laparoscopic myomectomy with electric tissue morcellation: Report of a case and review of the literature. *Journ Min Invasive Gyn* 2007; 770-775
133. Stout M, Odibo A, Graseck A, Macones G, Crane J, Cahill A. Leiomyomas at routine second-trimester ultrasound examination and adverse obstetric outcomes. *Obstet & Gyn* 2010; 116:1056-1063
134. Edwards D et al (REST Investigators). Uterine-artery embolization versus surgery for symptomatic uterine fibroids. *NEJM* 2007; 356(4): 360-370.
135. Moss J, Cooper K, Khanund A, Murray L, Murray G, Wu O, Criag L, Lumsden M. Randomised comparison of uterine artery embolization with surgical treatment in patients with symptomatic uterine fibroids (REST trial): 5-year results. *BJOG* 2011; 936-944
136. Ananthakrishnan G, Murray L, Ritchie M, Murray G, Bryden F, Lassman S, Lumsden M, Moss J. Randomized comparison of uterine artery embolization with surgical treatment in patients with symptomatic uterine fibroids (REST Trial): Subanalysis of 5-year MRI findings. *Cardiovasc Interv Radio* 2013; 36:676-681.
137. Hehenkamp, W, Volkers N, Donderwinkel P, Birnie E, Ankum W, Reekers J. Uterine artery embolization versus hysterectomy in the treatment of symptomatic uterine fibroids (EMMY trial): Peri- and postprocedural results from a randomized controlled trial. *American Journal of Obstetrics and Gynecology* (2005) 193, 1618–29
138. Volkers N, Hehenkamp W, Birnie E, et al. Uterine artery embolization versus hysterectomy in the treatment of symptomatic uterine fibroids: 2 years' outcome from the randomized EMMY trial. *Am J Obstet Gynecol* 2007;196:519e.1-519.e11.
139. Van der Kooij S, Hehenkamp W, Volkers N, Birnie E, Ankum W, Reekers J. Uterine artery embolization vs hysterectomy in the treatment of symptomatic uterine fibroids: 5-year outcome from the randomized EMMY trial. *Amer J Obstet & Gyn* 2010; 203:105.e1-13
140. Spies J, Cooper J, Worthington-Kirsch R, Lipman J, Mills B, Benenati J. Outcome of uterine embolization and hysterectomy for leiomyomas: results of a multicenter study. *Amer J Obstet and Gyn* 2004; 191:22-31

141. Ruuskanen A, Hippelainen M, Sipola P, Manninen H. Uterine artery embolization versus hysterectomy for leiomyomas: primary and 2-year follow-up results of a randomized prospective clinical trial. *Eur Radio* 2010; 20:2524-2532.
142. Siskin G, Shlanskay-Goldberg R, Goodwin S et al. A prospective multicenter comparative study between myomectomy and uterine artery embolization with polyvinyl alcohol microspheres: long-term clinical outcomes in patients with symptomatic uterine fibroids. *J Vasc Int Radio* 2006; 17:1287-1295
143. Mara M, Maskova J, Fucikova Z, Kuzel D, Belsan T, Sosna O. Midterm clinical and first reproductive results of a randomized controlled trial comparing uterine fibroid embolization and myomectomy. *Cardiovasc Intervent Radiol* (2008) 31:73–85
144. Pinto I, Chimeno P, Romo A, Paul L, Haya J, de la Cal M, Bajo J. Uterine fibroids: uterine artery embolization versus abdominal hysterectomy for treatment – a prospective randomized and controlled clinical trial. *Radiology* 2003; 226(2):425-431
145. Spies J, Bradley L, Guido R, Maxweel L, Levine B, Coyne K. Outcomes from leiomyoma therapies: comparison with normal controls. *Obstet & Gyn* 2010; 116(3):641-652
146. Jun F, Yamin L, Xinli X, Zhe L, Min Z, Bo Z, Wenli G. Uterine artery embolization versus surgery for symptomatic uterine fibroids: a randomized controlled trial and a meta-analysis of the literature. *Arch Gyn Obstet* 2012; 285:1407-1413.
147. Goodwin S, Bradley L, Lipman J, Stewart E, Noshier J, Sterling K, Barth M, Siskin G, et al. Uterine artery embolization versus myomectomy: a multicenter comparative study. *Fertility and Sterility* 2006; 85(1):14-21.
148. Manyonda I, Bratby M, Horst J, Banu N, GOrti M, Belli A. Uterine artery embolization versus myomectomy: impact of quality of life – results of the FUME Trial. *Cardiovasc Intervent Radiol* 2012; 35:530-536
149. Dutton S, Hirst A, McPherson K, Nicholson T, Maresh M. A UK multicenter retrospective cohort study comparing hysterectomy and uterine artery embolization for the treatment of symptomatic uterine fibroids (HOPEFUL study): main results on medium-term safety and efficacy. *BJOG* 2007; 114:1340-1351
150. Walker W, Barton-Smith P. Long term follow up of uterine artery embolization – an effective alternative in the treatment of fibroids. *BJOG* 2006; 464-468.
151. Smeets A, Nijenhuis R, van Rooij W, Weimar E, Boekkooi P, Lampmann L, Vervest H, Lohle M. Uterine artery embolization in patients with a large fibroid burden: long-term clinical and MR follow-up. *Cardiovasc Intervent Radiol* 2010; 33:943-948.
152. Poulsen B, Munk T, Ravn P. Long-term follow up after uterine artery embolization for symptomatic uterine leiomyomas. *Acta Obstet Gyn* 2011; 30:1281-1283.
153. Gabriel-Cox K, Jacobson G, Armstrong M, Hung Y, Learman L. Predictors of hysterectomy after uterine artery embolization for leiomyoma. *Amer Jour Obstet & Gyn* 2007; 588.e1-e6.
154. Spies JB, Bruno J, Czeyda-Pommershein F, Magee S, Ascher S, Jha R. Long-term outcome of uterine artery embolization of leiomyomata. *Obstet Gyn* 2005; 106:933-939.

155. Hehenkamp W, Volkers N, Birnie E, Reekers J, Ankum W. Symptomatic uterine fibroids: treatment with uterine artery embolization or hysterectomy – results from the EMMY Trial. *Radiology* 2008; 246(3):823-832
156. Freed M, Spies J. Uterine artery embolization for fibroids: a review of current outcomes. *Seminars in Reprod Med* 2010; 28(3):235-241
157. Park A, Bohrer J, Bradley L, Diwadkar G, Moon E, Newman J, Jelovsek J. Incidence and risk factors for surgical intervention after uterine artery embolization. *Amer J Obstet Gyn* 2008; 199(6):671.e1-6
158. Scheurig-Muenkler C, Koesters C, Powerski M, Grieser C, Froeling V, Kroencke T. Clinical long-term outcome after uterine artery embolization: sustained symptom control and improvement in quality of life. *J Vasc Interv Radiol* 2013; 24:765-771.
159. Guido R, Macer J, Abbott, K, Falls J, Tilley I, Chudnoff S. Radiofrequency volumetric thermal ablation of fibroids: a prospective, clinical analysis of two years' outcome from the Halt Trial. *Health and Quality of Life Outcomes* 2013; 11:139-147
160. Berman J, Guido R, Leal J, Permueller R, Whaley F, Chudnoff S. Three years' outcome from the Halt trial: A prospective analysis of radiofrequency volumetric thermal ablation of myomas. *Jour Min Invasive Gyn* 2014; doi:10.1016/j.jmig.2014.02.015
161. Rosenbaum S, Fried M, Munro M. Endometrial hydrothermablation: a comparison of short-term clinical effectiveness in patients with normal endometrial cavities and those with intracavitary pathology. *J Min Inv Gyn* 2005; 12:144-149.
162. Glasser M, Heinlein P, Hung Y. Office endometrial ablation with local anesthesia using the HydroThermAblator System: Comparison of outcomes in patients with submucous myomas with those with normal cavities in 246 cases performed over 5 ½ years. *Journ of Minim Invasive Gyn* 2009; 16(6):700-777
163. Mba E. The HTA system for management of menorrhagia in women with myomas: 6-12 month follow-up. *Journ of Min Invasive Gyn* 2005; 12(5): Sept/Oct Supplement S60
164. SEER Cancer Statistics Review 1975-2010. www.seer.cancer.gov.
165. ACOG Special Report: Power Morcellation and Occult Malignancy in Gynecologic Surgery: A Special Report. May 2014
166. AAGL: Morcellation During Uterine Tissue Extraction. May 2014
167. Wisner A, Holcroft C, Tulandi T, Abenhaim H. Abdominal versus laparoscopic hysterectomies for benign disease: evaluation of morbidity and mortality among 465,798 cases. *Gynecol Sur* 2013; 10:117-122
168. Rivard C, Salhadar A, Kenton K. New challenges in detecting, grading, and staging endometrial cancer after uterine morcellation. *Jour Minimally Invasive Gyn* 2012; 19: 313-316
169. Landy S, Minelli L. Chapter VII Technique of Laparoscopic Myomectomy. *Manual of Gynecological Laparoscopic Surgery 2nd Edition*. Endopress, 2013

170. Eichel L, Clayman R. Chapter 9. Fundamentals of laparoscopic and robotic urologic surgery. *Campbell-Walsh Urology Review Tenth Addition*. 2012
171. Wu S, Lesani A, Zhao L, Johnston W, Wolf J, Clayman R, Nadler R. A multi-institutional study on the safety and efficacy of specimen morcellation after laparoscopic radical nephrectomy for clinical stage t1 or t2 renal cell carcinoma. *Jour of Endourol* 2009; 23(9):1513-1518
172. Varkarakis I, Rha K, Hernandez F, Kaboussi L, Jarrett T. Laparoscopic specimen extraction: morcellation. *BJU* 2005; 95(S1):27-31
173. Serur E, Lakhi N. Laparoscopic hysterectomy with manual morcellation of the uterus. *Amer Jour of Obstet & Gyn* 2011; 566.e1-e2
174. Kho K. Evaluating the risks of electric uterine morcellation. *JAMA*, 2014; 311(9): 905-906
175. Uccella S, Cromi A, Bogani G, Casarin J, Serati M, Ghezzi F. Transvaginal specimen extraction at laparoscopy without concomitant hysterectomy: our experience and systematic review of the literature. *Jour Minimally Invasive Gyn* 2013; 20:583-590.
176. Favero G, Anton C, Silva A, Ribeiro A, Araujo M, Miglino G, Baract E, Carvalho J. Vaginal morcellation: a new strategy for large gynecological malignant extraction. *Gyn Onc*, 2012; 126:443-447.
177. Wyman A, Fuhrig L, Bedaiwy M, DeBernardo R, Coffey G. A novel technique for transvaginal retrieval of enlarged pelvic viscera during minimally invasive surgery. *Minimally Invasive Surgery* 2012; doi:10.1155/212/454120.
178. Wong W, Lee T, Lim C. Novel vaginal “paper roll” uterine morcellation technique for removal of large (>500g) uterus. *Jour Minimally Invasiv Gyn* 2010; 17:374-378.
179. Montella F, Riboni F, Cosma S, Dealberti D, Prigione S, Pisani C, Rovetta E. A safe method of vaginal longitudinal morcellation of bulk uterus with endometrial cancer in a bag at laparoscopy. *Surg Endosc* 2014; 28:1949-1953.
180. Ucella S, Cromi A, Seati M, Casarin J, Sturla D, Ghezzi F. Laparoscopic hysterectomy in case of uteri weighing ≥ 1 kilogram: a series of 71 cases and review of the literature. *Jour Minimally Invasiv Gyn* 2014; 21:460-465.
181. Bogani G, Ucella S, Cromi A, Serati M, Casarin J, Strula D, Ghezzi F. Electric motorized morcellator versus transvaginal extraction for myomas retrieval following laparoscopic myomectomy: a propensity matched analysis. *Jour of Minimally Invasiv Gyn* 2014; doi:10.1016/j.jmig.2014.04.012.
182. Cohen S, Greenberg J, Wang K, Srouji S, Gargiulo A, Pozner C, Hoover N, Einsarsson J. Risk of leakage and tissue dissemination with various contained tissue extraction techniques: an in vitro pilot study. *Jour Minimally Invasiv Gyn* 2014; doi:10.106/j.jmig.2014.06.004
183. Einarsson J, Cohen S, Fuchs N, Wang K. In bag morcellation. *Jour of Min Invasive Gyn* 2014; doi:10.106/j.jmig.2014.04.010.
184. David M, Adams L, Stupin J. Natural size development of myomata – ultrasound observational study of 55 premenopausal patients. *Geburtshilfe und Frauenheilkunde*, 2014; 74(1):75-80.

185. Parker W, Berek J, Fu Y. Uterine sarcoma in patients operated on for presumed leiomyomas and rapidly growing leiomyomas. *Obstet and Gyn* 1994; 83:414-418.
186. Murphy N, Wallace D. Gonadotropin releasing hormone agonist therapy for reduction of leiomyoma volume. *Gyn Onc* 1993; 49:266-267.
187. Kawamura N, Iwanaga N, Hada S, Maeda K, Sumi T, Ishiko O, Ogita S. Transient shrinkage of a uterine leiomyosarcoma treated with GnRH agonist for a presumed uterine leiomyoma: comparison of magnetic resonance imaging finding before and during GnRH agonist treatment. *Onc Reports*, 2001; 8:1255-1257.
188. Milman D, Zalel Y, Biran H, Open M, Caspi B, Hagay Z, Dgani R. Unsuspected uterine leiomyosarcoma discovered during treatment with a gonadotropin-releasing hormone analogue: a case report and literature review. *Eur J Obstet & Gyn* 1998; 76:237-240.
189. Condous G, Bignardi T, Alhamdan D, Van Calster B, Van Huffel S, Timmerman D, Lam A. What determines the need to morcellate the uterus during total laparoscopic hysterectomy? *Jour of Minimally Invasiv Gyn*, 2009; 15:52-55
190. Serur E, Lakhi N. Tips and tricks for successful manual morcellation: a response to “vaginal morcellation: a new strategy for large gynecological malignant tumor extraction.” *Gynecol Oncol*, 2013; 128(1):150. doi: 10.1016/j.ygyno.2012.09.007
191. Wan O, Cheung R, Chan S, Chung T. Risk of malignancy in women who underwent hysterectomy for uterine prolapse. *Austral and New Zealand Journ Obstet and Gyn* 2013; 53:190-196.
192. Frick A, Walters M, Larkin K, Barber M. Risk of unanticipated abnormal gynecologic pathology at the time of hysterectomy for uterovaginal prolapse. *Amer J Obstet & Gyn*, 2010; 202: 507.e1-4
193. Hill A, Carroll A, Matthews C. Unanticipated uterine pathologic finding after morcellation during robotic-assisted supracervical hysterectomy and cervicocolpopexy for uterine prolapse. *Female Pelvic Medicine and Reconstr Surgery*, 2014; 20(2):113-115.
194. Ouldamer L, Rossard L, Arbion F, Marret H, Body G. Risk of incidental finding of endometrial cancer at the time of hysterectomy for benign condition. *Jour of Minimally Invasiv Gyn*, 2014; 21:131-135.
195. Ramm O, Gleason J, Segal S, Antosh D, Kenton K. Utility of preoperative endometrial assessment in asymptomatic women undergoing hysterectomy for pelvic floor dysfunction. *Intl Urogyn Jour*, 2012; 23:913-917.
196. Hagemann I, Hagemann A, LiVolsi V, Montone K, Chu C. Risk of occult malignancy in morcellated hysterectomy: a case series. *Intl J Gyn Pathology*, 2011; 30:476-483.
197. Mahajan G, Kotru M, Batra M, Gupta A, Sharma S. Usefulness of histopathological examination in uterine prolapse specimens. *Austr and NZ Journal of Obstetrics and Gyn*, 2011; 51:403-405.
198. Saleh S, Fram K. Histopathology diagnosis in women who underwent a hysterectomy for benign condition. *Arch Gyn Obstet*, 2012; 285:1339-1343.
199. Yin H, Mittal K. Incidental findings in uterine prolapse specimen frequency and implications. *Intl Jour of Gyn Path*, 2004; 23:26-28.
200. Muezzinoglu B, Doger E, Yildiz D. The pathologic spectrum of prolapsus uteri: histopathologic evaluation of hysterectomy specimens. *Jour Gyn Surgery*, 2005; 21:133-135.

201. Theban J, Schellong A, Altgassen C, Kelling K, Schneider S, Grobs-Drieling D. Unexpected malignancies after laparoscopic-assisted supracervical hysterectomies (LASH): an analysis of 1,584 LASH cases. *Arch Gyn Obstet*, 2013; 287:455-462.
202. Nezhat C, Kho K. Iatrogenic myomas: New class of myomas? *Journ of Min Invasive Gyn* 2010; 17:544-550.
203. Leren V, Langebrekke A, Qvigstad E. Parasitic leiomyomas after laparoscopic surgery with morcellation. *Acta Obstet & Gyn Scand* 2012; 91:1233-1236.
204. Levy G, Hill M, Plowden T, Catherino W, Armstrong A. Biomarkers in uterine leiomyoma. *Fertility and Sterility* 2013; 99(4):1146-1152
205. Chen D, Liu J, Wu G, Ku C, Su H, Chen C. Serum vascular endothelial growth factor 165 levels and uterine fibroid volume. *Acta Obstet Gyn Scan* 2005; 84:317-321
206. Elsayes K, Pandya A, Platt J, Bude R. Technique and diagnostic utility of saline infusion Sonohysterography. *Intl J Gyn and Obstet* 2009; 105:5-9
207. Aviram R, Ochshorn Y, Markovitch O, Fishman A, Cohen I, Altaras M, Tepper R. Uterine sarcomas versus leiomyomas: Gray-scale and Doppler sonographic findings. *Journal of Clinical Ultrasound* 2005; 33(1):10-13
208. Lumsden M. Modern management of fibroids. *Ob, Gyn, and Reproductive Medicine* 2013; 23(3):65-70
209. Islam S, Protic O, Giannubilo R, Toti P, Tranquilli A, Petralgia F, Castellucci M, Ciarmela P. Uterine leiomyoma: Available medical treatments and new possible therapeutic options. *J Clin Endocrinol Metab* 2013; 98(3):921-934
210. Trumm C, Stahl R, Clevert D, Herzog P, Mindjuk I, Kornprobst S, Schwarz C, Hoffmann R, Reiser M, Matzko M. Magnetic resonance imaging-guided focused ultrasound treatment of symptomatic uterine fibroids. *Invest Radiol* 2013;48: 359-365
211. Desai S, Patil A, Nikam R, Desai A, Bachhav V. Magnetic resonance-guided focused ultrasound treatment for uterine fibroids: first study in Indian women. *J Clin Imaging Sci* 2012; 2:74-83
212. Zaher S, Gedroyc W, Lyons D, Regan L. A novel method to aid in the visualization and treatment of uterine fibroids with MRgFUS in patients with abdominal scars. *Euro J of Radiol* 2010; 76:269-273
213. Gorny K, Woodum D, Brown D, Henrichsen T, Weaver A, Amrami K, Hangiandreou N, Edmonson H, Bouwsma E, Stewart E, Gostout B, Ehman D, Hesley G. MRgFUS of uterine leiomyomas: review of a 12-month outcome of 130 clinical patients. *J Vasc Interv Radiol* 2011; 22:857-864.
214. Johnson L, Leong M, Miller M, Behera M. A prospective case-matched cohort analysis of MRgFUS versus UAE for treatment of symptomatic uterine fibroids. *Fertility and Sterility* 2009; 92:3 Suppl 1 (S127)
215. Taran F, Tempany C, Regan L, Inbar Y, Revel A, Stewart E. Magnetic resonance-guided focused ultrasound compared with abdominal hysterectomy for treatment of uterine leiomyomas. *Ultrasound Obstet Gynecol* 2009; 34: 572-578
216. Kohi M, Coakley F, Jacoby A, Rieke V, Westphalen A, Taylor A, Kolli K, Fidelman N, LaBerge J, Kerlan R, Jacoby V. A pilot randomized placebo-controlled trial of MR guided focused ultrasound

- for symptomatic uterine fibroids. *Journal of Vascular and Interventional Radiology* 2014 25:3 SUPPL. 1 (S68)
217. Bouwsma E, Hesley G, Woodrum D, Weaver A, Leppert P, Peterson L, Sterwart S. Comparing focused ultrasound and uterine artery embolization for uterine fibroids – rationale and design of the Fibroid Interventions: Reducing Symptoms Today and Tomorrow (FIRSTT) trial. *Fertility and Sterility* 2011; 96(3):704-710
 218. Rabinovici J, David M, Fukunishi H. Pregnancy outcome after MRgFUS for conservative treatment of uterine fibroids. *Fertil Steril* 2010; 93(1):199-209
 219. Hesley G, Gorny K, Woodrum D. MR-guided focused ultrasound for the treatment of uterine fibroids. *Cardiovasc Intervent Radiol* 2013; 36:5-13
 220. Clark M, Mumford S, Segars J. Reproductive impact of MRI-guided focused ultrasound surgery for fibroids: a systematic review of the evidence. *Fertility* 2014; 26(3):151-161
 221. Ciolina F, Boni F, Zaccagna F, Cavallo Marincola B, Noce V, Anzidei M, Napoli A, Catalano C. Retrospective analysis of elements that can predict short- and long-term outcome in patients with uterine leiomyomas treated with MRgFUS. *Cardiov and Interv Radiology* 2013; 36:Suppl 3 (S304)
 222. Ciolina F, Boni F, Zaccagna F, Cavallo Marincola B, Noce V, Anzidei M, Napoli A, Catalano C. Noninvasive treatment of symptomatic leiomyomas: initial experience using magnetic resonance-guided focused ultrasound technology. *Cardiov and Interv Radiology* 2013; 36:Suppl 3 (S304)
 223. Froeling V, Meckelburg K, Schreiter N, Scheurig-Muenkler C, Kamp J, Maurer M, Beck A, Hamm B, Kroencke T. Outcome of uterine artery embolization versus MR-guided high-intensity focused ultrasound treatment for uterine fibroids: long-term results. *Eur J of Rad* 2013; 82:2265-2269
 224. Mara M, Kubinova K, Maskova J, Horak P, Belsan T, Kuzel D. Uterine artery embolization versus laparoscopic uterine artery occlusion: the outcomes of a prospective, nonrandomized clinical trial. *Cardiov Intervent Radiol* 2012; 35:1041-1052
 225. Hald K, Noreng H, Istre O, Klew N. Uterine artery embolization versus laparoscopic occlusion of uterine arteries for leiomyomas: long-term results of a randomized controlled comparative trial. *JVIR* 2009; 20(10):1303-1310
 226. Ambat S, Mittal S, Srivastava D, Misra R, Dadhwal V, Ghosh B. Uterine artery embolization versus laparoscopic occlusion of uterine vessels for management of symptomatic uterine fibroids. *Int J Gyn and Obstet* 2009; 105:162-165
 227. Kuzel D, Mara M, Horak P, Kubinova K, Maskokva J, Dundr P, Cindr J. Comparative outcomes of hysteroscopic examinations performed after uterine artery embolization or laparoscopic uterine artery occlusion to treat leiomyomas. *Fertility and Sterility* 2011; 95(6):2143-2145.
 228. Helal A, Mashaly A, Amer T. Uterine artery occlusion for treatment of symptomatic uterine myomas. *JSLs* 2010; 4:386-390
 229. Goodwin S , Spies J, Worthington-Kirsch R, Peterson E, Pron G, Li S, Myers E; Fibroid Registry for Outcomes Data (FIBROID) Registry Steering Committee and Core Site Investigators. Uterine artery embolization for treatment of leiomyomata: long-term outcomes from the FIBROID Registry. *Obstet Gynecol.* 2008 Jan;111(1):22-33

230. Lohle P, Voogt M, De Vries J, Smeets A, Vervest H, Lampmann L, Boekkooi P. Long-term outcome of uterine artery embolization for symptomatic uterine leiomyomas. *J Vasc Interv Radiol* 2008; 19:319-326
231. Torre A, Paollissom B, Fain V, Labauge P, Pelage J, Fauconnier A. Uterine artery embolization for severe symptomatic fibroids: effects on fertility and symptoms. *Human Reproduction* 2014; 29(3):490-501
232. Bulman J, Ascher S, Spies J. Current concepts in uterine artery embolization. *RadioGraphics* 2012; 32:1735-1750
233. Pelage J, Guaou N, Jha R, Ascher S, Spies J. Uterine fibroid tumors: long-term MR imaging outcome after embolization. *Radiology* 2004; 230(3):803-809
234. Pron G, Bennett J, Common A, Wall J, Asch M, Sniderman K. The Ontario uterine fibroid embolization trial Part 2. Uterine fibroid reduction and symptom relief after uterine artery embolization for fibroids. *Fertility and Sterility* 2003; 79(1):120-127.
235. Katsumori T, Kasahara T, Kin Y, Nozaki T. Infarction of uterine fibroids after embolization: Relationship between postprocedural enhanced MRI findings and long-term clinical outcomes. *Cardiov Intervent Radiol* 2008; 31:66-72
236. Kroencke T, Scheurig C, Poellinger A, Gronewold M, Hamm B. Uterine artery embolization for leiomyomas: percentage of infarction predicts clinical outcome. *Radiology* 2010; 255(3): 834-841
237. Scheurig C, Gauruder-Burmester A, Kluner C, Kurzeja R, Lembcke A, Zimmermann E, Hamm B, Kroencke T. Uterine artery embolization for symptomatic fibroids: short-term versus mid-term changes in disease-specific symptoms, quality of life, and MRI results. *Human Reprod* 2006; 21(12):3270-3277
238. Shlansky-Goldberg R, Coryell L, Stavropoulos S, Trerotola S, Mondschein J et al. Outcomes following fibroid expulsion after UAE. *J Vasc Interv Radiol* 2011; 22:1586–1593
239. Al-Fozan H, Tulandi T. Factors affecting early surgical intervention after uterine artery embolization. *Obstet Gyn Surv* 2002; 57(12):810-815.
240. Hald K, Low N, Qvigstad E, Istre O. Laparoscopic occlusion compared with embolization of uterine vessels: a randomized controlled trial. *Obstet Gyn* 2007; 109:20-7
241. Robles R, Aquirre V, Arqueta A, Guerrero M. Laparoscopic radiofrequency volumetric thermal ablation of uterine myomas with 12 months of follow-up. *Int J Gyn Obstet* 2013; 120(1):65-69
242. Soysal M, Soysal S, Vicdan K. Thermal balloon ablation in myoma-induced menorrhagia under local anesthesia, *Gyn Obstet Invest* 2001; 51:128-133
243. Glasser M, Zimmerman J. The HydroThermAblator system for management of menorrhagia in women with submucous myomas: 12- to 20-month follow-up. *J Am Assoc Gynecol Laparosc.* 2003 Nov;10(4):521-7.
244. Perri T, Korach J, Sadetzki S, Oberman B, Firdman E, Ben-Baruch G. Uterine leiomyosarcoma: does the primary surgical procedure matter? *Int J Gynecol Cancer* 2009;19: 257-260.

245. Barri-soldevila P, Fargas F, Cusido M, Fabregas R. Negative impact of endoscopic approach on the prognosis of misdiagnosed uterine sarcomas. *Gyn Surg* 2013; 10 (Suppl 1): S1-151
246. Serrano C, Oduyebo T, Manola J, Feng Y, Muto M, George S. Impact of tumor morcellation on the natural history of uterine leiomyosarcoma. Abstract 011. CTOS Annual Meeting 2013
247. Rowland M, Lesnock J, Edwards R, Richard S, Zorn, Sukumvanich K, Krivak, T. Occult uterine cancer in patients undergoing laparoscopic hysterectomy with morcellation. *Gynecologic Oncology* 2012; 127: S1-S34
248. Guyon F, Stoecklel E, Grogan G, Kind M, Thomas L, Floquet A. Uterine morcellation of uterine sarcomas predicts a high risk of local recurrence. *EJSO* 2010; 795-932 Abstract 401
249. Hirst A , Dutton S, Wu O, Briggs A, Edwards C, Waldenmaier L, Maresh M, Nicholson A, McPherson K. A multi-centre retrospective cohort study comparing the efficacy, safety and cost-effectiveness of hysterectomy and uterine artery embolisation for the treatment of symptomatic uterine fibroids. The HOPEFUL study. *Health Technol Assess.* 2008 Mar;12(5)